

A Rare Case of *Salmonella enterica* serovar typhi Causing Extensive Abscesses Involving Multiple Sites and Meningeal Inflammation

Apurwa Bhojraj¹, Shashikala Shivaprakash², Mayur Patel³,
Himanshu Choudhury⁴

¹Department of Microbiology, ²Department of Microbiology, ³Department of Critical Care Medicine,

⁴Department of Radiology,

^{1,2,3,4} Sir HN Reliance Foundation Hospital, Mumbai, India

Corresponding Author: Shashikala Shivaprakash

DOI: <https://doi.org/10.52403/ijhsr.20250440>

ABSTRACT

Salmonella typhi a known cause of enteric fever, is endemic in Indian subcontinent and primarily cause bacteremia and gastrointestinal symptoms. The organism also has the potential to form extraintestinal abscesses in sites such as the liver, spleen, lymph nodes, bones, and joints, this report highlights an unusual manifestation of infection. Diabetes mellitus, haematological malignancies, HIV, immunocompromised states and other comorbidities may contribute to formation of abscess but the exact mechanism of pathogenesis remains unclear.

This case report describes a rare and noteworthy instance of *Salmonella Typhi* causing multiple abscesses in an immunocompetent patient who did not present with detectable bacteremia. Few reports have documented focal infections in spleen, liver, and brain. These abscesses, however, were found in patients with known *Salmonella Typhi* bacteremia.

The patient presented with insidious onset lower back pain, and radiological imaging revealed a localized abscess in the gluteal muscle, pelvic wall and presacral space, a site that is not commonly associated with this pathogen. Culture results of the aspirate confirmed the presence of *Salmonella Typhi*, and the organism was identified using VITEK MS (Mass Spectrometry) and confirmed by serotyping.

Prompt treatment, based on the antimicrobial susceptibility report, was initiated, demonstrating the importance of timely and accurate microbiological identification for proper management, even in the absence of typical bacteraemia symptoms.

Keywords: Enteric fever, Gluteal abscess, *Salmonella typhi*, VITEK MS

INTRODUCTION

Salmonella species are Gram-negative bacteria that encompass a wide range of serotypes, each capable of causing various human illnesses, from self-limited gastroenteritis to more severe systemic infections. While many cases present with

gastrointestinal symptoms, *Salmonella* can also lead to extraintestinal focal infections, including abscesses in organs such as the spleen, liver, and brain ^(1,2,3). These complications are often observed in patients, with, prior bacteremia due to *Salmonella* species.

The formation of abscesses without prior diagnosed *Salmonella* bacteremia is relatively uncommon. The pathogenesis of such abscess formation remains an area of active research. It is hypothesized that *Salmonella* may invade the bloodstream through the gastrointestinal tract, even in the absence of overt gastrointestinal symptoms, leading to systemic dissemination and subsequent abscess formation in distant organs.⁽⁴⁾ However, the exact mechanisms by which *Salmonella* causes these extraintestinal infections without prior bacteremia are not fully understood and warrant further investigation.

CASE REPORT

A 44-year-old male patient presented with insidious onset of lower back pain radiating to right thigh associated with tingling sensation, and difficulty in walking. Initial MRI findings suggested a lumbar disc bulge, for which symptomatic treatment, tapering steroids and rest was advised. However, the persistence and progression of

symptoms, including fever prompted further evaluation. Patient was admitted to a hospital for symptoms for which antibiotics were advised and a repeat MRI scan was suggestive of heterogeneously enhancing large lobulated mass in presacral region extending into right gluteal region encasing the sciatic nerve probably diagnosing as a Nerve sheath tumour.

The patient was admitted to our hospital for further management. Subsequent, a repeat MRI on admission was consistent with a localized loculated abscess in presacral region extending along the right greater sciatic foramen into the gluteal region encasing the sciatic nerve with mild perilesional edema. Cranially, it extended into the dorsolumbar spinal canal till D12 level with epidural abscess and thick leptomeningeal enhancement in lumbar region. A bilateral psoas abscess was also noted with marked inflammatory enhancement of psoas muscle.

The findings are depicted in Fig I.

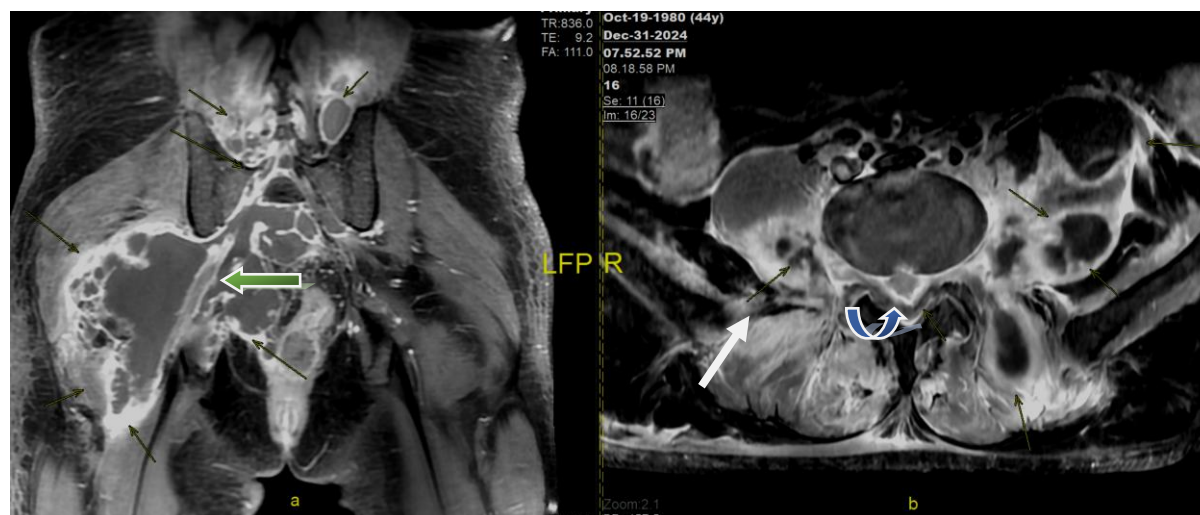


Figure I: Coronal post contrast MR image showing a large peripherally enhancing gluteal abscess extending to pelvic cavity along the Sacro-sciatic notch surrounding the sciatic nerve (thick green arrow). Image b axial post contrast MR image is showing epidural extension of the abscess with thick meningeitis (curved blue arrow), bilateral psoas and left paraspinal abscess [thin arrow].

Under CT scan guidance pigtail drainage catheter was inserted and procedure successfully aspirated approximately 200 cc of pus, which was sent for laboratory investigations. After the drainage, the patient showed some improvement in

mobility, but continued to experience intermittent episodes of fever.

The details of samples received in Microbiology laboratory are mentioned in Table 1.

Date of sample receipt	Type of Sample	Results
30/12/2024	Pus aspirate from right gluteal region for aerobic culture	<i>Salmonella typhi</i>
	Gene Xpert MTB RIF	MTB Not detected
	Blood culture set	No growth after 5 days of incubation.
1/1/2025	Pus aspirate from right gluteal region for aerobic culture	<i>Salmonella typhi</i>
	Pus aspirate from right gluteal region for anaerobic culture	<i>Salmonella typhi</i>
	Fungal culture of pus aspirate	No fungal elements seen
10/1/2025	Pus aspirate from right gluteal region for aerobic culture	<i>Salmonella typhi</i>

Table 1: Description of samples received.

Salmonella typhi was isolated repeatedly from pus with no isolation from blood.

Fluid cytological examination of aspirated pus was suggestive of neutrophils admixed with lymphocytes and macrophages over a background of eosinophilic necrotic debris. And negative for atypical or malignant cells. Other blood findings were s/o elevated CRP, altered SGOT and SGPT.

Microbiological findings included:

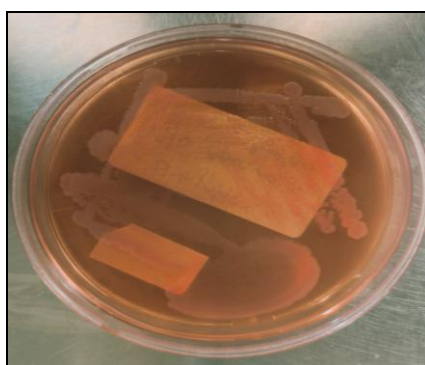
1. Gram stain: Fair number of pus cells and few Gram-negative bacilli were seen.

2. Ziehl-Neelsen (ZN) stain: No Acid-fast bacteria were seen.

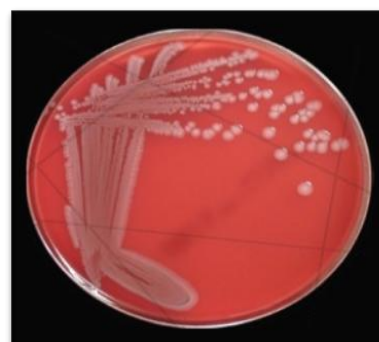3. After 24 hours of incubation, plates were examined for presence of growth.

- MacConkey agar: Approximately, 1-2 mm, non-lactose fermenting, translucent colonies were seen.

- Blood agar: Approximately 2-3 mm, grey, translucent, non-hemolytic colonies noted.



IIA. MacConkey agar



IIB. Blood agar

Figure II: MacConkey agar (IIA) and Blood agar (IIB) showing colony morphology after 24 hours of incubation.

The use of VITEK® MS (Mass Spectrometry) and VITEK® 2 Compact (Automated Antimicrobial Susceptibility Testing) along with serotyping has helped to

confirm the identification of the isolate as *Salmonella enterica* serovar Typhi.

The antimicrobial susceptibility was reported as per CLSI guidelines M100 ed 34 as explained in table 2.

Antibiotic	MIC value (Minimal inhibitory concentration)	Interpretation
Ceftriaxone	≤0.25	Susceptible
Ciprofloxacin	0.5	Intermediate

Levofloxacin	1	Intermediate
Ampicillin	Tested by disc diffusion method	Susceptible
Cotrimoxazole	≤0.20	Susceptible
Meropenem	≤0.25	Susceptible

Table 2: Antimicrobial susceptibility pattern.

Patient was started empirically on Piperacillin-tazobactam and vancomycin after sending cultures. On obtaining susceptibility report, antibiotic was tailored to meropenem and continued. On treatment, intensity of pain was reduced but still present and increase in mobility of affected leg was noted. Fever episodes were reduced but still present intermittently.

Subsequently, on continuation of treatment, the fever episodes were occasional, pain had reduced, vitals were stable and inflammatory markers showed a decreasing trend.

Given the absence of neurological involvement and the improvement with

antibiotic therapy, a multidisciplinary decision to manage the abscess conservatively (without surgical drainage) was taken.

Patient was discharged with meropenem, for a period of 1 month and follow up planned after 20 days with repeat MRI scan and liver function tests.

During the further course of treatment, due to deranged liver function tests, antibiotic was changed to ceftriaxone. Follow up MRI scan (Fig III) after a month of treatment and rehabilitation, was suggestive of near complete resolution of gluteal, psoas and epidural abscess with reduced leptomeningeal enhancement.

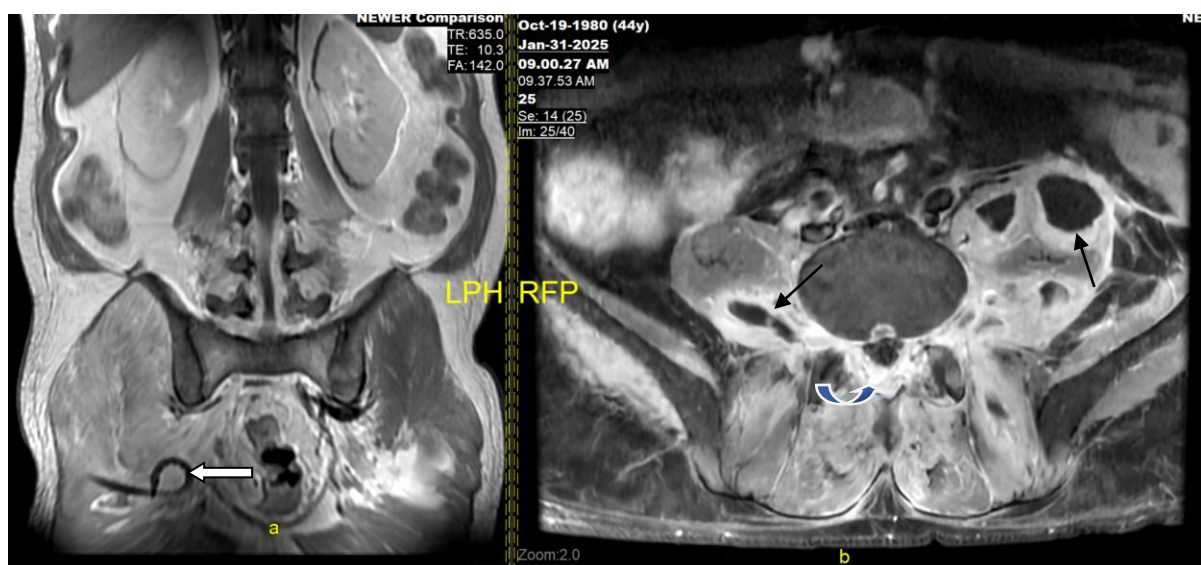


Figure III: Follow up MRI performed after 1 month of antimicrobial therapy, showing resolution of gluteal abscess with pigtail catheter in situ [thick long white arrow] in the coronal post contrast images (Fig IIIA). Axial post contrast image (Fig IIIB) also showing significant resolution of epidural abscess and thick meningitis [curved arrow], bilateral psoas and left paraspinal abscess [thin black arrow].

DISCUSSION

Enteric fever is caused by facultative intracellular organisms – *Salmonella Typhi* and *Salmonella Paratyphi* A and B. It usually presents as acute febrile illness with headache, diarrhoea, splenomegaly and leucopenia. Rarely, it causes extra-intestinal complications involving central nervous

system (3–35%), cardiovascular system (1–5%), pulmonary system (1–86%), bone and joints (≤1%), hepatobiliary system (1–26%), genitourinary system (<1%), and others⁽⁵⁾.

The development of an abscess caused by *Salmonella typhi* in our patient without a prior history of typhoid fever presents a diagnostic challenge. In such cases, it's

crucial to consider the possibility of a chronic carrier state, where the organism persists asymptomatically within the host, potentially leading to distant organ infections like abscesses.

The organism is known to reside within tissue macrophages in the liver and within the spleen and bone marrow. In fact, the organisms multiply within the reticuloendothelial system, and infected bile may lead to chronic carriage, thereby serving as a reservoir for future metastatic disease⁽⁶⁾.

Poorly controlled blood sugar levels are a significant risk factor for developing extraintestinal manifestations of *Salmonella* infections probably due to altered immune response and vascular complications hindering the delivery of immune cells to the site of infections⁽⁷⁾

Pastagia M, *et al.*, described a serovar typhi neck abscess as an opportunistic infection in

a++ patient with no prior history of typhoid fever⁽⁸⁾.

Further in this case, fluoroquinolones resistance was detected in subsequently cultured isolates. In 2017, World Health Organization (WHO) identified fluoroquinolone-resistant *Salmonella* species as priority pathogens, highlighting the urgent need for new antibiotics to combat these resistant strains.⁽⁹⁾

In the era of multidrug resistant salmonellosis, use of automated culture and antibiotic susceptibility methods are important for deciding the dose and duration of appropriate drug. Proper duration of therapy is essential for preventing relapses of the infection in future. There are no pre-established guidelines for the treatment of condition. However, few case reports in the literature have successfully treated the condition with various antibiotics as described in table 3.

Site of involvement	Isolate	Duration of treatment	References.
Psoas abscess	<i>Salmonella typhi</i>	Iv.cefotaxime * 5 weeks	Shakespeare WA. <i>et.al.</i> , (1)
Neck abscess	<i>Salmonella typhi</i>	Oral ciprofloxacin * 14 days	Pastagia M. <i>et al</i> ⁽⁸⁾ (2013)
Epidural abscess	<i>Salmonella enteritidis</i>	Oral ciprofloxacin * 3 months	Oki M. <i>et al</i> ⁽¹⁰⁾ (2016)
Thoracic spinal epidural abscess	<i>Salmonella typhi</i>	iv. ceftriaxone *6 weeks	Abdullah SH, <i>et al.</i> ⁽¹¹⁾ (2008)
Iliopsoas abscess	<i>Salmonella typhi</i>	iv ceftriaxone *6 weeks	Kumar B. <i>et al.</i> ⁽¹²⁾ (2024)

Table 3: Comparison of various case reports.

In any case, advancements in imaging techniques, automation in identification of microorganisms and antimicrobial susceptibility aids in starting prompt and appropriate treatment in order to combat resistance and mortality in patient.

This case highlights the importance of multidisciplinary collaboration, tailored antibiotic therapy, and careful monitoring in managing complicated infections like *Salmonella typhi* abscesses.

CONCLUSION

This case emphasizes several critical points in the diagnosis and management of infections, particularly in patients with

atypical presentation. It underscores the need for thorough clinical suspicion and advanced diagnostic techniques when managing abscesses, as uncommon pathogens such as *Salmonella* can sometimes present in unusual ways. It also emphasizes the significance of advanced diagnostic tools, such as VITEK MS, for the rapid and accurate identification of pathogens, which is essential in ensuring appropriate and targeted therapy. The emergence of fluoroquinolone-resistant *Salmonella typhi* highlights the critical need for vigilant antimicrobial stewardship, continuous surveillance, and the development of new therapeutic options to

effectively manage and control extraintestinal manifestations of the disease.

Declaration by Authors

Consent: Patient consent was obtained.

Acknowledgement: None

Source of Funding: None

Conflict of Interest: The authors declare no conflict of interest.

REFERENCES

1. Shakespeare WA, Davie D, Tonnerre C, Rubin MA, Strong M, Petti CA. Nalidixic Acid-Resistant *Salmonella enterica* Serotype Typhi Presenting as a Primary Psoas Abscess: Case Report and Review of the Literature. *J Clin Microbiol* 2005; 43:996-998. <https://doi.org/10.1128/jcm.43.2.996-998.2005>
2. Lambotte O, Debord T, Castagné C, Roué R. Unusual presentation of typhoid fever: cutaneous vasculitis, pancreatitis, and splenic abscess. *J Infect* 2001; 42:161-2. Doi: 10.1053/jinf.2000.0783.
3. Hanel RA, Araújo JC, Antoniuk A, da Silva Ditzel LF, Flenik Martins LT, Linhares MN. Multiple brain abscesses caused by *Salmonella typhi*: case report. *Surg Neurol* 2000; 53:86-90. doi: 10.1016/s0090-3019(99)00161-5.
4. Eng SK, Pusparajah P, Ab Mutalib N-S, Ser HL, Chan KG, & Lee LH. *Salmonella*: A review on pathogenesis, epidemiology and antibiotic resistance. *Frontiers in Life Science* 2015;8(3): 284–293. <https://doi.org/10.1080/21553769.2015.1051243>.
5. Huang DB, DuPont HL. Problem pathogens: extra-intestinal complications of *Salmonella enterica* serotype Typhi infection. *Lancet Infect Dis* 2005;5: 341-8. doi: 10.1016/S1473-3099(05)70138-9.
6. Parry, C. M., T. T. Hien, G. Dougan, N. J. White, and J. J. Farrar. Typhoid fever. *N Engl J Med* 2002;347: 1770-1782. <https://doi.org/10.1056/NEJMra020201>.
7. Telzak EE, Zweig Greenberg M S, Budnick L D, Singh T, Blum S. Diabetes Mellitus—A Newly Described Risk Factor for Infection from *Salmonella enteritidis*. *The Journal of Infectious Diseases* 1991;164: 538–541. <https://doi.org/10.1093/infdis/164.3.538>.
8. Pastagia M, Jenkins SG. *Salmonella* neck abscess as an opportunistic infection in diabetes mellitus. *Case Rep Infect Dis* 2013; 2013:708419. doi: 10.1155/2013/708419.
9. WHO priority pathogens list for R&D of new antibiotics/ WHO 2017.
10. Oki M, Ueda A, Tsuda A, Yanagi H, Ozawa H, Takagi A. *Salmonella Enterica* Serotype Enteritidis Vertebral Osteomyelitis and Epidural Abscess Complicated with Meningitis. *Tokai J Exp Clin Med* 2016;41: 169-71.
11. Abdullah SH, Ata OA, El-Adwan N. Thoracic spinal epidural abscess caused by *Salmonella typhi*. *Neurol Med Chir (Tokyo)* 2008;48: 140-2. doi:10.2176/nmc.48.140.
12. Kumar B, Agarwal D, Meena DS, Kumar D, Sureka B. Case Report: *Salmonella typhi* Iliopsoas Abscess with Concomitant Sacroiliitis in a Young Immunocompetent Male: A Rare Case. *Am J Trop Med Hyg* 2024;111: 297-299. doi:10.4269/ajtmh.24-0045.

How to cite this article: Apurwa Bhojraj, Shashikala Shivaprakash, Mayur Patel, Himanshu Choudhury. A rare case of *Salmonella enterica* serovar typhi causing extensive abscesses involving multiple sites and meningeal inflammation. *Int J Health Sci Res.* 2025; 15(4):279-284. DOI: <https://doi.org/10.52403/ijhsr.20250440>
