

An Individualised Homoeopathic Treatment of a Haemorrhagic Ovarian Cyst: A Case Report

Dr Rilang Iki Bamon¹, Dr Thounaojam Nanao², Dr Bakmenlin P Chyne³,
Dr Iarynkatin Keri⁴

¹Lecturer Practice of Medicine, ²Lecturer Obstetrics and Gynaecology, ³Assistant Professor,
Department of Organon of Medicine, NEIAH, Lecturer Materia Medica, NEIAH, Meghalaya, India.

Corresponding Author: Dr Rilang Iki Bamon

DOI: <https://doi.org/10.52403/ijhsr.20240846>

ABSTRACT

An ovarian cyst is a common gynecological problem during the childbearing age, these ovarian enlargements are functional in 70% of cases, neoplastic (mostly benign) in 20% of cases and ovarian endometriomas in 10% of cases. Malignant enlargement of ovaries can occur in any age group, however more often after the age of 50 years. Ovarian cyst can be divided into functional and pathological. A patient aged 28 years of age came with the complaints of irregularities of menses, and pelvic pain for 1 year and USG suggesting of hemorrhage ovarian cyst. CA 125 was under normal limit. Pulsatilla was given as an individualized drug of the patient after evaluating symptomology of the case and the potency used in this case was 200, repetition of potency was done according to the need of the case and follow up criteria. The treatment was done for 6 months, her symptomology was subsided and after treatment USG report also suggest of no presence of an ovarian cyst. The Modified Naranjo criteria were accessed to see the casual attribution to the prescribed medicine in the case. This evidence based case report can suggest the scope of homeopathic management in the treatment of Ovarian Cyst.

Keywords: Ovarian cyst, Homoeopathy, Individualised Homoeopathic medicine, Pulsatilla.

INTRODUCTION

An ovarian cyst is a common gynecological problem¹. Ovarian enlargement, cystic or solid may occur at any age. Functional and inflammatory enlargements of ovary develop almost exclusively during the childbearing years, they may be symptomatic or produce local discomfort, menstrual irregularities, infertility or in rare cases cause acute symptoms due to complications such as haemorrhage, rupture or torsion. During the childbearing age, these ovarian enlargements are functional in 70% of cases, neoplastic (mostly benign) in 20% of cases and due to ovarian

endometriomas in 10% of cases malignant enlargement of ovaries can occur in any age group, however more often after the age of 50 years^{1,2,3}.

Ovarian cysts can sometimes also be caused by an underlying condition, such as endometriosis. The vast majority of ovarian cysts are non-cancerous (benign), although a small number are cancerous (malignant). Cancerous cysts are more common if you have been through the menopause^{3,4}.

Ovarian cyst is divided into 2 main categories; physiological/ functional and pathological¹ Physiological/ functional cysts are follicular cysts and luteal cysts that

develop as part of the menstrual cycle and are usually harmless and short-lived usually regress spontaneously^{2,3}; these are the most common type, are more likely to rupture. Pain associated with the rupture of ovarian follicle at the time of ovulation is called mittelschmerz.⁵ Pathological cysts are cysts that form as a result of abnormal cell growth; these are much less common and considered as ovarian tumors, which might be benign, malignant, and borderline. Benign tumors are more common in young females, but malignant are more frequent in elderly females. Most ovarian cysts are asymptomatic and disappear spontaneously^{2,3,6}. An ovarian cyst usually only causes symptoms if it splits (ruptures), is very large or twists and then blocks the blood supply to the ovaries^{3,5}. When ovarian cysts are large, they may cause abdominal discomfort. If pressing on the bladder it may also cause frequency of urination. The signs and symptoms of ovarian cysts may include; pelvic pain, dysmenorrhea, and dyspareunia. Other symptoms are nausea, vomiting, or breast tenderness, fullness and heaviness in the abdomen and frequency and difficulty emptying of the bladder^{3,4,5}.

CASE REPORT

Patient information: A lady aged 29 years, unmarried visited the Homoeopathy outpatient department of North East Institute of Ayurveda and Homoeopathy, Meghalaya on 13/11/ 2023 with the complaints of pain over the left iliac region, irregularities of menses, heavy menses since 1 year.

Presenting complaint:

LOCATION: Patient presented with pain in left side of lower abdomen since one year which extend till the left hip and upper part of thigh and also to lower part of back thigh with irregular menses.

Sensation: Pain is dull in nature.

Modalities: Pain is aggravated before and after menstruation, and was relieved by massage and stretching.

History of present complaint: 1st

complaint: -menstrual history

- menses was irregular (28+10 days) .
- duration is 3-4 days,
- There was heaviness flow for 2 day and no pain during menses
- Menses is watery with clots on 3rd day.
- 2nd complaint: -Leucorrhoea since 1 year
- Whitish, offensive+++
- Itching+++ aggravates before menses, relieved by washing with hot water

Past history: nothing specific

Family history: Mother died of hyperthyroidism two years ago.

Personal history- Patient is working in an agency

Physical generals

Appetite: good

Thirst: thirsty, luke warm water

Desire: for fruits, sweet

Sleep: disturbed by slightest noise

Aversion: N/P

Sweat: only on exertion, while awake scanty

Stool: regular, satisfactory

Urine: clear

Thermal reaction: chilly patient

Dreams- animal

Menstrual history

Menarche: At the age of 13 years.

LMP: 28/09/2023

Cycle: Irregular Duration :3-4 Days. Menses used to last for 3-4 days, clotted, irregular. Colour and consistency- thick red clots before menses end.

Mental symptoms: Patient was cooperative, introverted, mild and emotionally sensitive. she has a weeping tendency and fond of children, likes to help others, likes to share her problems and feel better after sharing her problems, anger does not last long, likes to be alone, always hurry in doing anything.

General survey: The patient was apparently healthy, with no features of anaemia, cyanosis, jaundice or clubbing. Blood Pressure:120/80 mm of Hg, right hand, sitting position, pulse: 72/min, regular rhythm, vessel wall not palpable, oxygen saturation-98 %

Respiratory rate: 20 breath/ min.

Temperature: A febrile at time of examination.

Physical examination of abdomen: On inspection:-no swelling, no redness, or mass seen

On palpation:- Tenderness in left iliac fossa on superficial palpation.

On deep palpation around lump can be felt in the left iliac fossa.

Rovsing sign - negative.

Laboratory investigation:

Ultrasonography (USG) of lower abdomen done on 16/11/23, impression:

Left haemorrhagic ovarian cyst measuring about 4.23cmx3.48cms in left ovary

Diagnosis: Haemorrhagic left ovarian cyst

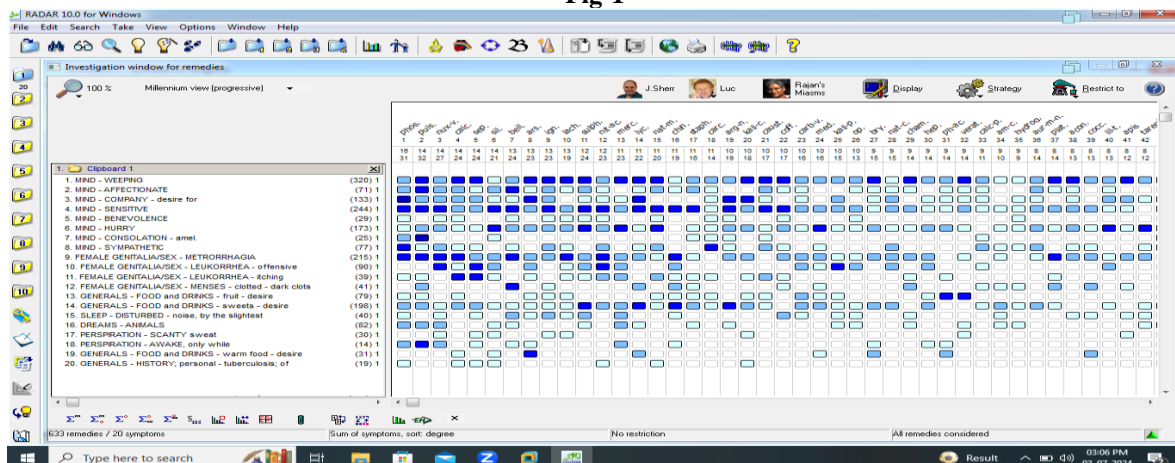
Analysis and evaluation

- Cooperate and weeping disposition
- likes to be alone
- Fond of children
- Benevolence
- Sensitive
- hurry in doing things
- Consolation ameliorates
- Sympathetic
- Dreams of animals
- chilly patient
- Desire for sweets and warm food, fruits
- Pain in left side of lower abdomen before and during menses.

Repertorization.

- Repertorization was done by using RADAR 10 Software for windows; Schroyens F; Synthesis, shown in figure 1
 - Rubric taking for reportarisation
 - Mind -weeping
 - Mind-affectionate
 - Mind- company-desire for
 - Mind- sensitive
 - Mind- benovalence
 - Mind - hurry
 - Mind- consolation- ameliorate
 - Mind- sympathetic
 - Female genitalia/sex- METRORRHAGIA
 - Female genitalia/sex- LEUKORRHEA-offensive
 - Female genitalia/sex- LEUKORRHEA-itching
 - Female genitalia/sex- MENSES-clotted-dark clot
 - Generals-food and drinks- fruits- desire
 - Generals-food and drinks- sweet- desire
 - Generals-food and drinks- warm food-desire
 - Generals- history,personal-tuberculosis of
 - Sleep - disturbed - noise- by slightest
 - Dreams- Animals
 - Perspiration- scanty-sweat
 - Perspiration-Awake- only while
- 1ST PRESCRIPTION: PULSATILLA 200 3 DOSE ODx3days.

Fig-1



Followed up sheet: FOLLOW UP IS DONE IN EVERY 1 month as she is from far place.

Table-1

Date	Symptom of patient	Prescription and remarks
11/12/23	Patient not feeling any changes, pain in the left side abdomen same, menses is irregular LMP-09/11/23 and complaint of leucorrhoea is decreased and itching ++ and all the generalities are good. Sense of well being was present.	RX. 1. Rubrum 200 5-05- for 1month, (no repetaion and change in potency as she was feeling better. Wait and watch)
22/01/24	Patient felt little improvement in terms of her pain in left side of abdome, menses- irregular, LMP-30/12/23, leucorrhoea and pruritus vagina – decreased. All generalities are good.	RX. 1. Pulsatilla 200 2 dose weekly- for 2 weeks, Rubrum for 1 month. (dose was repeated as choice of drug and potency was acting well and to further complete the process of action of cure)
22/02/24,	Patient feeling much better after taking medicine, pain in iliac region reduced, leucorrhoea and pruritus vagina was absent, LMP-3/2/24 duration, menstrual cycle-32 days, all generalities are good. No new compalits	RX 1. Rubrum 200 5-05- for 1 month, (rubrum was given not to distrub the action of puls 200)
05/04/24	Patient feeling much better, no pain in iliac region Lmp-5/3/24 cycle-32 days, all generalities is good. No new complaints.	RX 1. Rubrum 200 5-05- for 1 month, 2.kaliphos 6x 2-0-2 for 2 week.
23 /5/24	No pain in iliac region, LMP :6/4/24 cycle 32 days. No new complaints.	1. Rubrum 200 5-05- for 1 month, Advice for USG (whole abdomen) Review with the report. Report of USG on 25/5/24-suggesting of no abnormality and ovarian cyst seen.

Table-2 Modified Naranjo Criteria

Domains	Yes	No	Not sureor N/A
1. Was there an improvement in the main symptom or condition for which the homeopathic medicine was prescribed?	+2		
2. Did the clinical improvement occur within a plausible timeframe relative to the drug intake?	+2		
3. Was there an initial aggravation of symptoms?			0
4. Did the effect encompass more than the main symptom or condition (i.e., were other symptoms ultimately improved or changed)?	+1		
5. Did overall wellbeing improved?	+1		
6A Direction of cure: did some symptoms improve in the opposite order of the development of symptoms of the disease?			0
6B Direction of cure: did at least two of the following aspects apply to the order of improvement of symptoms: –from organs of more importance to those of less importance? –from deeper to more superficial aspects of the individual? –from the top downwards?			0
7. Did “old symptoms” (defined as non-seasonal and non-cyclical symptoms that were previously thought to have resolved) reappear temporarily during the course of improvement?			0
8. Are there alternate causes (other than the medicine) that—with a high probability—could have caused the improvement? (Consider known course of disease, other forms of treatment, and other clinically relevant interventions)			0
9. Was the health improvement confirmed by any objective evidence? (e.g., laboratory test, clinical observation, etc.)	+2		
10. Did repeat dosing, if conducted, create similar clinical improvement?	+1		
Total	9		

DISCUSSION

There are instances of case reports and case series reports which has shown Homoeopathic Individualised treatment is effective in the treatment of ovarian cyst. One case report suggested Lycopodium as an constitutional or individualised drug and shown effective in the treatment of an ovarian cyst¹¹. There is also a case series reported for the Non-invasive Resolution of Pathological Ovarian Masses with Homeopathic Treatment¹². Individualised homoeopathy treatment shows favourable results in the treatment of ovarian cyst in both functional and pathological type of ovarian cyst but no randomised clinical trial on ovarian cyst by homoeopathic treatment was found during the review search, therefore randomised clinical trial with adequate sample size need to be advocated for further claim on the effectiveness of homoeopathy in the treatment of ovarian cyst. This case report is presented with an aim to add additionally value in individualised homoeopathy management in the treatment of ovarian cyst on the existing claim where a case with Haemorrhagic left ovarian cyst in which patient presenting with irregular menses and abdominal pain was treated with

individualised homoeopathy; Pulsatilla 200. After reportorisation, Phosphorus was the medicine that came first but based on the Individualised clinical picture, mental symptoms and totality of symptoms, Pulsatilla 200 was chosen as a choice of remedy and potency. Evaluation and analysis of symptoms were done according to Kent's Philosophy, Philosophy of Posology, various Materia medica and Repertory were exceeded for better evaluation of the case. Thus, Pulsatilla which was prescribed has brought absolute improvement to the patient symptomatology within 6 months of follow up. Pre and post ultrasonic reports were compared for the significance of the results. And also by using Modified Naranjo criteria, score of +10 indicated the causal role of medicine i.e Pulsatilla200 in action of recovery.

CONCLUSION

This case report will serve an additional evidence based report to the existing case series for the effectiveness of homoeopathy in the management of ovarian cyst particularly to an symptomatic functional cyst by individualized drug Pulsatilla 200. Ultrasonography report before treatment and after treatment,

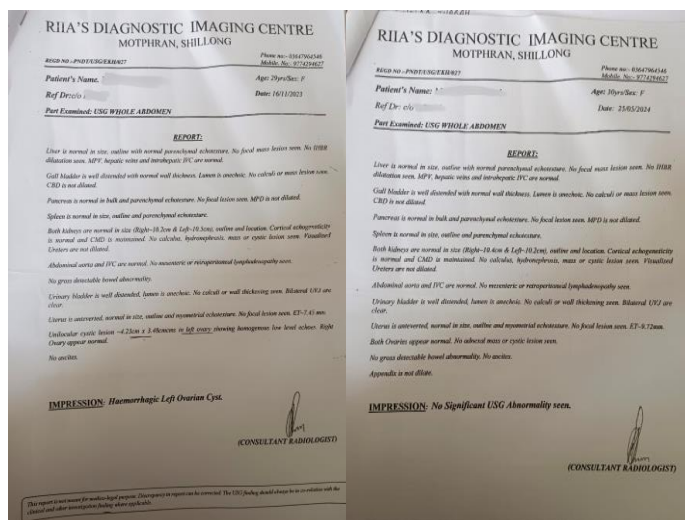


Fig-2

Declaration by Authors

Informed consent: The patient consent was obtained prior to case taking for confidentiality of her identity. The patient has agreed that her report and other clinical information is to be reported in the journal.

Acknowledgement: The authors deeply acknowledge the patient for allowing us to collect the data.

Conflict of interest: None

Financial support: Not available

REFERENCE

1. Abduljabbar HS, Bukhari YA, Al Hachim EG, Alshour GS, Amer AA, Shaikhoon MM, Khojah MI. Review of 244 cases of ovarian cysts. Saudi Med J. 2015 Jul;36(7):834-8. doi: 10.15537/smj.2015.7.11690. PMID: 26108588; PMCID: PMC4503903.
2. Konnar H; D C Dutta's Textbook of Gynecology 8th edition;2020.
3. <https://www.nhs.uk/conditions/ovarian>
4. Padubidri VG. Daftary Shirish N. Shaws Textbook of Gynaecology 18th edition;Elsevier
5. https://www.researchgate.net/publication/362790394_CASE_STUDY_Individualised_homoeopathic_treatment_of_ovarian_cyst
6. Berek Jonathan S. Berek & Novak's Gynaecology 16th edition: wolters kluwer
7. Boericke W, Boericke's New Manual of Homoeopathic Materia Medica with Repertory – Third Revised & Augmented Edition Based on Ninth Edition, New Delhi B.Jain Publishers;2014.
8. Sarkar BK, Organon of medicine. Delhi: Birla publications Pvt.Ltd;2005-2006
9. Kent JT, Lectures on Homoeopathic Philosophy, Low price edition, New Delhi; B.Jain publishers,2014
10. RADAR 10 Software for windows; Schroyens F; Synthesis
11. Nath, Arunava & Palit, Deb & Kundu, Nivedita. (2020). Homoeopathic Management Of Ovarian Cyst – A Case Report. AYUSHDHARA. 2393-2399. 10.47070/ayushdhara.v6i5.491.
12. A Case Series. Homeopathy. 2022 Aug;111(3):194-201. doi: 10.1055/s-0041-1735849. Epub 2021 Dec 27. PMID: 34959245

How to cite this article: Rilang Iki Bamon, Thounaojam Nanao, Bakmenlin P Chyne, Iarynkatin Keri. An individualised homoeopathic treatment of a haemorrhagic ovarian cyst: a case report. *Int J Health Sci Res.* 2024; 14(8):409-414. DOI: <https://doi.org/10.52403/ijhsr.20240846>
