

# Comprehensive Physiotherapy Management of Giant Cell Tumour - A Case Report

Avantika Arora<sup>1</sup>, Monika Virk<sup>2</sup>, Sunidhi Rana<sup>3</sup>, Gaytri Kankerwal<sup>4</sup>

<sup>1,3,4</sup>Assistant Professor, Prem Physiotherapy and Rehabilitation College, Panipat, Haryana, India

<sup>2</sup> BPT Student, Prem Physiotherapy and Rehabilitation College, Panipat, Haryana, India

Corresponding Author: Avantika Arora

DOI: <https://doi.org/10.52403/ijhsr.20240833>

## ABSTRACT

**Background:** A 21-year-old female student from Patiala, Punjab currently residing in Canada and working at Tim Hortons, presented with a two-month history of persistent, sharp pain in her left knee, making it difficult to bend.

**Case Presentation:** The patient is 154 cm tall, weighing 58 kg and with a BMI of 24.4 kg/m<sup>2</sup>, had a fall in August eight months prior to presentation. Initial consultation with an orthopedician a week post-fall led to analgesics and an X-ray recommendation. An X-ray on October 15th in Canada revealed a concerning ill-defined lytic lesion within the distal femoral metaphysis, suggestive of a neoplastic or malignant process. Returning to India for further treatment, a CT scan at the AIIMS confirmed a grade 3 giant cell tumour diagnosis. On November 25th, a plaster cast was applied and a biopsy on December 2nd confirmed the diagnosis, leading to a surgical recommendation.

**Treatment and Outcome:** Chemotherapy infusion commenced on January 13th and continued until March. Surgery involving curettage and Titanium plating was performed on April 4th, with the limb placed in a plaster cast removed on April 24th. Post-surgery, an above-knee brace was provided and physiotherapy management was advised. On May 6th, visited Dr. Prem Cancer Hospital, Physiotherapy OPD for ongoing physiotherapy management.

**Conclusion:** The patient journey from initial injury through diagnosis, treatment and post-surgical rehabilitation highlights the complexity of managing giant cell tumours and the importance of a multidisciplinary approach including orthopaedic, oncological and physiotherapeutic care.

**Keywords:** Female, Young Adult, Titanium, Casts

## INTRODUCTION

A type of primary benign bone tumour that is relatively rare, giant cell tumour (GCTs) are characterized by multinucleated large cells that have similarities to osteoclast.<sup>1</sup> Giant cell tumours are mostly found in the epiphysis of long bones.<sup>2</sup> Lung metastases occur in about 1%–9% of GCTB patients, and 2-4% of individuals develop after malignant GCT. Most often, GCTBs are

seen in the distal femur (30%), proximal tibia (28%) and distal radius (9%), and distal tibia (6%) Pelvic (2%), sacral (2%) and spinal (3%).<sup>2</sup>

Females are affected more often than males.<sup>3</sup> The prevalence of GCT is recorded at 3%-8% in western countries and 20% in Asia of the total primary bone tumours, where 80% of cases are in the age range of 20-50 years, with a peak incidence of

patients in the third decade of life. GCT also has a high risk of recurrence at 10%-65%, even though studies have been conducted to treat tumours. There is a risk that 10% of GCTs can develop into malignant tumours.<sup>1</sup> GCT patients typically feel pain as a result of the tumour deterioration of their bones. Tumours that appear close to joints had reduced range of motion (ROM), joint effusion, synovitis and a soft tissue mass or bump as it spreads beyond the bone. Approximately 11% and 37% of GCTs cause pathological fractures.<sup>1</sup>

GCT was divided into three phases by Enneking and Cam Panacci based on radiological appearance. Latent in Stage I, active in Stage II, and aggressive in Stage III. Grades I, II, and III; grade II with fracture. A thin ring of mature bone forms a well-marginated border around a grade I tumour, and the cortex is either whole or slightly thinned but not distorted.<sup>2,4</sup>

The borders of a grade II tumour are often clearly defined, but there is no radiopaque rim, and the reactive bone rim is only slightly to moderately enlarged. Fractures in grade-II lesions are rated differently. A tumour classified as Grade III has fuzzy edges, indicating that it is growing quickly and may be permeating the surrounding soft tissues.<sup>2,4</sup>

Grade – II tumour has relatively well-defined margins but no radiopaque rim and rim of reactive bone is rather thin and moderately expanded. Grade-II lesions with a fracture are graded separately. Grade – III designates a tumour with fuzzy borders, suggesting a rapid and possibly permeative growth and the tumour bulges into the soft tissues.<sup>2,4</sup>

**Surgical Options** include Curettage, in which the tumour is removed by scraping, and the space is then filled with bone cement or graft. To lower recurrence, this is frequently used in conjunction with adjuvant therapies such polymethylmethacrylate (PMMA), liquid nitrogen, or phenol. Another surgical option includes En bloc excision in which a full excision of the tumour with a margin of

healthy tissue may be required in situations of large or recurring tumors.<sup>5</sup>

**Non-surgical Interventions** include Radiation therapy that is a medical intervention that targets cancer cells with high-energy beams like protons or X-rays. It is frequently used to shrink tumours before surgery or to eliminate cancers that cannot be surgically removed. Another non-surgical intervention used is Denosumab which is a monoclonal antibody that inhibits osteoclast activity by targeting RANKL (Receptor Activator of Nuclear Factor Kappa-B Ligand) thus reducing the size of the tumour and pain.<sup>6</sup>

### CASE DESCRIPTION

A 21-year-old female student from Patiala, Punjab, currently residing in Canada and working at Tim Hortons presented with persistent, sharp pain in her left knee, making it difficult to bend. This pain had been ongoing for the past two months. She is 154 cm tall, weighs 58 kg and has a body mass index of 24.4 kg/m<sup>2</sup>. Her medical history reveals that she experienced a fall in August eight months ago. A week after the fall, she consulted an orthopedician who prescribed analgesics and recommended an X-ray. She scheduled an appointment in Canada for October 5th, and the X-ray on October 15th revealed ill-defined lytic lesion within the distal femoral metaphysis concerning for a neoplastic/malignant process of the distal femoral metaphysis. For further treatment, she returned to India and consulted a doctor at the All-India Institute of Medical Sciences. A subsequent CT scan confirmed the diagnosis, revealing it to be a grade 3 giant cell tumour. On 25th November, Plaster cast is applied. The doctor advised a biopsy and a report for biopsy revealed on 2nd December and subsequently recommended surgery. From 13th January onwards Chemotherapy infusion was started till March. The surgery was performed on April 4th with a curettage and Titanium plating and her limb was placed in a plaster cast, which was removed on April 24th. After which above knee brace

was provided and doctor advised her for physiotherapy management and first, she went to Artios Hospital – Super Speciality Hospital and later on May 6th, she visited

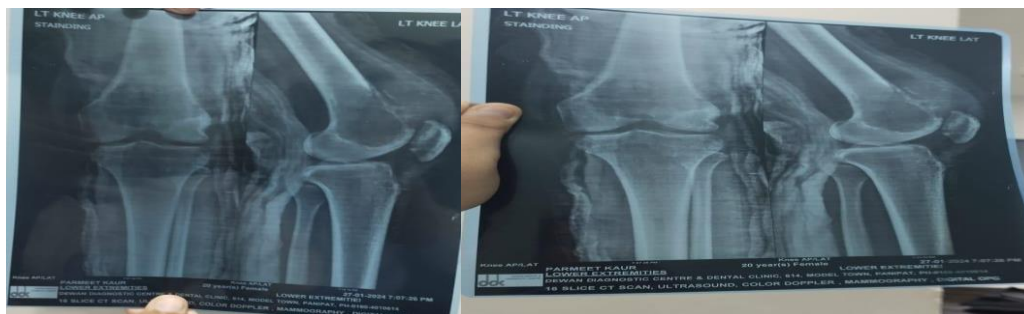the Dr. Prem Cancer Hospital, Physiotherapy OPD for physiotherapy management. Write here procedure/technique of your research study.

**ASSESSMENT**

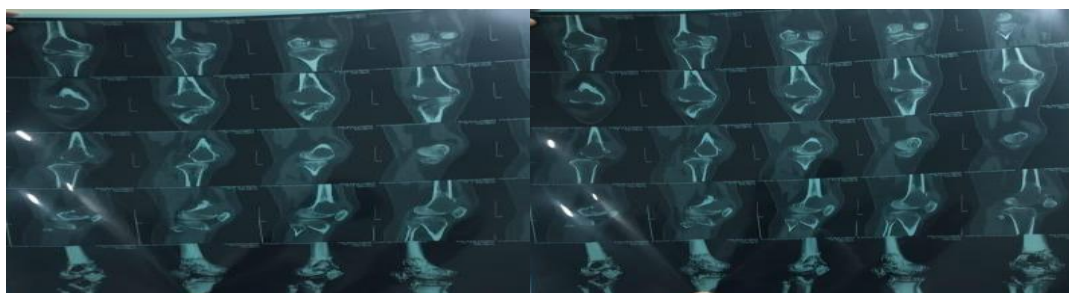
OUTCOME	BASELINE	POST-INTERVENTION
<b>Visual Analogue Scale (VAS)</b>	7.8/10	4/10
<b>Range of Motion (Left)</b>		
<b>Hip</b>		
Flexion	0-30 °	0-40°
Extension	0-27 °	0-20°
Abduction	0-60 °	0-60°
Adduction	0-60 °	0-60°
<b>Knee</b>		
Flexion	0-55°	0-62°
Extension	0-10 °	0-15°
<b>Ankle</b>		
Dorsiflexion	0-35°	0-35°
Plantarflexion	0-45°	0-50°
Eversion	0-25°	0-30°
Inversion	0-15°	0-20°
<b>KOOS</b>	58%	74%

<b>Muscle Girth</b>	<b>Affected Side (Left side)</b> 5cm above patella- 19 inch 10 cm above patella- 22.5 inch 15 cm above patella- 22 inch	<b>Unaffected Side (Right side)</b> 5cm above patella- 18.5 inch 10 cm above patella- 21.5inch 15 cm above patella- 24 inch
<b>Limb Length Discrepancy</b>	<b>Left Side</b> True Limb Length - 32.2 inch Apparent Limb Length- 34.5 inch	<b>Right Side</b> True Limb Length - 32.2 inch Apparent Limb Length- 35 inch

**INVESTIGATIONS**



**X-RAY**

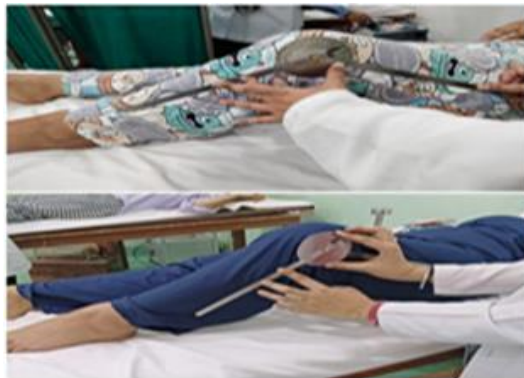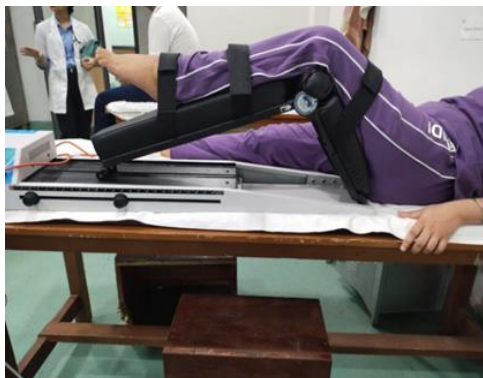


**MRI**

## PHYSIOTHERAPY MANAGEMENT

### REHABILITATION PROTOCOL

<b>DAY 1</b>	<ul style="list-style-type: none"> <li>• CPM -10 minutes at 6 degrees</li> <li>• Circulatory drills (Ankle) in a supine</li> <li>• Heel slides (10 reps*2 sets) {B/L}</li> <li>• Abduction movement hip (10 reps*2sets)</li> <li>• Straight leg raise in supine lying (10 reps*5 sec hold*1 set) {B/L}</li> <li>• Patella Maitland mobilization Grade 1</li> <li>• Popliteus Release</li> <li>• Quadriceps isometric exercise in supine (10 reps*10 sec hold*1 set). {B/L}</li> <li>• Calf Stretching (3 reps*30 sec hold) {B/L}</li> </ul>
<b>DAY 2</b>	<p>Continue same treatment</p> <p>CPM -10 minutes at 8 degrees</p> <p>Tibiofemoral (anterior glide) Maitland Mobilization Grade 1</p> <p>SLR in all 3 planes Supine lying 10 reps*10 sec hold*1set</p> <p style="padding-left: 40px;">Side lying</p> <p style="padding-left: 40px;">Prone lying</p>
<b>DAY 3</b>	<p>Continue same treatment</p> <p>CPM – 10 min at 9 degrees</p> <p>Hamstring curls (10 reps*2 sets) {B/L}</p> <p>Quadriceps isometric exercise in sitting (10 reps*10 sec hold*1 set). {B/L}</p>
<b>DAY 4</b>	<p>Continue same treatment</p> <p>Wall slides (10 reps*2 sets) {B/L}</p> <p>Joint Compression</p> <p>Tibiofemoral (anterior glide) Maitland Mobilization Grade 2</p> <p>Sit to Stand (20 reps*5 sec rest*2 sets)</p>
<b>DAY 5</b>	<p>Continue same treatment</p> <p>CPM-10 minutes at 13 degrees</p> <p>Wall Squats at 30-degree hold (7 reps*1 set)</p> <p>Standing up and off heels (10 reps*2 sets)</p>
<b>DAY 6</b>	<p>Continue same treatment</p> <p>CPM – 10 minutes at 16 degrees</p> <p>Tibiofemoral (anterior glide) Maitland Mobilization Grade 3</p> <p>Stepping up and down the step box forward and sideward.</p>
<b>DAY 7</b>	<p>Continue same treatment</p> <p>CPM – 10 minutes at 20 degrees</p> <p>Tibiofemoral (anterior glide) Maitland Mobilization Grade 3</p> <p>Mini squat with assistant aid</p> <p>Toe gait Walking. <sup>7,8</sup></p>







## DISCUSSION

In current cases, physical therapy emphasizing manual therapy and therapeutic exercise has shown significant results in patients with GCT. The intervention aims to reduce pain, increase range of motion (ROM), decrease spasticity, improve flexibility, and promote functional independence. Patients with GCT often experience challenges such as inability to walk, anticipated pain, and dysfunction.

GCT is a complex tumour necessitating a multidisciplinary approach involving orthopaedic surgeons, radiologists and oncologists to ensure optimal management. Ongoing research is focused on enhancing treatments, understanding the molecular basis of the disease and identifying predictive markers for recurrence and metastasis.

The primary treatment for GCT is surgical tumour removal, aiming for complete excision while preserving healthy bone and joint function. In cases where surgery alone is not feasible or to reduce recurrence risk, adjuvant therapies like chemotherapy and post-operative physical therapy are employed. Post-operative stiffness can be effectively managed with specific exercises and modalities.

## CONCLUSION

The study presented a case of Giant Cell Tumour (GCT) managed using physical therapy, specifically focusing on manual therapy and therapeutic exercise. These interventions were found to achieve

significant results in treating patients with the GCT tumour.

### *Declaration by Authors*

**Ethical Approval:** Not Needed

**Acknowledgement:** None

**Source of Funding:** None

**Conflict of Interest:** The authors declare no conflict of interest.

## REFERENCES

1. Ihsan M, Yanti N Physical Therapy Interventions for Post-Operative a Giant Femoral Tumour: A Case Report, *Kinesiology and Physiotherapy Comprehensive*.2022. 1(1):1-6.
2. Tsukamoto S, Mavrogenis AF, Kido A, Errani C. Current Concepts in the Treatment of Giant Cell Tumours of Bone. *Cancers (Basel)*. 2021. 21;13(15):3647.
3. Deventer N, Budny T, Gosheger G, Rachbauer A, Puetzler J, Theil JC, Kovtun D, de Vaal M, Deventer N. Giant cell tumour of bone: A single center study of 115 cases. *J Bone Oncol*. 2022 .17; 33:100417.
4. Sobti A, Agrawal P, Agarwala S, Agarwal M. Giant Cell Tumor of Bone - An Overview. *Arch Bone Jt Surg*. 2016;4(1):2-9.
5. Wang Y, Tian Q, Wu C, Li H, Li J, Feng Y. Management of the Cavity After Removal of Giant Cell Tumor of the Bone. *Front Surg*. 2021. 29; 8:626272.
6. Baskar R, Lee KA, Yeo R, Yeoh KW. Cancer and radiation therapy: current advances and future directions. *Int J Med Sci*. 2012;9(3):193-9.
7. An J, Son YW, Lee BH. Effect of Combined Kinematic Chain Exercise on

Physical Function, Balance Ability, and Gait in Patients with Total Knee Arthroplasty: A Single-Blind Randomized Controlled Trial *J Environ Res Public Health*. 2023 16;20(4):3524.

8. Xu J, Zhang J, Wang XQ, Wang XL, Wu Y, Chen CC, Zhang HY, Zhang ZW, Fan KY, Zhu Q, Deng ZW. Effect of joint mobilization techniques for primary total knee arthroplasty: Study protocol for a

randomized controlled trial. *Medicine (Baltimore)*. 2017;96(49):e8827.

How to cite this article: Avantika Arora, Monika Virk, Sunidhi Rana, Gaytri Kankerwal. Comprehensive physiotherapy management of giant cell tumour - a case report. *Int J Health Sci Res*. 2024; 14(8):296-301.  
DOI: <https://doi.org/10.52403/ijhsr.20240833>

\*\*\*\*\*