

Lung Carcinoid Tumour: A Rare Case Report

Dr Veena Gupta¹, Dr Shivani Bhargava², Dr Vibhuti Jain³, Dr Sunita Singh⁴,
Dr Meenu Gill⁵, Dr Promil Jain⁶

¹Professor, Department of Pathology, Pt. B.D Sharma Post Graduate Institute of Medical Sciences, Rohtak, Haryana, India.

²Junior Resident, Department of Pathology, Pt. B.D Sharma Post Graduate Institute of Medical Sciences, Rohtak, Haryana, India.

³Senior Resident, Department of Pathology, Pt. B.D Sharma Post Graduate Institute of Medical Sciences, Rohtak, Haryana, India.

⁴Senior Professor and Head, Department of Pathology, Pt. B.D Sharma Post Graduate Institute of Medical Sciences, Rohtak, Haryana, India.

⁵Professor, Department of Pathology, Pt. B.D Sharma Post Graduate Institute of Medical Sciences, Rohtak, Haryana, India

⁶Professor, Department of Pathology, Pt. B.D Sharma Post Graduate Institute of Medical Sciences, Rohtak, Haryana, India

Corresponding Author: Dr Shivani Bhargava

DOI: <https://doi.org/10.52403/ijhsr.20240528>

ABSTRACT

Introduction- Bronchial carcinoids are slow growing tumours that are usually asymptomatic until later stages and mimic most benign conditions clinically. Clinical diagnosis of carcinoid tumour of lung may be challenging because of its rare incidence and rare presentation with classical carcinoid syndrome. Bronchoscopy is the gold standard for early diagnosis followed by histopathology. Surgical resection is the treatment of choice for patients with no evidence of systemic metastasis.

Material and Methods: A 28-year-old Indian male, non-smoker presented with complaint of pain in back, chest and cough with haemoptysis, first episode occurred in May 2023, post that he was normal. Second episode of cough and haemoptysis occurred in October 2023 which was not associated with any nausea or headache.

Results: Awareness can lead to early detection and avoid misdiagnosis. Bronchoscopy is the gold standard. Surgical resection is for early diagnosis followed by histopathology.

Keywords: Carcinoid tumour, Neuroendocrine tumour, Chemotherapy, prognosis

INTRODUCTION

Bronchial carcinoids are slow growing tumours that are usually asymptomatic until the later stages and mimic most benign conditions clinically.¹ A pulmonary carcinoid tumour is a neuroendocrine tumour with indolent behaviour. Pulmonary carcinoid tumours have a relatively low incidence, ranging from 1.0% to 2.2% of all lung cancers, but could lead to death in 5-25% of patients with the disease. Pulmonary

carcinoid tumours are generally classified into two types based on histological features as follows: Typical (TC) and Atypical (AC). Compared with TCs, patients with ACs are more likely to have lymph node metastases and a worse prognosis.² Early diagnosis is extremely important to allow surgical excision which represent the treatment of choice and determines the prognosis.³

CASE REPORT

Twenty-eight years old male, non –smoker presented with complaint of pain in back, chest and cough with haemoptysis, first episode occurred in May 2023, post that he was normal. Second episode of cough and haemoptysis occurred in October 2023 which was not associated with any nausea or headache. On Chest X -ray -White opacity seen in left hilar region. On FDG PET CT-LUNG revealed heterogenous density mass measuring 3.6x3.1x3.8 cms with areas of calcification in the left lung infra hilar location involving left lung lower lobe superior segment and encasing the left lung lower lobe bronchus. On fibre optic bronchoscopy left lower lobe bronchus completely occluded. On CT -Chest myocutaneous emphysema noted in left lateral chest wall. Left sided hydropneumothorax with collapse of left lung, few secretions noted in left main bronchus. Throat culture was found positive for E. coli. Pulmonary function test was within normal limits. Clinical and radiological differentials of hamartoma /Neuroendocrine tumour were made.

Histopathological study of the excised mass showed lower left lobectomy specimen measuring 11x7x3 cm. External surface is congested. On cut section, a grey-white firm nodule is identified measuring 3.5x3x2.3 cm in lower pole. Multiple cystic spaces were identified largest measuring 0.3 cm in the greatest dimension. Microsections examined showed lung tissue and mucosal glands with foci of inflammatory infiltrate. Sections examined from grey white firm nodule show histological features suggestive of typical carcinoid tumour; well-differentiated. Showing, uniform tumour cells with polygonal shape, round to oval nuclei with salt and pepper chromatin, inconspicuous nucleoli, moderate to abundant eosinophilic cytoplasm. One lymph node isolated from the hilum of the lobectomy specimen showed reactive lymphadenitis. Sections examined from the excised margins were free from tumor infiltration. For further confirmation. a panel of immunohistochemical markers were applied. The tumor cells showed positive cytoplasmic immunoreactivity for CK, CD56, Synaptophysin and chromogranin while negative immunostaining for TTF-1, napsin and CDX2.



fig-1 Left lower lobectomy piece.

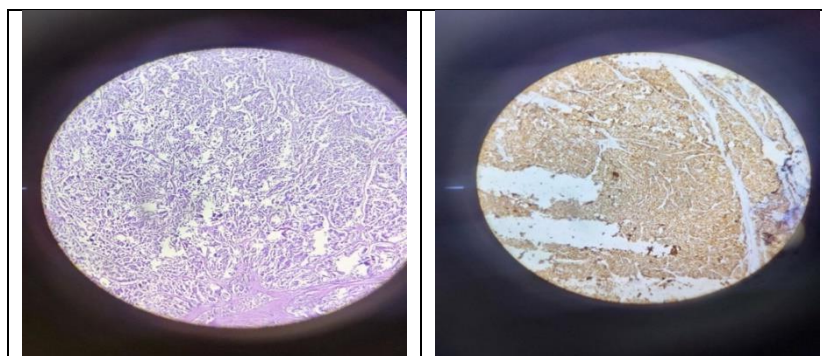


Fig-2 Immunohistochemical aspect of carcinoid tumour.

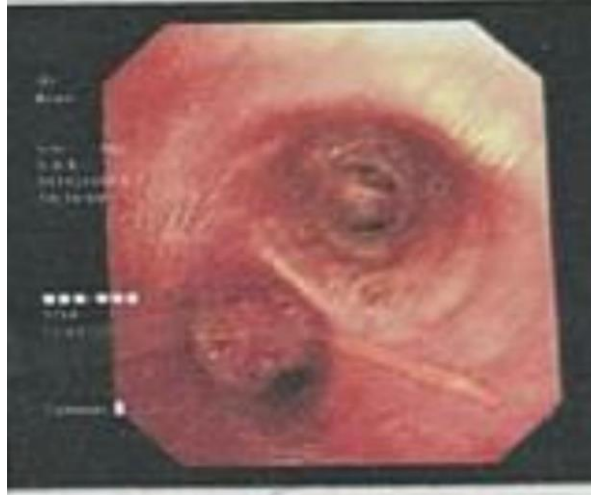

Fig-3 Endoscopic appearance of carcinoid tumour

DISCUSSION

A pulmonary carcinoid tumour is a neuroendocrine tumour with indolent behaviour. Pulmonary carcinoid tumours have relatively low incidence, ranging from 1.0% to 2.2% of all lung cancers, but could lead to death in 5-25% of patients with the disease. For carcinoid tumours, one of the most important prognostic factors is histologic subtype. As TC and AC have very different clinical features. There is no known correlation between typical carcinoid tumours and tobacco use or exposure to other carcinogens. Atypical carcinoid tumours, however, have been reported to have an association with tobacco use. Metastasis occur in 15%.⁴

- Diagnostic criteria: Tumour with size $>$ or $=$ to 5 mm with <2 mitosis /mm² and absence of necrosis.
- Neuroendocrine growth pattern or pseudoglandular, follicular and papillary growth.
- Uniform tumour cells with polygonal shape, round to oval nuclei with salt and pepper chromatin, inconspicuous nucleoli, moderate to abundant eosinophilic cytoplasm.
- Fine and highly vascularised stroma, hyalinisation, cartilage and bone formation possible

IHC can be used for confirmation of diagnosis and differentiation.

For most TC tumors surgical resection is optimal treatment. Surgical resection represents the cornerstone of the treatment.

CONCLUSION

A carcinoid tumour of the lung may be considered as a challenging disease because of its rare incidence, which most often present with non-specific pulmonary symptoms (cough, haemoptysis or recurrent pneumonia). Awareness can lead to early detection and avoid misdiagnosis. Bronchoscopy is the gold standard. Surgical resection is for early diagnosis followed by histopathology.

Declaration by Authors

Ethical Approval: Ethical approval is not requiring for this study in accordance with local/national guidelines.

Acknowledgement: The authors thank the patient who kindly consented to this case report.

Source of Funding: None

Conflict of Interest: The authors declare no conflict of interest.

REFERENCES

1. Mulukoju R, Adimulam GR, Leo S, et al. Carcinoid Tumour of the lung: Hospital-based descriptive study. J Respi 2023; 9: 220-228.
2. Yiweni Huang, Yiwei Huang, Xiaodong yang, et al. Assessment of the prognostic factors in patients with pulmonary

- carcinoid tumour: a population- based study. rep, 2018; 1-6.
3. Selma Abdala et al. lung carcinoid tumour: A case report. Sch J Med case rep, 2021 Apr9(4): 471-473.

How to cite this article: Veena Gupta, Shivani Bhargava, Vibhuti Jain, Sunita Singh, Meenu Gill, Promil Jain. Lung carcinoid tumour: a rare case report. *Int J Health Sci Res.* 2024; 14(5):224-227. DOI: [10.52403/ijhsr.20240528](https://doi.org/10.52403/ijhsr.20240528)
