

Aicardi Syndrome: Case Series

T. Rama Rao¹, C. Navyasri¹, Dwip Jyoti Kalita¹, Shahzad Alam¹, B. Pratiksha¹

¹Department of Pharm. D, CMR College of Pharmacy, Kandlokoya, Medchal, Telangana, India.

Corresponding author: T. Rama Rao

DOI: <https://doi.org/10.52403/ijhsr.20241018>

ABSTRACT

Aicardi syndrome is a rare genetic disorder that primarily affects females and is marked by three main clinical features: agenesis of the corpus callosum, chorioretinal lacunae, and seizures. The absence or abnormal development of the corpus callosum impairs communication between the brain's hemispheres, resulting in various neurological issues. Seizures, commonly appearing as infantile spasms, are frequent and can vary in severity and frequency. Aicardi syndrome is usually diagnosed in infancy through clinical evaluation and imaging studies. Effective care and management of Aicardi syndrome require a multidisciplinary approach.

Case presentation: A 2-month-old girl was brought to our hospital after experiencing multiple episodes of generalized spasticity characterized by hyperflexion of the upper and lower extremities toward the trunk (tonic seizures) and rapid jerking movements of the eyes. Additionally, she showed signs of delayed psychomotor development.

A 29-day-old girl was admitted for evaluation of abnormal movements. She was born following a normal pregnancy and delivery, with Apgar scores of 6 at 1 minute and 8 at 5 minutes. Her mother, who is 36 years old, has a history of parental consanguinity and is gravida 4, para 4, with three living children and one deceased child.

A female baby born by elective cesarean section at 36 weeks of gestation began to show symptoms, including stiffening of the arms and legs and hyperextension of the neck, with a frequency of 12-20 episodes per day.

Keywords: Aicardi syndrome, Corpus callosum, Hyperextension, Hyperflexion.

INTRODUCTION

Aicardi syndrome is an extremely rare genetic disorder that primarily affects females. Individuals with Aicardi syndrome exhibit three main characteristics: agenesis of the corpus callosum, chorioretinal lacunae, and seizures. Agenesis of the corpus callosum refers to the abnormal development of the structure that connects the two hemispheres of the brain, resulting in communication difficulties between the hemispheres.

Chorioretinal lacunae are small holes in the retina, located at the back of the eye, and can only be seen by a doctor using specialized equipment. It is highly unusual, if not impossible, for someone to have Aicardi syndrome without having chorioretinal lacunae.^[1]

Seizures associated with Aicardi syndrome can vary in type. Infants with the condition typically experience a type of seizure known as "infantile spasms," characterized by single

jerks of the entire body that may occur many times a day. During these spasms, infants are usually awake. These seizures differ from the more common "generalized tonic-clonic" seizures, which involve rhythmic jerking of the arms and legs, often accompanied by a loss of consciousness. As children with Aicardi syndrome grow, they usually outgrow infantile spasms and develop generalized tonic-clonic or other types of seizures. Additionally, other brain abnormalities contribute to frequent seizures and intellectual disabilities in those affected by Aicardi syndrome.^[2]

Symptoms:

- **Agenesis of the Corpus Callosum:** This is the partial or complete absence of the corpus callosum, the structure that connects the two hemispheres of the brain. It leads to communication issues between the brain's hemispheres and contributes to neurological problems.
- **Seizures:**
 1. **Infantile Spasms:** These are brief, sudden jerks of the whole body, often occurring multiple times a day. They are a common early symptom in infants with Aicardi syndrome.
 2. **Other Seizure Types:** As the child grows, other types of seizures, such as generalized tonic-clonic seizures, may develop. These involve rhythmic jerking of the arms and legs and may result in a loss of consciousness.
- **Ophthalmologic Symptoms:**
 1. **Chorioretinal Lacunae:** These are small defects or holes in the retina that are typically visible only through an eye examination using specialized equipment. They are considered a hallmark of Aicardi syndrome and are crucial for diagnosis.
 2. **Other Eye Abnormalities:** Additional eye abnormalities, such as colobomas (gaps in some parts of the eye) or microphthalmia (abnormally small eyes),

may be present.

Diagnosis:

The diagnosis of Aicardi syndrome is based entirely on clinical findings. The modified diagnostic criteria require either the presence of the classic triad of symptoms or two of the classic triad along with at least two other major or supporting features. Although a specific gene for Aicardi syndrome has not been identified, several observations suggest that the disorder is caused by de novo pathogenic variants in a gene located on the X chromosome that is subject to X-chromosome inactivation.^[3]

Treatment:

Currently, there is no cure for Aicardi syndrome, but some symptoms can be managed with treatment. The primary focus of treatment is controlling the seizures and spasms associated with the disorder. Additionally, there are programs designed to assist children and their parents in managing the intellectual disabilities and developmental delays commonly seen in Aicardi syndrome. Your child's doctor will likely refer you to a pediatric neurologist, who specializes in treating nervous system disorders in children, for further evaluation and long-term management of the condition. Depending on the symptoms and severity of the syndrome, doctors in other specialties may also be consulted, including:

- ✓ Neurosurgery
- ✓ Ophthalmology
- ✓ Orthopedics
- ✓ Gastroenterology
- ✓ Physical therapy
- ✓ Speech therapy
- ✓ Occupational therapy

CASE PRESENTATION

Case 1: A girl was born at full term via vaginal delivery. At birth, she experienced a delay in crying for 5 minutes but did not

exhibit cyanosis and did not require oxygen or an incubator. She has no surgical, family, or psychosocial history. At 2 months old, she developed multiple episodes of generalized spasticity with hyperflexion of the upper and lower extremities toward the trunk (tonic seizures) and rapid jerking movements of the eyes. There was no cyanosis, fever, or loss of consciousness during these episodes. At this stage, she experienced seizures up to 7 times a day, each lasting about 10 minutes. Initially, she was given 1 mg/day of phenobarbital, which did not result in significant improvement. After a week, the dosage was increased to 2 mg/day, reducing the seizures to 2 episodes per day, and this situation persisted for about 5 months.

At 7 months old, she was evaluated at a pediatric hospital. Her weight was 6.5 kg, height was 65 cm, and head circumference was 39.5 cm. She had a broad, flat nasal bridge and a wide mouth, along with signs of delayed psychomotor development, such as difficulty standing with support, holding her head up, and rolling from stomach to back and vice versa.

The clinical impression suggested a congenital neurological defect. To further assess her condition, an ophthalmic exam, a thoracic spine x-ray, and an MRI were conducted.

The ophthalmic examination revealed

bilateral medial strabismus without nystagmus, normal optokinetic responses, and reactive pupils. Retinal examination showed bilateral small peripapillary well-circumscribed chorioretinal lacunae with hyperpigmented borders, and the optic disc was normal. The thoracic spine x-ray (AP view) showed hemivertebrae and reduced height in the 7th and 8th thoracic vertebral bodies.

MRI findings included subependymal grey matter heterotopia with a nodular pattern, underdevelopment of the left operculum, hypogenesis of the inferior vermis, hypogenesis of the posterior part of the corpus callosum, and multiple cysts with peripheral enhancement. Two of the cysts were interhemispheric, one was in the posterior horn of the left ventricle, and one was in the posterior horn of the right ventricle.

The presence of these characteristic MRI findings, along with the chorioretinal lacunae and frequent tonic seizures, confirmed the diagnosis of Aicardi syndrome and excluded other potential conditions such as Dandy-Walker syndrome, agenesis of the corpus callosum, and Lennox-Gastaut syndrome. As part of her follow-up care, her seizures are regularly reassessed, and her psychomotor development is monitored during her visits every three months.

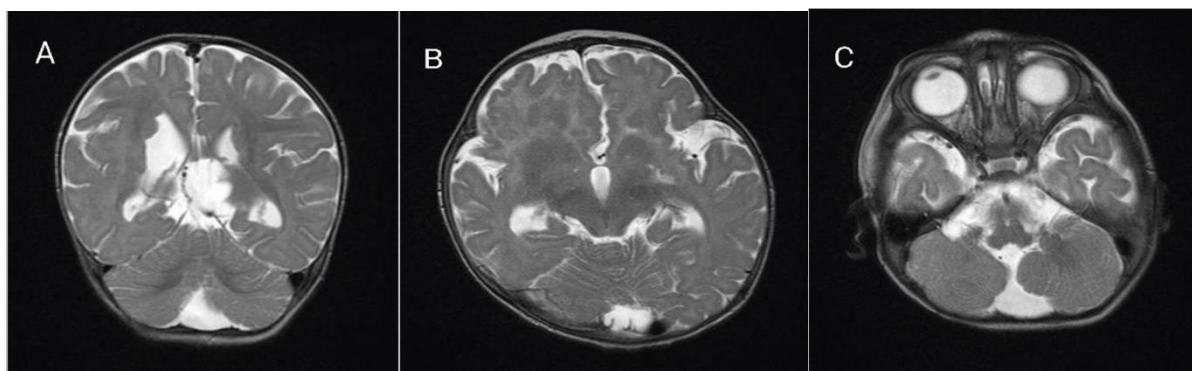


Fig. 1: Magnetic resonance imaging (MRI) for our patient at the age of 7 months. A: coronal T2-weighted image showing subependymal grey matter heterotopia.

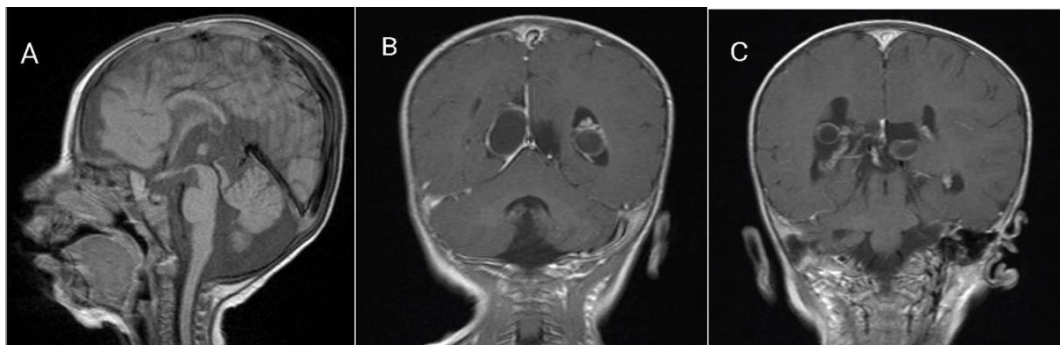


Fig. 2: Magnetic resonance imaging (MRI) for our patient at the age of 7 months. A: sagittal T1-weighted image showing hypogenesis of corpus callosum.

Case 2: A 29-day-old girl was admitted for evaluation of abnormal movements. She was born following a normal pregnancy and delivery, with Apgar scores of 6 at 1 minute and 8 at 5 minutes. Her mother is 36 years old, with a history of parental consanguinity, and is gravida 4, para 4, with three living children and one deceased child. The girl's birth weight was 3500 g. The family history is significant for the death of a sibling at 1 year and 11 months of age, who began experiencing abnormal movements and spasticity at 3 months old. At 10 days old, the patient began experiencing episodes of choking while feeding and perioral cyanosis. She was diagnosed with gastroesophageal reflux and started on Ranitidine. At 29 days old, she presented with abnormal movements in the upper and lower extremities, upward rolling of the eyes, lip-smacking, choking-like episodes that did not improve with medication, and spasticity

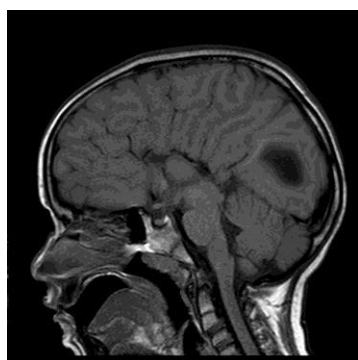

Fig 1: MRI brain that showed hypoplasia of corpus callosum.

Case 3: We present a case of a female infant born via elective cesarean section at 36 weeks of gestation to a 42-year-old mother. During the pregnancy, multiple ultrasound assessments were conducted, with an initial suspicion of Dandy-Walker syndrome. At birth, the baby weighed 2090 g, measured 42 cm in length, and had an APGAR score of 8/10. No congenital diseases were reported in the family history. At 15 days old, the first symptoms appeared, including stiffening of the arms and legs, and hyperextension of the neck, occurring 12-20 times per day. A physical examination showed that the patient was alert with normal newborn reflexes, but also revealed bilateral iris colobomas resembling a cat's eye, mild scoliosis, and missing ribs 7-9. Given the clinical presentation of infantile spasms and bilateral iris colobomas, magnetic resonance imaging (MRI) was performed. The MRI revealed agenesis of the corpus callosum, a multiseptated interhemispheric cyst communicating with the ventricular system, and bilateral coloboma cysts. Based on the MRI findings, the patient was referred to the pediatric neurology department, where an electroencephalogram (EEG) was conducted. The EEG showed frequent paroxysmal activity throughout the recording, characterized by generalized polyspikes (high voltage and slow waves located in the left hemisphere), confirming the diagnosis of infantile spasms. Due to the presence of

infantile spasms and agenesis of the corpus callosum, Aicardi syndrome (AS) was suspected. The patient was then referred to the ophthalmology department, where an ophthalmoscopy revealed multiple hypopigmented chorioretinal lesions corresponding to chorioretinal lacunae. With the presence of corpus callosum agenesis, infantile spasms, and chorioretinal lacunae,

the classic triad of Aicardi syndrome was confirmed, leading to the diagnosis. Treatment was initiated with lamotrigine, valproic acid, levetiracetam, physiotherapy, and regular follow-ups with pediatric neurology. Although the patient continues to experience infantile spasms, the frequency has significantly decreased to 10-12 episodes per day.

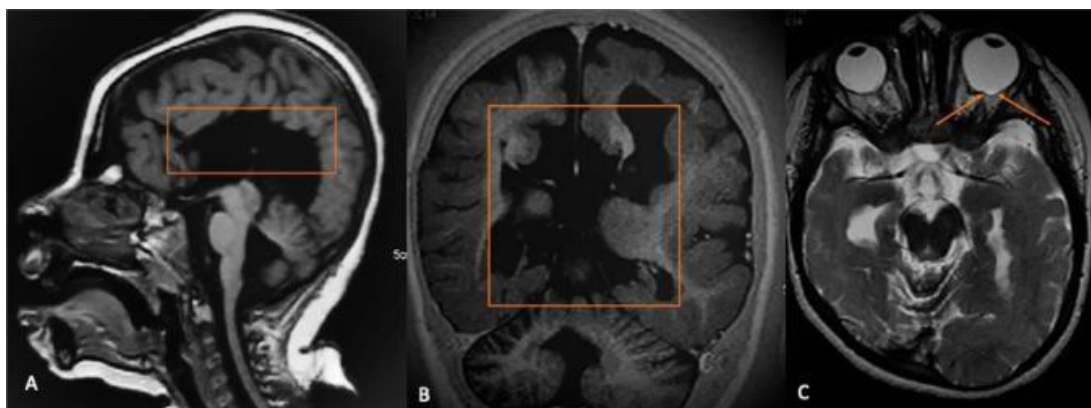


Fig 1: Brain MRI. T1-weighted image shows agenesis of corpus callosum (orange box in A) and a multiseptated Inter hemispheric cyst (orange box in B). T2-weighted image shows a left coloboma cyst located in the posterior portion of the left eyeball.

DISCUSSION

In 1965, Aicardi described a combination of agenesis of the corpus callosum, infantile spasms, and ocular abnormalities, which comprise the syndrome now named after him. Aicardi syndrome is a rare genetic disorder, with an estimated 853 cases in the US and over 4,000 cases worldwide. It is believed to be inherited in an X-linked dominant pattern due to a mutant gene on the X chromosome that is lethal in XY males. However, it can occur in males with Klinefelter syndrome (47, XXY). One major challenge in diagnosing Aicardi syndrome is the eye examination, as chorioretinal lacunae may be mistaken for findings associated with intrauterine infections, especially in infants and young children. A significant number of girls with Aicardi syndrome are born and develop normally until around three months of age, when infantile spasms begin to appear. These

spasms are often the first symptoms that prompt clinicians to conduct further investigations.^[5]

CONCLUSION

Diagnosing Aicardi syndrome requires a multidisciplinary approach involving ophthalmology, radiology, and pediatric neurology to accurately identify the classic triad of symptoms and confirm the disease. Clinical suspicion of Aicardi syndrome should be raised in any newborns who exhibit stiffening of the arms and legs, making MRI and electroencephalogram essential for establishing the diagnosis. Costovertebral anomalies should also be investigated in all patients with Aicardi syndrome.

Declaration by Authors

Acknowledgement: None

Source of Funding: None

Conflict of Interest: The authors declare no conflict of interest.

REFERENCE

1. V. Reid Sutton; Aicardi syndrome; National organization of rare disease; 2023(August).
2. Hopkins B; Neruoinaging aspects of aicardi syndrome; AM J.Med Gene A; 2008, 146A(22), 2871-8.
3. MD and Ignatia; Aicardi syndrome; Gene reviews; 30(June), 2006.
4. Carmella wint; Aicardi syndrome; Health line;

- 31(March), 2007.
5. Graziella zakaia; Aicardi syndrome: case report; European Journal of Biomedical and Pharmaceutical science; 2018, 5(8), 81-82.

How to cite this article: T. Rama Rao, C. Navyasri, Dwip Jyoti Kalita, Shahzad Alam, B. Pratiksha. Aicardi syndrome: case series. *Int J Health Sci Res.* 2024; 14(10):176-181. DOI: <https://doi.org/10.52403/ijhsr.20241018>
