

Case Report

## **Role of Physiotherapy in Juvenile Pilocytic Astrocytoma of Brainstem: A Case Report**

Shailesh Gardas<sup>1</sup>, Neha Sawant<sup>2</sup>

<sup>1</sup>Assistant Professor, MGM College of Physiotherapy, Navi Mumbai, Maharashtra, India,

<sup>2</sup>MPT Student, MGM School of Physiotherapy, Navi Mumbai, Maharashtra, India,

Corresponding Author: Shailesh Gardas

### **ABSTRACT**

Juvenile Pilocytic Astrocytoma is a rare childhood tumour with excellent prognosis. Usually grade I and Grade II Astrocytomas are benign and are slow growing. Symptoms of these tumours depend upon their size and location within brain. We herein review a case of 16 years old child diagnosed with grade I Pilocytic Astrocytoma (PA). Patient was initially treated with ventriculoperitoneal (VP) shunting followed by excision of tumour. Role of physiotherapy rehabilitation in recovery is discussed.

**Keywords:** Pilocytic Astrocytoma, brainstem tumours, ventriculo-peritoneal shunt.

### **INTRODUCTION**

Juvenile Pilocytic Astrocytoma (PA) as classified by World Health Organization (WHO) are benign slow growing tumours of central nervous system. They are classified as Grade I and Grade II which are benign and called low grade tumours, while Grade III and Grade IV are malignant and called high grade tumours. <sup>[1]</sup> Incidence rate of tumours of central nervous system accounts for 5 to 10 per 100,000 populations. <sup>[2]</sup> Most common of those tumours was Astrocytoma with 34.7%. Results published from a study performed in a tertiary care centre in South India in a longitudinal study of 15 years involving 1043 patients reported most frequent tumour as Astrocytoma with 47.3% of population. <sup>[2]</sup> PA is most frequent primary brain tumour found in new born to 19-year old children. <sup>[3]</sup> Most common site of PA tumour is reported as cerebellum, brainstem, hypothalamus, optic pathway or in intramedullary spinal cord. <sup>[4]</sup> Here we present a case of low grade pilocytic astrocytoma treated with ventriculoperito-

neal shunting followed by excision & rehabilitated post operatively.

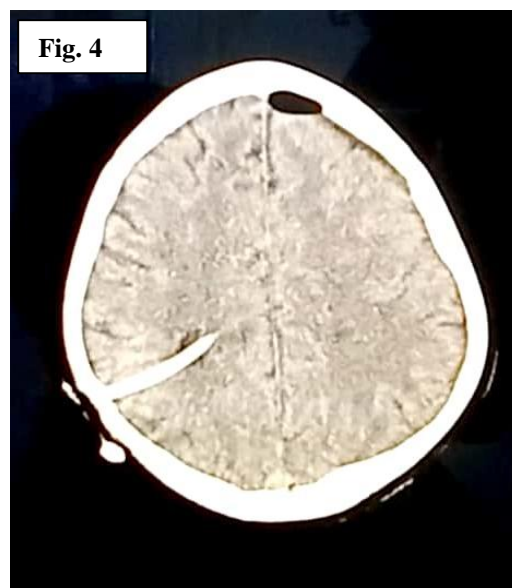
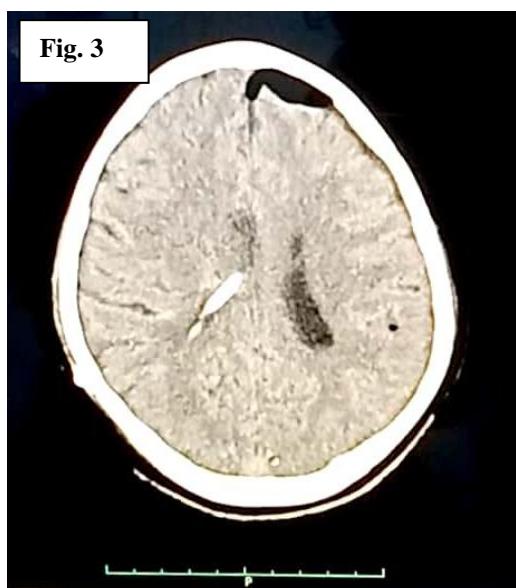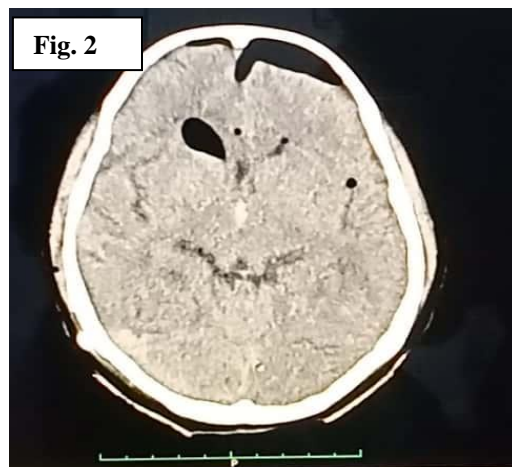
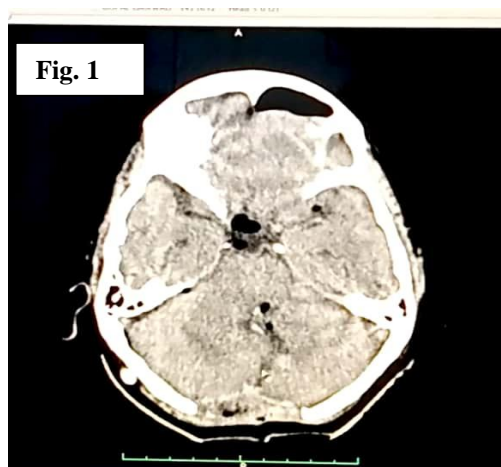
### **CASE REPORT**

Presenting here a 16 years old male child who was admitted to inpatient department of MGM hospital, Maharashtra, India. Patient came to MGM hospital with complains of dizziness, occipital headache, and nausea since 2-3 years which had aggravated since 7-8 months. CT brain was done which revealed brainstem tumour and hydrocephalus. During this period patient was conscious and oriented. Ventro - peritoneal shunting was done for obstructive hydrocephalus followed by observation in ICU. After 20 days of his admission, sub occipital craniotomy was done for excision of tumour since the symptoms didn't subside. Operative notes revealed grey colour, non suck able tumour seen coming out of Foramen of Magendie, adherent to medulla and pons which was excised and part of it was left adherent to brainstem. Histopathology of the mass revealed

multiple, friable, grey white tissue suggestive of low grade astrocytoma (pilocytic).

Patient was referred to Neuro physiotherapy department post operatively. Personal history revealed reduced appetite and sleep. No involvement of bladder and bowel was seen. Physical built of patient was ectomorphic and vitals were stable. On

observation facial asymmetry with left side involvement of face and left eye tarsorrhaphy was evident. Reduced upper and lower limb strength was observed on left side. Unequal weight bearing, with more on right side was observed. Generalised weakness and reduced arousal level was noticed.



Clinical examination on day 3 post operatively revealed tenderness at suture site extending from occipital protuberance to C3 vertebrae. Spasm was present on trapezius bilaterally. Patient was unable to speak. Higher mental functions were intact. He was well oriented to time, place and person. Patient was drowsy for few days initially, which improved within few days. All superficial and combined cortical

sensations were intact except, joint position sense and kinesthesia of left upper limb. Deep tendon reflexes were diminished on left side. Triceps and knee reflex was pendular. Hypotonia was present on left upper and lower limb muscles. According to MRC grading, manual muscle testing (MMT) was graded as grade 2 for upper and lower limb musculature on left side. Right side was grade 3 on MMT grading. Cranial

nerves VI on right side affected, left could not be assessed because of tarsorrhaphy. Facial nerve (VII) was affected with orbicularis oculi, corrugator and buccinators as weak functional and rest were non functional on House-Brackmann Scale. Cranial nerve VIII was affected. Patient showed saccadic movement of right eye and horizontal and downbeat nystagmus was present. Severe incoordination was present as seen by inability to perform heel to shin test, finger to nose, finger to therapist finger, rapid alternating movements correctly. Movements were slow and of poor quality, lacking finesse. Anticipatory and reactive balance was poor when assessed in sitting position.

Postoperative CT scan brain findings showed VP shunt seen in right lateral ventricle (Fig.4), pneumocephalus seen in bilateral frontal base of skull and right lateral ventricle (Fig. 2,3), blood seen in 3<sup>rd</sup> and occipital horn of left lateral ventricle (Fig. 1,3), air specks and blood clots in 4<sup>th</sup> ventricle & craniotomy noted in occipital bone.

## DISCUSSION

Pilocytic Astrocytoma usually has a benign course and is slow growing tumour. [5,6] Recurrence rates of PAs are high. Most favourable choice of treatment in such cases in paediatric population is excision of tumour. Usually children with Astrocytoma in brainstem region present with headache, dizziness, nausea, diplopia and clumsiness in movements. [6] Similar features of headache, dizziness, and nausea were observed in our patient. Clinical presentation of patient was seen to improve after VP shunting and tumour excision. Patient was referred for physiotherapy day 3 post operatively.

Physiotherapy management was given for 28 days before discharge. Functional evaluation of patient before therapy was inability to perform supine to sit and sit to stand transition, inability to stand and walk, difficulty in reaching in supported propped up sitting. His bed

mobility was affected, sitting balance was poor and patient was unable to sit erect without support. Standing and walking was not possible. Outcome measures pre treatment taken noted 37 score on functional independence measure (FIM).

### Course of rehabilitation:

1<sup>st</sup> week was aimed at improving core strength, upper and lower limb strengthening, for which trunk rotations, partial curls, active range of motion exercises for upper and lower limb which were gradually progressed to weight training by fourth week were given. Facial exercises- blowing a candle, puffing cheeks, clenching teeth, eye closure, raising eyebrows, smiling, frowning was given. Gaze stability exercises for nystagmus were taught. Patient was made to learn supine to sit transition. Frenkel's exercises in crook lying position were also started.

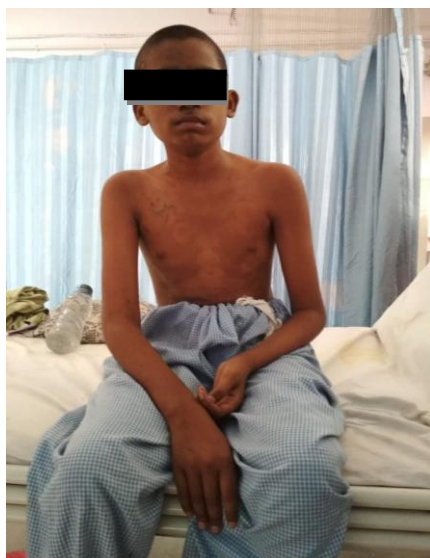By 2<sup>nd</sup> week of therapy, patient could manage bed side sitting without assistance but still had problem with maintaining erect posture, with more lean on right side. Frenkel's exercises were continued in sitting with progressions. Trunk strength mainly for obliques was increased by giving trunk PNF, specifically rhythmic stabilization bilaterally, alternating isometrics and slow reversals. By end of 2<sup>nd</sup> week, patient could sit erect without support, his visual tracking and arousal levels had improved.

3<sup>rd</sup> week of therapy included balance training in sitting and standing. Sit to stand transition was emphasised. Reach outs initially at midline, progressing towards laterally were given within base of support, progressing out of base of support. Small amplitude perturbations were introduced to balance training to improve reactive balance. Balance and equilibrium exercises- one leg standing, tandem standing, eyes open and eyes closed standing with assistance Frenkel's exercises were progressed to standing with varying range. By end of third week, patient was able to stand erect without support.

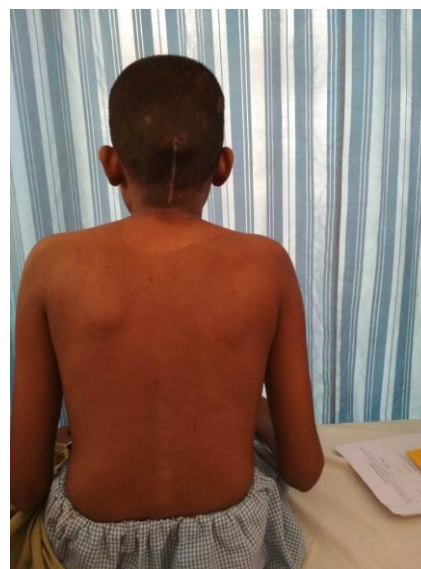In 4<sup>th</sup> week, gait training was started for patient in ward itself. Initially bilateral manual support was required. Patient ambulated with small base of support, with frequent loss of balance. Turning from right side was difficult and required more support. Gait training was initiated with forward, backward, and sideways walking with bilateral support, which was gradually reduced. Later, speed alterations- slow and fast, dual tasking- walking while talking, walking holding a glass of water, walking while counting numbers, obstacle walking- crossing and stepping over obstacle were taught to patient. By end of fourth week,

patient was independently ambulating at slow speed and could perform ADLs with minimum assistance. Post therapy FIM score was 72 Patient was discharged by end of fourth week. Home programme was given and was asked to follow up in physiotherapy OPD.

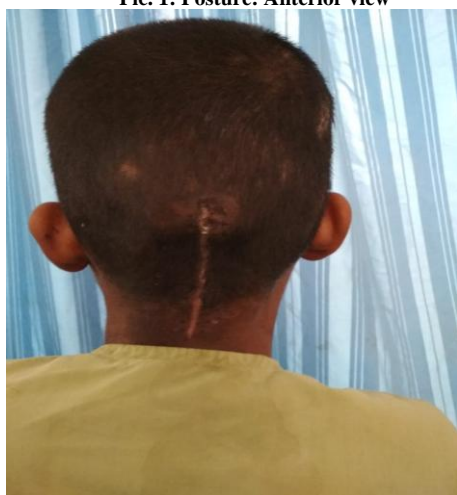In conclusion, juvenile PA is slowly growing benign in nature with less mortality rate. Hence, its complete surgical removal is possible. However, they have a high rate of recurrence, therefore we believe, timely follow up with neurosurgeon to prevent recurrence and physiotherapy treatment for faster functional recovery is advised.



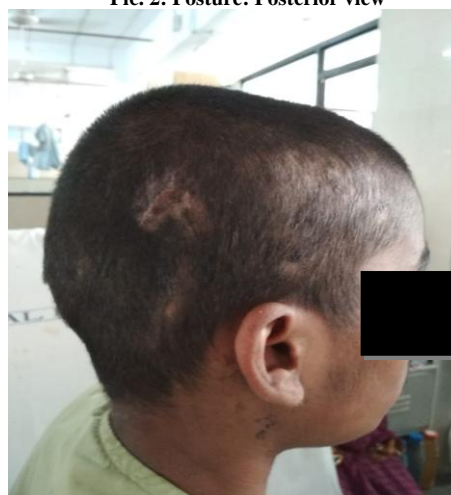Pic. 1: Posture: Anterior view



Pic. 2: Posture: Posterior view



Pic. 3: Sub-occipital craniotomy scar



Pic. 4: Ventriculoperitoneal shunt scar

#### BIBLIOGRAPHY

1. Kleihues P, Rushing E, Ohgaki H. The 2016 revision of the WHO classification of

tumours of the central nervous system. Oxford Textbook of Neuro-Oncology. 2017 Sep 1.



2. Dasgupta A, Gupta T, Jalali R. Indian data on central nervous tumors: A summary of published work. South Asian journal of cancer. 2016 Jul;5(3):147.
3. Collins VP, Jones DT, Giannini C. Pilocytic astrocytoma: pathology, molecular mechanisms and markers. Acta neuropathologica. 2015 Jun 1;129(6):775-88.
4. Ostrom QT, Gittleman H, Fulop J, Liu M, Blanda R, Kromer C, Wolinsky Y, Kruchko C, Barnholtz-Sloan JS. CBTRUS statistical report: primary brain and central nervous system tumors diagnosed in the United States in 2008-2012. Neuro-oncology. 2015 Oct 1;17(suppl\_4):iv1-62.
5. Fernandez C, Figarella-Branger D, Girard N, Bouvier-Labit C, Gouvernet J, Paredes AP, Lena G. Pilocytic astrocytomas in children: prognostic factors- a retrospective study of 80 cases. Neurosurgery. 2003 Sep 1;53(3):544-55.
6. B. Jamjoom A, Jamjoom ZA, Al-Rayess M. Intraventricular and leptomeningeal dissemination of a pilocytic cerebellar astrocytoma in a child with a ventriculoperitoneal shunt: case report. British journal of neurosurgery. 1998 Jan 1;12(1):56-8.

How to cite this article: Gardas S, Sawant N. Role of physiotherapy in juvenile pilocytic astrocytoma of brainstem: a case report. Int J Health Sci Res. 2019; 9(1):321-325.

\*\*\*\*\*