

Case Report

Homoeopathy an Alternative Therapy for Dermatophyte Infections

Piyu Amit Uttamchandani¹, Aditya Dilipkumar Patil²¹Director, Holistic Homoeopathic Center and Smart Clinic, Pune, Maharashtra, India.²Department of Homoeopathic Pharmacy, Bharati Vidyapeeth (Deemed to be) University, Homoeopathic Medical College and Hospital, Pune -43, Maharashtra, India.

Corresponding Author: Piyu Amit Uttamchandani

ABSTRACT

Dermatophytosis a disease of aerobic fungal organism affecting keratinized tissues such as the epidermis, hair and nails, has globally affected the tropical region. Clinical manifestation of these fungal infections can be confirmed by its appearance and lesions affecting throughout the various site of the host. First line of therapy has always been a topical agent; while in resistance of the topical agents next preferred treatment are the oral therapies of antifungal agents (Ketoconazole, Terbinafine, Fluconazole and Itraconazole). However complementary and alternative therapy has also shown the significant results in control of growth of these dermatophytes. Homeopathy has always been a safe and cost effective treatment in cases of dermatophyte infections. In the present case studies homeopathic medicine *Rhus toxicodendron* (30C, 200C), *Arsenic album* 30C and *Apis mellifica* (30C, 200C) had shown the antifungal activity against the dermatophytes infection. The results confirmed in this case report study needs to be extrapolated on phase 1 clinical trial with more considerable evidence and understanding the mechanism of action of ultra-diluted medicines.

Keywords: Antifungal, Dermatophytes, Homoeopathy.

INTRODUCTION

Globally affecting aerobic fungi dermatophytes which produces the proteases that is found to be affecting keratin by allowing it for inhibiting the growth of colonization and infection to stratum corneum of skin, hair shaft, and the nails. [1] This aerobic fungi are in the form of moulds classified into three genera of fungi imperfecti (1) *Microsporum*, (2) *Trichophyton*, and (3) *Epidermophyton*. [2]

Various fungal agent are found to be affecting humans viz. *T. rubrum* and *T. mentagrophytes* complex affecting skin and nail, then *T. tonsurans*, *T. violaceum*, and *M. canis* are the predominant pathogens responsible for tinea capitis. [3] These fungal species is known to cause Dermatophytosis a disease condition characterized by the infection of keratinized tissues such as the

epidermis, hair and nails. [4] Later producing the keratinases which degrades the keratin and thus, invade the superficial skin tissue. [4] In general, dermatophytes lack the ability for invading the deeper tissues or organs of the host. [4] The typical infections of ringworm of dermatophytes show the ring like appearance over the host. [4] Recently these organisms had affected those individual who are on immunosuppressive drugs for controlling serious infectious as well as non-infectious conditions. [4]

The tinea infections are found to be prevalent commonly in tropics and in geographical areas where the higher humidity, overpopulation and poor hygienic living conditions are present. (Weitzman and Summerbell 1995; Peerapur et al. 2004). Hot and humid climate of India allows these dermatophytes to invade the

superficial fungal infection of skin (Niranjan et al. 2012).

Clinical manifestations and by the characteristic distribution of lesions the diagnosis of dermatomycoses can primarily be established through observations. [5] The treatment for this dermatophytes are determined by the site and extent of lesions involved, and there efficacy, safety profile, and pharmacokinetics of the available antifungal agents. [6] First-line of therapy is the topical agents, typically imidazole antifungals. [6] In case of resistant to first line of therapy, oral therapy with antifungal agents such as ketoconazole, terbinafine, fluconazole and itraconazole are usually followed. [7] Combined therapy with topical and oral antifungals and anti-inflammatory agents has been employed in an attempt to increase the cure rate. [8] Mortality or psychological morbidity of these dermatoses are not so serious but have substantial clinical consequences like producing chronic or difficult-to-treat cutaneous

lesions. [9] Even further, they affect patients' quality of life and cause disfigurement, with impacts on self esteem and vanity, and might result in social discrimination. [10]

With the increase in resistant to available antifungal agents complementary and alternative medicine has shown significant results in the control of these dermatophytes infection. Homeopathic medicines are known to rarely produce side-effects and are also cost effective and safe in administration. Homeopathy treatment has also been found to be useful in management of psoriasis. [11,12] Homeopathy has always offered a safe and significant results in controlling the infections of cutaneous disorders, including atopic dermatitis, [13] eczema, [14] lichen striatus, [15] seborrheic dermatitis, [16] melasma, [17] rosacea, [18] dermatitis herpetiformis, [19] verruca vulgaris. [20] In the present study we have showed the results of homeopathy in dermatophytes infections in various age group affections.

CASE REPORTS –

Name.	Age/Sex.	DOCT.	Chief complaints.	Prescription.	Remark.
Mrs. M. M – (A)	Female / 52 yrs	2/10/2014	Complaints of burning & itching at neck region since 2-3 days, Red circular which is intense burning. Due to burning & itching physical restlessness. Aggravation during sleep, Aggravation rest, Better by warm application.	Rhus tox 30C three powder doses (OD). SL 3 pills for 4 days (TDS) 1 dram.	No any relapse or adverse event noted.
		6/10/2014	Itching reduced but burning yet disturbing patient. Red color of lesion is reduced. Yet physical restlessness due to burning.	Rhus tox 200C three powder doses (OD). SL 3 pills for 4 days (TDS) 1 dram.	
		11/10/2014	Patient is better. No itching. No burning. Sleep pattern good. All over complaints relief.	No medicine.	
Ms. P.M – (B)	Age 1 yr 4 month / F	10/02/2015	Complaints of eruption on chest and chin since week. Crying due to itching. Scratching the lesion and crying, shouting. Thirst: drinking in sip every 10-15 min. Can't sleep due to itching. O/E: Body is cold.	Ars.Alb 30C two powder doses (OD). SL 3pills for 2 days (TDS) 1 dram.	No any relapse or adverse event noted.
		13/02/2015:	Patient is better. Red eruption slightly less.	SL 3pills for 7 days (TDS) 1 & ½ dram.	
		21/02/2015	Patient is better. No any lesion seen on chest and chin.	No medicine	
Mr. P. U. – (C)	24 yrs /M	4/8/2016	Complaints of red circular lesion all over body since 3-4 days. Swelling present. Burning, itching. Stinging pain on an off. Aggravation heat of bed, Aggravation touch. Ameliorates cool things, cool air. Can't lie down due to burning and pain. No thirst since complaints.	Apis 30C single powder dose stat. SL powder dose (SOS).	No any relapse or adverse event noted.
		5/8/2016	Pain slightly reduced. Burning present. Thirst – Thirst decreased.	Apis 30C two powder doses (BD). SL powder dose (SOS).	
		7/8/2016	Burning reduced. But stinging pain yet present. Thirst decreased. Can't lie down.	Apis 200C three powder doses (OD). SL 4 pills for 3 days (TDS) 1 dram.	
		11/08/2016	Burning reduced. Lesions disappeared. Sleep improved. Appetite: Good. Thirst: Improved.	No medicine	

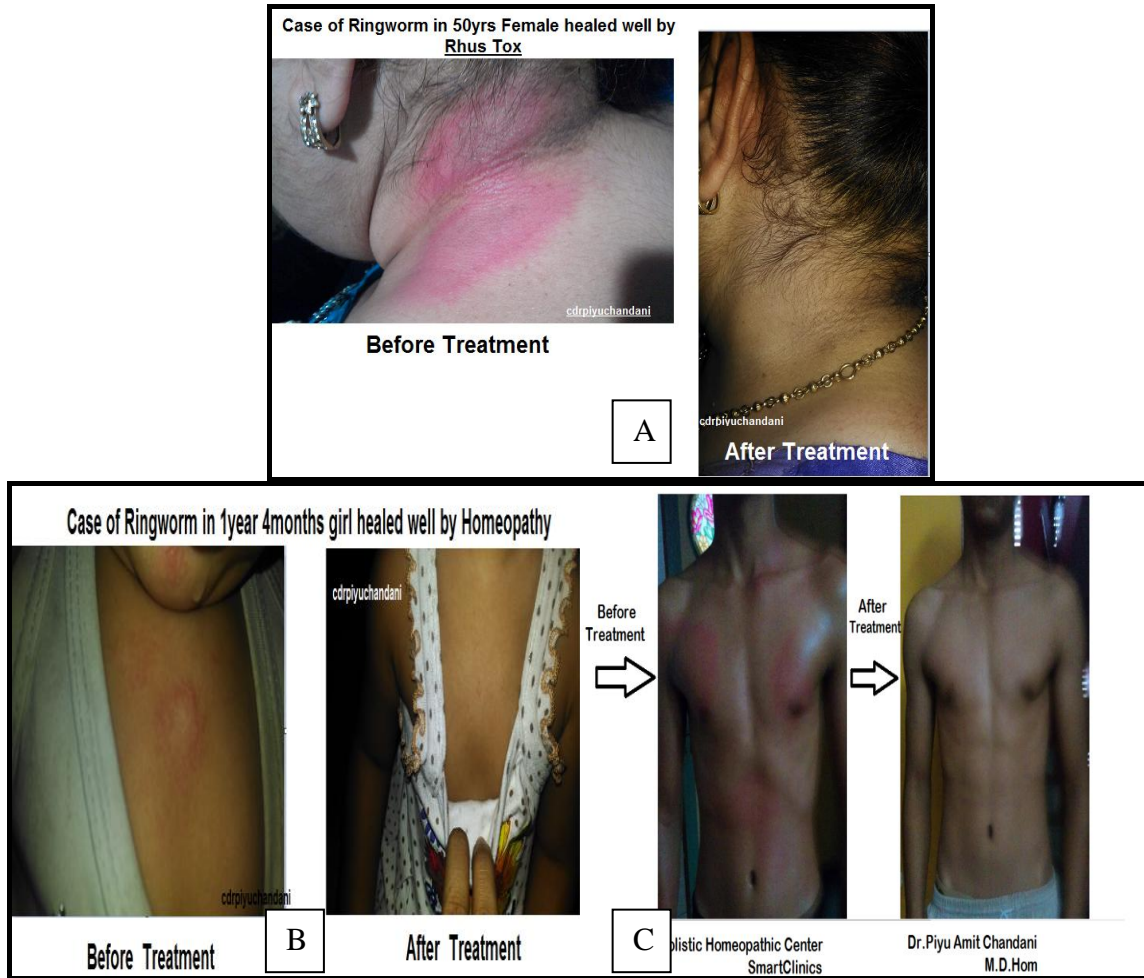


Figure – A) Before and after Rx Mrs. M.M, B) Before and after Rx Ms. P.M, C) Before and after Rx Mr. P.U.

DISCUSSION

Dermatophyte infections are challenging to treat as they get resistant after a certain period of time for the available antifungal treatments. In such situation alternative therapies are found to be effective in controlling the fungal infections. Homoeopathy has always been an alternative therapy preferred by various dermatologists. Although Homeopathic philosophy has always challenged with its ultra-high dilutions which are implausible to explain as they are beyond the Avogadro's constant unit (6.023×10^{-23}), ⁽²¹⁾ but in this case report study the ultra-high dilution homeopathic medicines 30C and 200C (10^{60} and 10^{400}) respectively has shown a significant result. Following are the three case reports of dermatophyte infections found in different age groups treated with homeopathic medicines.

Case No.1 –

A female aged 52yrs named Mrs. M. M came with complaints of burning & itching at neck region since 2-3 days with red circular rashes which had intense burning. Due to the complaints of burning & itching she was physical feeling restlessness. Complaints Aggravated during sleep and at resting position. Complaints were ameliorated by warm application. Based on these complaints the homeopathic medicine was analyzed with the help of Homopath software. Homeopathic medicine Rhus toxicodendron in 30C three powder doses (OD) and SL 3 pills for 4 days (TDS) 1 dram was prescribed. Within few days the complaints were relieved and no adverse event was recorded (Figure - A).

Case No. 2 –

A female child 1yr 4 months named Ms. P.M came with complaints of eruption on chest and chin since last week. Intense itching made her cry day and night. She

used to scratch those lesions and crying, shouting throughout complaints. Her thirst had increased, drinking in sip every 10-15 min. O/E: Body felt cold. Due to complaints her sleep was disturbed. Based on these complaints the homeopathic medicine was analyzed with help of Homopath software. Homoeopathic medicine Arsenic album 30C two powder doses (OD) and SL 3 pills for 2 days (TDS) 1 dram were prescribed. Within few days the complaints were relieved and no adverse event was recorded (Figure – B).

Case No. 3 –

A male aged 24 yrs named Mr. P.U came with complaints of red circular lesion all over body since 3-4 days. With the existing complaints parts with lesion had swelling present with burning and itching. Pain had particular stinging sensation on an off. Complaints were aggravated by heat of bed, touch. Complaints were ameliorated with cool things, cool air. He couldn't lie down on bed due to burning pain. No thirst since complaints. Based on these complaints the homeopathic medicine was analyzed with help of Homopath software. Homoeopathic medicine Apis mellifica 30C single powder dose stat and SL powder dose (SOS) were prescribed. Within few days the complaints were relieved and no adverse event was recorded (Figure - C).

CONCLUSION

Homoeopathic medicines for the treatment of dermatophytes infection as an antifungal agent has showed a significant result with cost effective and safe administration with no any side effects or adverse event seen. The results confirmed in this case report study needs to be extrapolated on phase 1 clinical trial with more considerable evidence and understanding the mechanism of action of ultra-diluted medicines.

REFERENCES

1. Gorbach SL, Bartlett JL, Blacklow NR. Infectious disease. 3rd ed. Philadelphia: Lippincott Williams and Wilkins; 2004. p. 1162-80.

2. Kanwar AJ, Mamta, Chander J. Superficial fungal infections. In: Valia GR, editor. IADVL Text book and Atlas of Dermatology. 2nd ed. Mumbai: Bhalani Publishing House; 2001. p. 215-58.
3. Zhan P, Liu W. The Changing Face of Dermatophytic Infections Worldwide. *Mycopathologia* 2017; 182: 77-86.
4. Bhatia and Sharma: Epidemiological studies on Dermatophytosis in human patients in Himachal Pradesh, India. SpringerPlus 2014 3:134.
5. Campanha AM, Tasca RS, Svidzinski TIE. Dermatômicoses: frequencia, diagnostico laboratorial e adesao de pacientes ao tratamento em um sistema publico de saude, Maringa-PR, Brasil. *Lat Am J Pharm.* 2007; 26: 442-8.
6. Kassem MA, Esmat S, Bendas ER, El-Komy MH. Efficacy of topical griseofulvin in treatment of tinea corporis. *Mycoses.* 2006; 49: 232-5.
7. Fernandez-Torres B, Cabanes FJ, Carrillo-Munoz AJ, Esteban A, Inza I, Abarca L, et al. Collaborative evaluation of optimal antifungal susceptibility testing condition for dermatophytes. *J Clin Microbiol.* 2002; 40: 3999-4003.
8. Seebacher C, Bouchara JP, Mignon B. Updates on the epidemiology of dermatophyte infections. *Mycopathologia.* 2008; 166: 335-52.
9. Wille MP, Arantes TD, Silva JLM. Epidemiologia das dermatomicoses em populacao da periferia de Araraquara - SP. *Rev Bras Clin Med.* 2009; 7: 295-8.
10. Lopes JO, Alves SH, Mari CR, Oliveira LT, Brum LM, Westphalen JB, et al. A ten-year survey of onychomycosis in the central region of the Rio Grande do Sul, Brazil. *Rev Inst Med Trop Sao Paulo.* 1999; 41: 147-9.
11. Witt CM, Lüdtkke R, Willich SN. Homeopathic treatment of patients with psoriasis – a prospective observational study with 2 years follow-up J EADV. 2009; 23: 538-43.
12. Nwabudike LC. Psoriasis and homeopathy. *Proc Rom Acad Series B.* 2011; 3: 237-42.
13. Nwabudike LC. Atopic dermatitis and homeopathy. *Our Dermatol Online.* 2012; 3: 217-20.
14. Signore RJ. Classic homeopathic medicine and the treatment of eczema. *Cosm Derm.* 2011; 24:420-5.

15. Signore RJ. Treatment of lichen striatus with homeopathic calcium carbonate. *Jl Amer Ost College Derm.* 2011; 21: 43.
16. Nwabudike LC. Seborrheic dermatitis and homeopathy. *Our Dermatol Online.* 2011; 2: 208-10.
17. Nwabudike LC. Melasma and Homeopathy. *Homeopathic Links.* 2012; 25: 99-101.
18. Nwabudike LC. Rosacea and Homeopathy. *Proc Rom Acad Series B.* 2012; 14: 207-11.
19. Nwabudike LC. Homeopathy in the treatment of dermatitis herpetiformis – a case presentation *Homeopathic Links.* 2015; 28: 44-6.
20. Nwabudike LC. Homeopathy in the treatment of verruca vulgaris – An experience of two cases. *Proc Rom Acad Series B.* 2010; 2: 147-9.
21. Prashant S. Chikramane, Akkihebbal K Suresh, Jayesh Ramesh Bellare and Shantaram Govind Kan. Extreme homeopathic dilutions retain starting materials: A nanoparticulate perspective. *Homeopathy: The Faculty of Homeopathy* 2010; 99:231-242.

How to cite this article: Uttamchandani PA, Patil AD. Homoeopathy an alternative therapy for dermatophyte infections. *Int J Health Sci Res.* 2019; 9(1):316-320.
