

Case Report

Palisaded Encapsulated Neuroma of Knee: A Rare Case

Dr. Neha Mukesh Goel

Assistant Professor, Department of Pathology, BKL Walawalkar Rural Medical College and Hospital, Taluka - Chiplun, Dist-Ratnagiri, Pincode-415606

ABSTRACT

Palisaded encapsulated neuroma also known as Solitary circumscribed neuroma is a benign cutaneous or mucosal neural tumor which, usually, presents as a solitary, firm, asymptomatic, papule or nodule. The lesions typically appear on the face; however, albeit rarely, they may also develop on the extremities, trunk, or genital region. It is essential for pathologists to be familiar with histopathology of this lesion since many lesions are probably diagnosed microscopically as neurofibroma, schwannoma or mucosal neuroma which may lead to unnecessary clinical concern or patient testing. Here, we report a case of palisaded encapsulated neuroma in knee, an unusual site. To the best of our knowledge, this is the second such case in the documented literature.

Keywords: circumscribed, neuroma, neurofibroma, palisaded encapsulated neuroma, PEN

INTRODUCTION

Palisaded encapsulated neuroma, first described by Reed and colleagues in 1972, a distinctive neural tumor, mainly affects middle-aged adults of both sexes. [1] An alternate designation i.e. solitary circumscribed neuroma (SCN) was proposed by Fletcher in 1989 when he noted that most lesions are not fully encapsulated and showed only focally palisading pattern histopathologically. [2] PEN displays histologic features of both a neurofibroma and a schwannoma. However, unlike these tumors, PEN lacks the implications for underlying systemic disease or malignancy. It is a commonly underdiagnosed and misdiagnosed tumor that, once identified clinically and histologically, can be easily excised without recurrence. [3] The lesions most commonly appear on the face but may also affect the hands, feet, trunk, glans penis, eyelid, nasal fossa and oral cavity. [3,4] PEN of knee is rare. [5] Here, we report a case of PEN in a 49-year old female in an

unusual site, with emphasis on the needs and challenges for diagnosing such lesions as they have to be differentiated from other peripheral nerve sheath tumors.

CASE REPORT

A 49-year-old female came with the chief complaint of swelling in left knee since 1 year. There was no history of previous trauma or other medical problems. There are no signs of any associated systemic disease. On examination, a subcutaneous nodule measuring 1.2x1 cms was seen on left knee. On palpation, growth was nontender and firm in consistency. There were no secondary changes associated with the growth. Routine blood investigations were normal. An excisional biopsy was done under local anesthesia and specimen was sent for histopathological examination. Grossly a well circumscribed firm nodule was sent. Microscopy reveal a well circumscribed partially thin encapsulated intradermal tumor (Figure 1)

consisting of broad interlacing elongated fascicles of bland spindle shaped cells with elongated wavy nuclei & eosinophilic cytoplasm and separated by cleft like spaces (Figure 2). The nuclei showed palisading arrangement of the tumor cells with rudimentary verocay bodies (Figure 3). Few nerve fascicles were present in the periphery. No organization into Antoni A and Antoni B areas were identified. No myxoid change or hyalinization of stroma noted. No scarring or inflammatory cells were seen. No nuclear pleomorphism or mitotic activity or necrosis was seen. Based on the above findings a diagnosis of a nerve sheath tumor was arrived. So to know the exact nature of the mass and to arrive at a conclusive diagnosis, immunohistochemical (IHC) staining was performed. On immunohistochemical analysis, interlacing fascicles of Schwann cells were S100 protein positive and Glial fibrillary acidic protein negative (Figure 4,5). Axons coursing through the lesion showed positivity with neurofilament antibody (Figure 6). Surrounding capsule exhibited epithelial membrane antigen positivity demonstrating delicate layer of perineurium (Figure 7). Based on these findings; a definitive diagnosis of PEN was rendered. Patient did not have recurrence of swelling one year post-treatment.

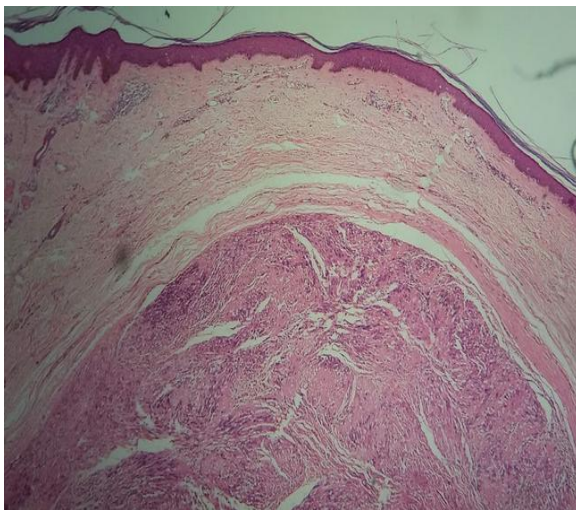


Figure 1: Well circumscribed partially thin encapsulated intradermal tumor (H & E, 4X)

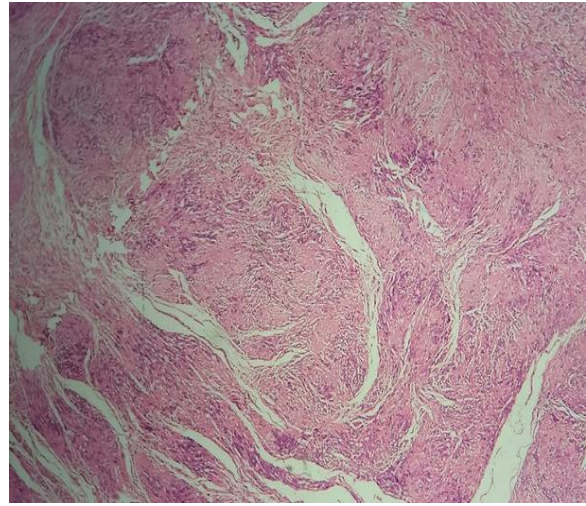


Figure 2: Broad, interlacing, elongated fascicles of spindle cells with elongated wavy nuclei (H & E, 4X)

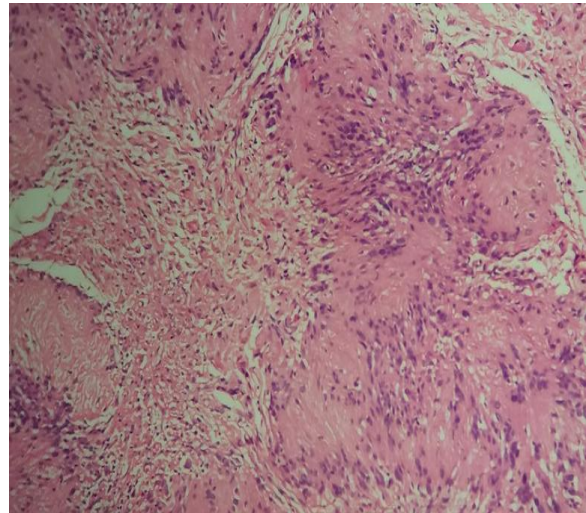


Figure 3: Rudimentary verocay bodies (H & E, 10X)

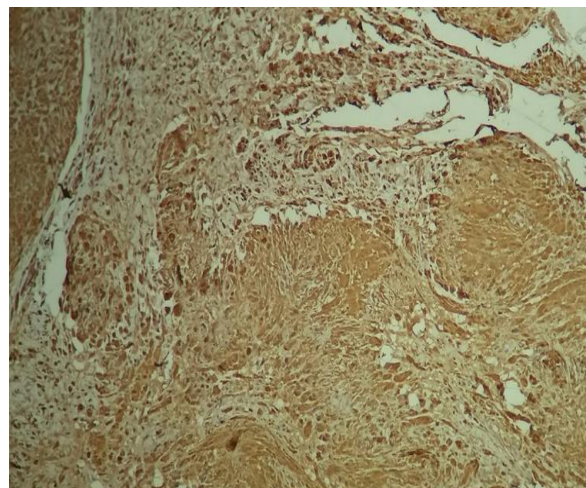


Figure 4: S-100 positive spindle cells (streptavidin-biotin immunoperoxidase-DAB, 10X)

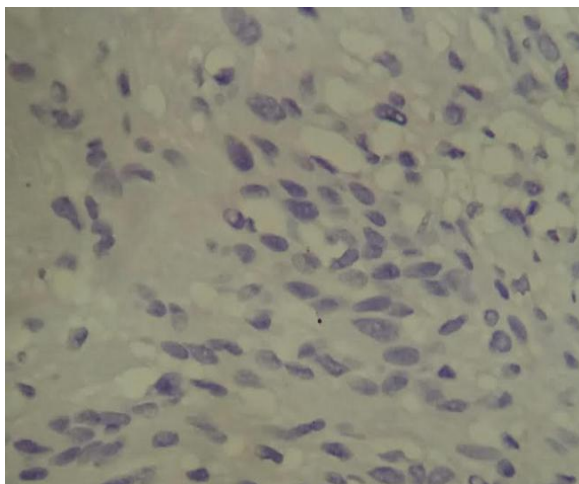


Figure 5: GFAP negative spindle cells (streptavidin-biotin immunoperoxidase-DAB,40X)

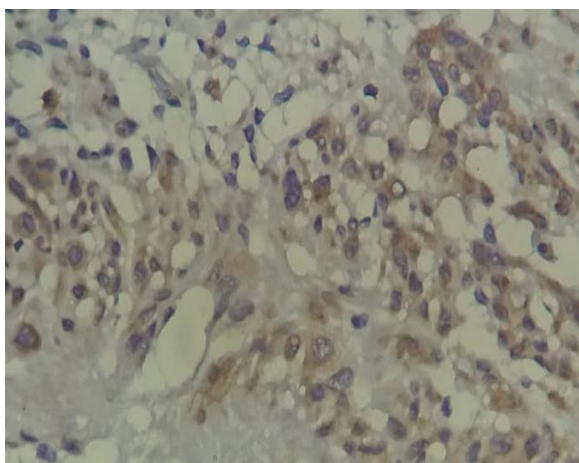


Figure 6: Neurofilament protein reveals numerous axons throughout the lesion (streptavidin-biotin immunoperoxidase-DAB,40X)

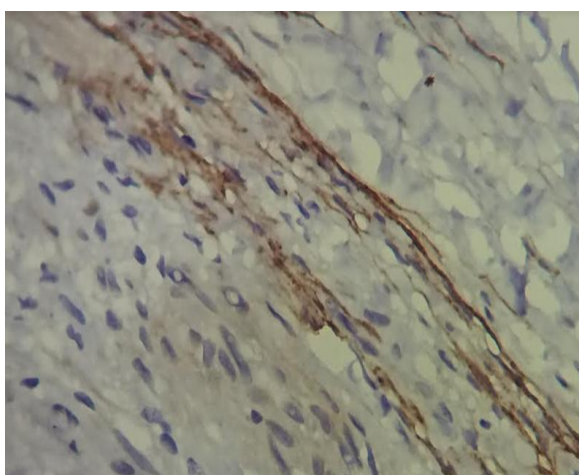


Figure 7: Capsule show EMA positivity (streptavidin-biotin immunoperoxidase-DAB,40X)

DISCUSSION

Palisaded encapsulated neuroma; also known as SCN is a clinically distinctive, solitary, benign cutaneous or

mucosal tumor. [6] PEN is not known to represent a sign of underlying disease and may be excised without recurrence. [3] PEN is most often found on the face or close to the mucocutaneous junction. However, reports have described these lesions occurring on the eyelid, oral mucosa, nasal fossa, shoulder, arm, hand, foot, trunk, and glans penis. [5] To date, only one case of palisaded encapsulated neuroma of knee has been described in the literature by Tiwari AK et al in a 45 yrs old male. [5] There is no sex preponderance, and the lesion is most frequently diagnosed between the fifth and seventh decades of life. [6] Reed, et al observed equal frequency in both sexes, but recent evidence suggests that the condition exhibits a slight female predilection. [1,3]

Clinically, these lesions are solitary, sessile, firm, pink or flesh colored, dome-shaped papule or nodule. Size of the lesion, usually, varies between 2 and 6 mm with a slow progression in the growth of tumor seen over a number of years. [1,7,8] Multiple lesions are rarely found. [9]

Regarding the pathogenesis of PEN; it remains a matter of debate. The cause is uncertain, but trauma may play an etiologic role in some cases. [10] Irrespective of terminology; PEN are regarded as hyperplasia of nerve fibers, axons and accompanying Schwann cells. [11] Hence, this tumor is generally considered to represent a reactive (hamartomatous) lesion rather than a neoplasm. [10]

Histologically, appearance is characteristic, and tumor appears well circumscribed. Tumor consists of partially encapsulated mass of moderately cellular interlacing fascicles of spindle cells that are consistent with Schwann cells. Tumor cells are poorly delineated with eosinophilic cytoplasm. Basophilic nuclei are characteristically wavy and pointed with no significant pleomorphism or mitotic activity. [1,8,12,13] Palisading of nuclei is also seen. [6] These features were in accordance with the histopathologic features in the present case.

Since there are similarities and overlap in features of peripheral nerve sheath tumors; a histologic correlation along with IHC staining is needed to arrive at a definitive diagnosis. [6] Lesions of PEN must be differentiated from neurofibroma, schwannoma, traumatic neuroma, mucosal neuroma. [2,7,8,14] Differentiation from neurofibroma is critical since the latter is often associated with neurofibromatosis, and has a tendency for malignant conversion. [3] Neurofibroma is not encapsulated and shows hypocellular sheets, mucoid matrix with delicate collagen and mast cells in significant amounts. [11] Neurofibroma can be GFAP positive. [15] Schwannoma is uncommon in the dermis, has a complete capsule and reveals cellular fascicular Antoni A (with verocay bodies) and more definite palisading in the nuclei than that in PEN/SCN. Schwannoma lacks axons (Neurofilament negative) and can be GFAP positive. [15,16,17] Traumatic (amputation) neuroma has a history of trauma and the lesion is commonly painful with occasional burning sensation or paresthesia. [18,19] Traumatic neuroma shows perineural cells rimming discrete microfascicles, the larger quantity of interstitial collagen, mucoid matrix and myelin elements. [11] Moreover, absence of inflammatory cells helps to distinguish PEN from traumatic neuroma. [20] Mucosal neuroma does not have capsule and palisading nuclei. It demonstrates nerve bundles in different sizes surrounded by normal connective tissue and is frequently associated with multiple endocrine neoplasia (MEN) type 2B. [16] The lesion cells are negative for GFAP. GFAP negative immunostaining may be useful to separate PEN/SCN from other peripheral nerve sheath tumors. [21] Immunohistochemical analysis of PEN reveals presence of numerous axons within tumor which are neurofilament protein positive and spindle cells show a positive IHC reaction for S-100 protein and negative for GFAP, which is consistent with Schwann cell differentiation. [6] Peripheral, delicate capsule show EMA

positivity. [8] Similar results were noted in present study.

PEN/SCNs have an excellent prognosis; complete surgical excision is a treatment of choice and recurrence is rare. Laser therapy has also been used to manage the PEN. [22] This technique allows for adequate histological examination and is ideal for most soft tissue excisions. [23]

CONCLUSION

To conclude, we present the second case of PEN in knee, a rare location for this tumor. Importance of correctly diagnosing PEN is that patients can be reassured that excision is curative, with less chance of recurrence, and there is no indication for further investigations for malignancy. So knowledge about this tumor is imperative for both clinicians and pathologists to avoid misdiagnosis as other neural tumours that may be associated with systemic syndromes, such as neurofibromas or mucosal neuromas.

REFERENCES

1. Reed RJ, Fine RM, Meltzer HD. Palisaded encapsulated neuromas of the skin. *Arch Dermatol* 1972;106:865-70.
2. Fletcher CD. Solitary circumscribed neuroma of the skin (so-called palisaded, encapsulated neuroma). A clinicopathologic and immunohistochemical study. *Am J Surg Pathol* 1989;13:574-80.
3. Newman MD, Milgraum S. Palisaded encapsulated neuroma (PEN): an often misdiagnosed neural tumor. *Dermatol Online J*. 2008 Jul 15; 14 (7): 12.
4. Beutler B, Cohen PR. Palisaded Encapsulated Neuroma of the Trunk: A Case Report and Review of Palisaded Encapsulated Neuroma. *Cureus* 2016;8(8):e726. doi:10.7759/cureus.726.
5. Tiwary AK, Chaudhary SS, Mishra DK. Palisaded encapsulated neuroma: An uncommon tumour at uncommon location. *Our Dermatol Online*. 2016;7(4):442-444.
6. Manchanda AS, Narang RS, Puri G. Palisaded encapsulated neuroma. *J Orofac Sci* 2015;7:136-9.
7. Halder C, Sen S, Gangopadhyay A et al. Zosteriform palisaded encapsulated

- neuroma: An unusual presentation. *Indian J Dermatol* 2013;58:492
8. Dubovy SR, Clark BJ. Palisaded encapsulated neuroma (solitary circumscribed neuroma of skin) of the eyelid: Report of two cases and review of the literature. *Br J Ophthalmol* 2001;85:949-51
 9. Magnusson B. Palisaded encapsulated neuroma (solitary circumscribed neuroma) of the oral mucosa. *Oral Surg Oral Med Oral Pathol Oral Radiol Endod* 1996;82:302-4.
 10. Neville BW, Damm DD, Allen CM et al. *Oral and Maxillofacial Pathology*. 3rd ed. Philadelphia, PA, USA, Noida, India: Saunders Elsevier; 2009.
 11. Koutlas IG, Scheithauer BW. Palisaded encapsulated ("solitary circumscribed") neuroma of the oral cavity: A review of 55 cases. *Head Neck Pathol* 2010;4:15-26.
 12. Dover JS, From L, Lewis A. Palisaded encapsulated neuromas. A clinicopathologic study. *Arch Dermatol* 1989;125:386-9.
 13. Dakin MC, Leppard B, Theaker JM. The palisaded, encapsulated neuroma (solitary circumscribed neuroma). *Histopathology* 1992;20:405-10.
 14. Megahed M. Palisaded encapsulated neuroma (solitary circumscribed neuroma). A clinicopathologic and immunohistochemical study. *Am J Dermatopathol* 1994;16:120-5.
 15. Gray MH, Rosenberg AE, Dickersin GR et al. Glial fibrillary acidic protein and keratin expression by benign and malignant nerve sheath tumors. *Hum Pathol*. 1989 Nov;20(11):1089-96.
 16. Mortazavi N, Gholami A, Amini Shakib P et al. Palisaded Encapsulated Neuroma of the Tongue Clinically Mimicking a Pyogenic Granuloma: A Case Report and Review of Literature. *J Dent (Tehran)* 2015; 12: 537–541.
 17. Ghiluși M, Pleșea IE, Comănescu M et al. Preliminary study regarding the utility of certain immunohistochemical markers in diagnosing neurofibromas and schwannomas. *Rom J Morphol Embryol*. 2009;50(2):195-202.
 18. Anbinder AL, Paiva TV, Mariano RC et al. Traumatic neuroma of the lower lip. *West Indian Med J*. 2009; 58: 604–606.
 19. Lopes MA, Vargas PA, Almeida OP et al. Oral traumatic neuroma with mature ganglion cells: A case report and review of the literature. *J Oral Maxillofac Pathol*. 2009; 13: 67–69.
 20. Maharudrappa B, Kumar GS. Neural Tumours of Oral and Para Oral Region. *Int J dent Clin*. 2011; 3:34–43.
 21. Triolo D, Dina G, Lorenzetti I et al. Loss of glial fibrillary acidic protein (GFAP) impairs Schwann cell proliferation and delays nerve regeneration after damage. *J Cell Sci*. 2006; 119 (Pt 19): 3981–3993.
 22. Panthula VR. Rare or Underdiagnosed?- Solitary Circumscribed Neuroma of the Lip. *J Clin Diagn Res*. 2015; 9: ZD32–ZD34.
 23. Atarbashi-Moghadam S, Lotfi A, Salehi Zalani S et al. Palisaded Encapsulated (Solitary Circumscribed) Neuroma of the Buccal Mucosa: a Rare Case. *J Dent (Shiraz)*. 2017 Dec;18(4):314-317.

How to cite this article: Goel NM. Palisaded encapsulated neuroma of knee: a rare case. *Int J Health Sci Res*. 2018; 8(9):300-304.
