

Case Report

## Pyrexia of Known Origin and Rapidly Increased Right Sided Empyema Diagnosed As Ruptured Amoebic Liver Abscess

Umakanth M

Senior Lecturer in Medicine, Department of Clinical Sciences, Faculty of Health Care Sciences, Eastern University, Sri Lanka.

### ABSTRACT

Amoebic liver abscess occurs worldwide, it is estimated that roughly 40 to 50 million people develop colitis or extraintestinal disease annually with 40,000 deaths. It is measured the third most common parasitic infection worldwide with around 500 million infections per year and a leading cause of parasite-related mortality with over 100,000 deaths annually. In most cases the infections are asymptomatic, however extraintestinal invasion in the form of liver abscess causing abdominal pain and fever. We reported case with pyrexia of unknown origin with right sided chest pain with progressive chest radiographic changes. Ultimately, we diagnosed as ruptured amoebic liver abscess. The lungs are the second most common site of extraintestinal infection, with pleural invasion accounting for 2-3% of patients with invasive disease.

**Keywords:** Amoebic liver abscess, Amoebiasis, *Entamoeba histolytica*.

### INTRODUCTION

Liver abscess due to amoeba is one of the common space-occupying diseases of the liver, mainly in developing countries like Sri Lanka and India. However, in developed countries liver abscess also seen migrants who travelled to endemic areas. [1] This infection is caused by protozoa *Entamoeba histolytica*. Those who are chronically carry *Entamoeba histolytica* shed cysts in their faeces transmitted disease to others. From the cysts, trophozoites are formed which adhere to the colonic mucosae and penetrate the mucosal layer. Some of the *Entamoeba histolytica* enter in to the mesenteric venules, and portal vein and reached liver where they formed abscess. Mechanism of pulmonary involvements could be due to sympathetic serous effusion or rupture of liver abscess leading to empyema or direct haematogenous spread to lung parenchyma. [2] Furthermore, the reasons behind the progression from intestinal amoebiasis to an amoebic liver abscess are not fully

understood. However, those who had low cell-mediated immunity, genetic susceptibility, malignancy, alcoholism, malnutrition and age may increase the risk of liver involvement. [3,4] The most common presentations of liver abscess are right upper quadrant pain which radiate to right shoulder with high fever. However, we reported case with pyrexia of unknown origin with right sided chest pain with progressive chest radiographic changes. Ultimately, we diagnosed as ruptured amoebic liver abscess.

### CASE HISTORY

A 34-year-old farmer complained of fever and body pain for last 3 weeks duration. It was high grade, intermittent fever, and came 3-4 episodes per day. Last couple of days complained of sort of breath and right sided chest pain. On admission, we thought that it could be community acquired pneumonia. We ordered chest X-ray, it was normal (figure 1). On examination, he looked ill, febrile, toxic,

blood pressure 100/80 mm/Hg, pulse rate 110/min, and respiratory rate 18/min. However, his white blood count revealed neutrophil leukocytosis (WBC  $21 \times 10^9/l$ ) with high inflammatory markers (ESR 120mm/h) CRP 65, ALT 36 IU/l, AST 42IU/L and total bilirubin 0.6mg/dl. Second day of the admission, he complained worsening right sided chest pain and short of breath, repeat chest X-ray was ordered, which revealed evidence of right sided elevated diaphragm and right lower zone opacity (Figure 2). Abdominal ultrasound revealed that ruptured liver abscess and right lung empyema. Third day of the admission, Chest x-ray revealed that moderate to severe empyema (Figure 3). Same day, surgical team inserted intercostal drainage tube, chocolate colour pus was drained, later it was confirmed as amoebic liver abscess. This patient was treated with intravenous metronidazole and third generation cephalosporin cefotaxime. The empyema was treated by fixation of an intercostal tube with good response. On discharge most of his laboratory parameters were normal.

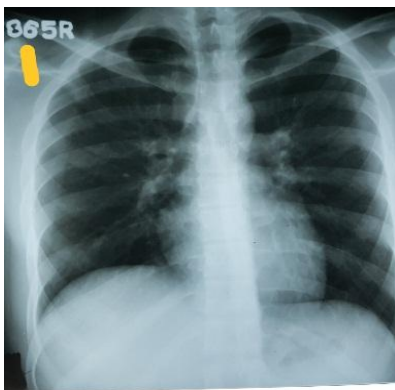


Figure 1 Normal chest X-ray

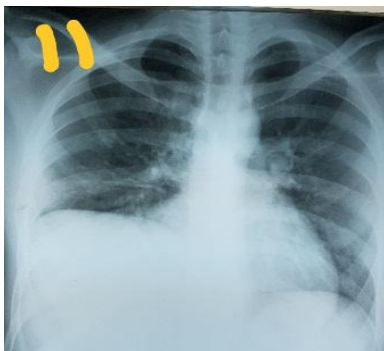


Figure 2 Elevated right hemidiaphragm

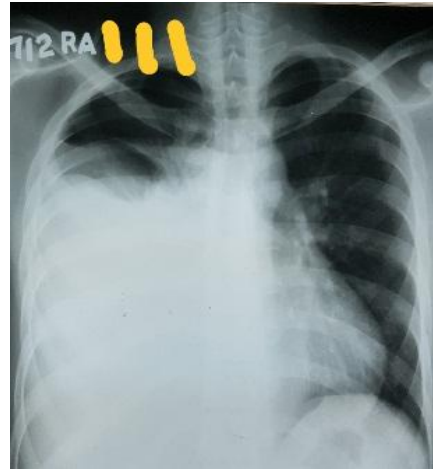

Figure 3 Right sided empyema

## DISCUSSION

Amoebic liver abscess is a common problem in the world; however it is more prevalence among developing countries. It has been reported that nearly 40-50 million people are affected annually in the world. [5] It can typically present with right upper quadrant pain and fever, however right quadrant pain is not always present. [6] There are number of atypical presentations have been reported including involvement of brain, lungs, heart, ameboma. [7,8] Mechanism of pulmonary involvements could be due to sympathetic serous effusion or rupture of liver abscess leading to empyema or direct haematogenous spread to lung parenchyma. However, only 10% of cases revealed *E. histolytica* from the amoebic empyema. [9] The diagnosis mainly based on detection of antibodies against *E. histolytica* in the serum and a negative bacterial culture of the pleural fluid. We reported a case of right sided empyema, it initially misdiagnosed as right sided lower lobe of community acquired pneumonia, and second day of the admission it causes marked changes in the right lower zone. Same day ultrasound confirmed as right sided empyema complicated with liver abscess. The underlying mechanism of amoebic empyema is that the liver abscess burst in to or advances to and across the diaphragm in to right pleural space. [10,11] However, in this case ruptured liver abscess was observed by ultrasonically. Amoebic liver abscess is a treatable disease and

complicated with empyema needed percutaneous intervention. The mortality in ruptured amoebic liver abscess is higher than non-ruptured which needed prolonged hospital stay.

## CONCLUSION

It is obvious that amoebic liver abscess is a common problem in tropical countries. Early diagnosis and immediate treatment are the mainstay of the management. However, complicated with empyema needed percutaneous drainage.

### *Consent to participate*

Consent was taken from the patient

### *Consent for publication*

Written informed consent was obtained from the patients for publication of this case report

### *Availability of data and material*

All data gathered during this study are included in this published article.

### *Competing interests*

The author declares that no competing interests.

### *Funding*

This research received no funding support

## ACKNOWLEDGEMENTS

I thank the patient for accepting the publication of this article

## REFERENCES

1. Freedman, D. O., Weld, L. H., Kozarsky, P. E., Fisk, T., Robins, R., von Sonnenburg, F., Keystone, J. S., Pandey, P., Cetron MS. Spectrum of disease and relation to place of exposure among ill returned travelers. *N Engl J Med.* 2006;354:119–130.
2. Abiodun M, Osarogiagbon W, Oviawe O. Pyogenic liver abscess mimicking pleural effusion. *South African Fam Pract [Internet].* 2012;54(5):459–62. Available from: [http://www.embase.com/search/results?subaction=viewrecord&from=export&id=L366053277%5Cnhttp://www.journals.co.za/WebZ/images/ejour/mp\\_safp/mp\\_safp\\_v54\\_n5\\_a19.pdf?sessionid=01-55738-89496325&format=F%5Cnhttp://sfx.library.uu.nl/utrecht?sid=EMBASE&issn=1726](http://www.embase.com/search/results?subaction=viewrecord&from=export&id=L366053277%5Cnhttp://www.journals.co.za/WebZ/images/ejour/mp_safp/mp_safp_v54_n5_a19.pdf?sessionid=01-55738-89496325&format=F%5Cnhttp://sfx.library.uu.nl/utrecht?sid=EMBASE&issn=1726)
3. Park, W. B., Choe, P. G., Jo, J. H., Kim, S. H., Bang, J. H., Kim, H. B., Kim, N. J., Oh, M. D. & Choe KW. Amebic liver abscess in HIV-infected patients, Republic of Korea. *Emerg Infect Dis.* 2007;13:516–517.
4. Stanley S L. Amoebiasis. *Lancet.* 2003;361:1025–1034.
5. Blessmann J, Ali IK, Nu PA et al. Longitudinal study of intestinal Entamoeba histolytica infections in asymptomatic adult carriers. *J Clin Microbiol.* 2003; 41(10): 4745–50.
6. Nasrullah A, Haq S, Ghazanfar H, Sheikh AB, Akhtar A et. al. A Unique Case of Empyema Secondary to Amoebic Liver Abscess. *Cureus.* 2017 Jun 21;9(6):e1377.
7. Kale S, Nanavati AJ, Borle N et al. Outcomes of a conservative approach to management in amoebic liver abscess. *J Postgr Med.* 2017;63:16–20.
8. Kaki R, Al Ghamdi F, El-Hossary D, Al Rehily S. Amoeboma in a Saudi resident: a case report. *JMM Case Reports [Internet].* 2016;3(3):1–5. Available from: <http://www.microbiologyresearch.org/content/journal/jmmcr/10.1099/jmmcr.0.005032>
9. C I-P. Thoracic complications of amebic abscess of the liver: report of 501 cases. *Chest.* 1981;79(6):672–677.
10. Yokoyama T, Hirokawa M, Imamura Y, Aizawa H. Respiratory failure caused by intrathoracic amoebiasis. *Infect Drug Resist.* 2010;3(1):1–4.
11. Rahimian J, Wilson T, Oram V HR. Pyogenic liver abscess: Recent trends in etiology and mortality. *Clin Infect Dis.* 2004;39(11):1654–9.

How to cite this article: Umakanth M. Pyrexia of known origin and rapidly increased right sided empyema diagnosed as ruptured amoebic liver abscess. *Int J Health Sci Res.* 2018; 8(7):377-379.

\*\*\*\*\*