

Original Research Article

Morphometric Study of Subthalamic Nucleus in Adult Human Cadaveric Brain

Mangala Kohli¹, Athira PA², Reeha Mahajan³

¹Director Professor and Head, Vardhaman Mahavir, Medical College & Safdarjung Hospital, New Delhi

²Post Graduate, Lady Hardinge Medical College, New Delhi

³Visiting Faculty Anatomy, ISIC Institute of Rehabilitation sciences, New Delhi

Corresponding Author: Reeha Mahajan

ABSTRACT

The subthalamic nucleus (STN) is a biconvex nucleus situated in the diencephalon. The knowledge of the morphometry of the subthalamic nucleus is essential for accurate targeting of the nucleus during Deep Brain Stimulation. The present study aims to note the morphometry of the subthalamic nucleus in both the cerebral hemispheres which will prove to be of great value to radiologists and neurosurgeons. A cross-sectional observational study was conducted in the Departments of Anatomy and Forensic Medicine, Lady Hardinge Medical College & Associated Hospitals, New Delhi on thirty adult cadaveric brain specimens of unclaimed and donated corpses. The specimens were categorized into 3 age groups: 20-35, 35-50 and above 50 years. All samples were collected after following the standard protocol for ethical clearance. The morphometric study of 60 subthalamic nucleus were thus conducted. Transverse section of the brain was made at a plane 4mm ventral to the plane containing mid commissural point. The dimensions of the subthalamic nucleus were measured bilaterally with the aid of digital Vernier caliper and magnifying glass. In the present study, the mean length and width and AC-PC length of the subthalamic nucleus were recorded on the right and left side in Group A, B and C. On comparison of mean of subthalamic nucleus dimensions between the right and left side in Group C, no statistically significant difference was observed. The length and width of subthalamic nucleus measured in the 3 age groups were compared with each other and the p value calculated. There was no statistically significant difference between the dimensions of Group A and B, Group B and C as well as Group A and C. The present study reveals that there is no significant reduction in the size of the nucleus was noted with increasing age. Thus, the values obtained in the present study can be used as reference for various invasive and non-invasive procedures on subthalamic nucleus.

Keywords: Subthalamic nucleus, morphometry, deep brain stimulation.

INTRODUCTION

The subthalamic nucleus (STN) or Corpus Luysi is a biconvex nucleus situated in the diencephalon and was first described by Jules Bernard Luys, a French neurologist, in the year 1865. ^[1] The nucleus is placed obliquely with respect to the standard anatomical axes i.e. 20° oblique to the horizontal plane, 35° to the sagittal plane and 55° to the frontal plane. ^[2] The STN which lies in the ventral subthalamic region

is related to the thalamus above and the substantia nigra below and lies dorsolateral to the red nucleus. It is in close relation to the zona incerta and lies ventral to it with the fasciculus lenticularis intervening between the two. This lens shaped structure is encapsulated by a lamina of axons mainly derived from subthalamic fasciculus and is separated from the globus pallidus of the lentiform nucleus by the medial aspect of the internal capsule. ^[3,4] In fresh sections of

brain specimens the nucleus has a café-au-lait colour. It has a rich blood supply derived from branches of the posterior cerebral artery, premamillary branches of the posterior communicating artery and peduncular branches of the anterior choroidal arteries. [5]

The knowledge of the morphometry of the subthalamic nucleus is essential as it is the target site for the neurosurgical procedure, Deep Brain Stimulation (DBS) which is used in the treatment of Parkinson's disease, essential tremors, dystonia and obsessive compulsive disorder. Thus knowledge of the morphometry of the subthalamic nucleus is essential for accurate targeting of the nucleus during Deep Brain Stimulation. The present study aims to note the morphometry of the subthalamic nucleus in both the cerebral hemispheres which will prove to be of great value to radiologists and neurosurgeons.

MATERIALS AND METHODS

The present study is a cross-sectional observational study conducted in the Departments of Anatomy and Forensic Medicine, Lady Hardinge Medical College & Associated Hospitals, New Delhi from November 2014 to March 2016 on thirty adult cadaveric brain specimens procured from the Department of Forensic Medicine from autopsies of unclaimed and donated corpses. These brains were retrieved from the donated and unclaimed bodies, registered to departments with known cause of death, unrelated to the subthalamic nucleus, the specimens were categorized into 3 age groups: 20-35, 35-50 and above 50 years. All samples were collected after following the standard protocol for ethical clearance. The morphometric study of 60 subthalamic nucleus were thus conducted. The grossly normal appearing adult cadaveric brain specimens of different age groups were included in the study while the brain specimens of individuals with known history of neurological disorder were excluded from the study. brains were

removed en bloc from the cadaver and fixed in 10% formalin. The location of the anterior commissure and the posterior commissure were identified on the medial surface of the cerebral hemisphere. The mid commissural point was then located as the midpoint of the line joining the superior part of the anterior commissure and the centre of the posterior commissure (Figure 1).

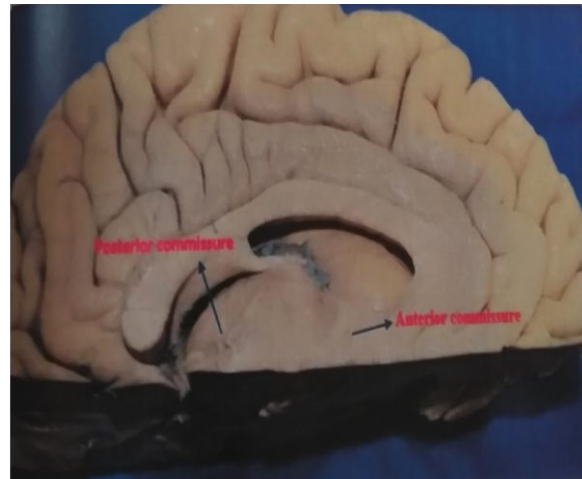


Figure 1: Transverse section of the left cerebral hemisphere made at a plane 4mm ventral to the plane of mid commissural point

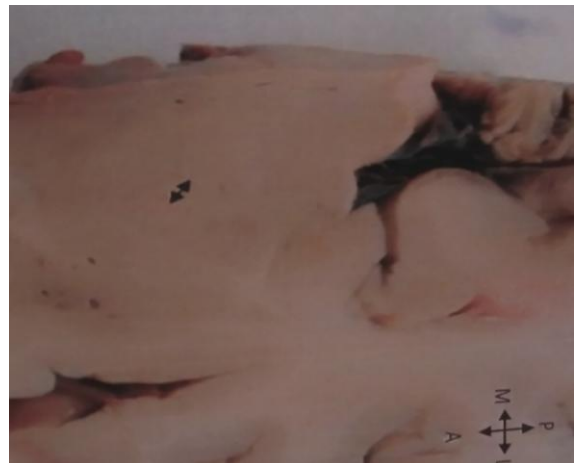

Figure 2: Transverse section 4mm ventral to plane of mid-commissural point showing width of the subthalamic nucleus

Transverse section of the brain was made at a plane 4mm ventral to the plane containing mid commissural point. [5] The brain specimens were categorized into 3 age groups, Group A: 20-35 years, Group B: 35-50 years and Group C: above 50 years. The dimensions of the subthalamic nucleus were measured bilaterally. The maximum dimension along the longitudinal and transverse axis of the biconvex subthalamic

nucleus (Figure 2,3) was measured with aid of digital Vernier caliper and magnifying glass.

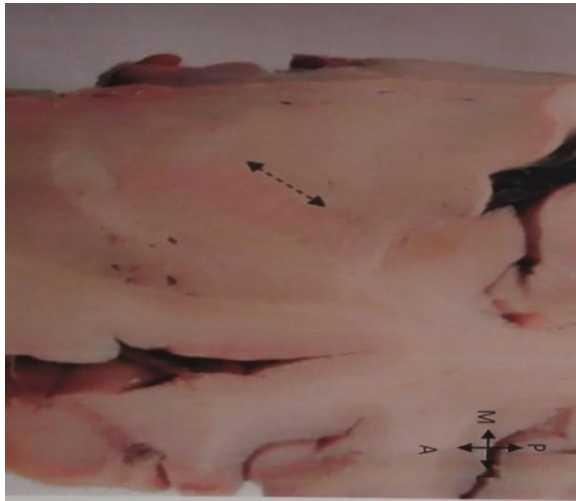

Figure 3: Transverse section 4mm ventral to plane of Mid commissural point showing length of the subthalamic nucleus

The results were analysed using Microsoft Excel 2007 and Epi Info statistical software.

RESULTS

In the present study, the length of the subthalamic nucleus in Group A was observed to be 7.68 ± 0.29 mm on the right side and 7.65 ± 0.32 mm on the left side. The width of the nucleus was recorded as 3.78 ± 0.31 mm on the right side and 3.8 ± 0.31 on the left side. The mean AC-PC length was 26.83 ± 1.02 mm on the right side and 26.77 ± 0.99 mm on the left (Table 1).

Table 1: Dimensions of subthalamic nucleus in Group A on gross morphometry

Sl. no	RIGHT HEMISPHERE			LEFT HEMISPHERE		
	AC-PC	LENGTH	WIDTH	AC-PC	LENGTH	WIDTH
1	26.42	7.73	3.37	26.38	7.68	3.34
2	29.08	7.66	3.23	28.89	7.63	3.25
3	25.49	7.41	3.52	25.45	7.44	3.57
4	27.16	7.39	3.83	27.14	7.39	3.87
5	27.08	7.26	3.79	27.05	7.29	3.81
6	26.52	7.68	3.96	26.49	7.61	4.01
7	27.14	8.12	4.02	27.08	8.17	4.06
8	25.52	7.56	3.89	25.44	7.28	3.91
9	27.32	7.83	4.08	27.31	7.89	4.11
10	26.54	8.14	4.12	26.46	8.15	4.11
MEAN	26.827	7.678	3.781	26.769	7.653	3.804
S.D	1.023611	0.294082	0.307045	0.996399	0.32643	0.314084

On comparison of mean of subthalamic nucleus dimensions between the right and left side in Group A, no statistically significant difference was observed.

The length of the subthalamic nucleus in Group B was observed to be 7.67 ± 1.28 mm on the right side and 7.65 ± 0.63 mm on the left side. The width of the nucleus was recorded as 3.75 ± 0.85 mm on the right side and 3.73 ± 0.45 on the left side. The mean AC-PC length was 26.8 ± 1.27 mm on the right side and 26.65 ± 1.06 mm on the left (Table 2).

Table 2: Dimensions of subthalamic nucleus in Group B on gross morphometry

Sl. no	RIGHT HEMISPHERE			LEFT HEMISPHERE		
	AC-PC	LENGTH	WIDTH	AC-PC	LENGTH	WIDTH
1	25.49	7.27	3.2	25.43	7.84	3.2
2	26.1	9.31	4.03	25.69	9.33	4.01
3	26.34	7.83	4.04	26.42	7.79	3.98
4	29.88	7.84	4.63	28.98	7.87	4.69
5	27.93	7.08	3.58	27.78	7.14	3.62
6	25.96	7.23	3.34	25.87	7.32	3.32
7	27.12	7.33	4.01	27.07	7.36	3.39
8	26.14	7.68	3.39	26.25	7.57	3.31
9	26.7	7.32	3.64	26.78	7.34	3.86
10	26.38	7.79	3.89	26.24	7.68	3.92
MEAN	26.804	7.668	3.775	26.651	7.724	3.73
S.D	1.274138	0.641037	0.429347	1.069709	0.617184	0.455656

On comparison of mean of subthalamic nucleus dimensions between the right and left side in Group B, no statistically significant difference was observed.

The length of the subthalamic nucleus in Group C was observed to be 7.45 ± 0.21 mm on the right side and 7.5 ± 0.2 mm on the left side. The width of the nucleus was recorded as 3.7 ± 0.47 mm on the right side and 3.6 ± 0.32 on the left side. The mean AC-PC length was 26.19 ± 1.99 mm on the right side and 26.16 ± 1.89 mm on the left (Table 3). On comparison of mean of subthalamic nucleus dimensions between the right and left side in Group C, no statistically significant difference was observed.

Table 3: Dimensions of subthalamic nucleus in Group C on gross morphometry

Sl. no	RIGHT HEMISPHERE			LEFT HEMISPHERE		
	AC-PC	LENGTH	WIDTH	AC-PC	LENGTH	WIDTH
1	27.04	7.28	3.76	27.02	7.26	3.77
2	27.07	7.38	4.61	26.94	7.43	3.66
3	24.5	7.27	3.94	24.53	7.31	3.91
4	26.67	7.6	3.11	26.69	7.8	3.19
5	28.37	7.93	3.76	28.07	7.87	3.66
6	21.2	7.32	4.01	21.4	7.38	4.02
7	27.02	7.26	3.77	26.98	7.38	3.72
8	26.69	7.58	3.12	26.64	7.61	3.15
9	27.02	7.34	3.82	27.01	7.39	3.8
10	26.38	7.54	3.14	26.41	7.56	3.12
MEAN	26.196	7.45	3.704	26.169	7.499	3.6
S.D	1.997205	0.213229	0.472139	1.893805	0.206045	0.327278

The length and width of subthalamic nucleus measured in the 3 age groups were compared with each other and the p value calculated. There was no statistically significant difference between the dimensions of Group A and B, Group B and C as well as Group A and C. The maximum length of the nucleus was noted in a brain specimen belonging to Group B in the left hemisphere (9.33mm). The maximum length was observed to be 7.08mm in the right hemisphere of a specimen of the B group. The maximum width of the nucleus was recorded in the left hemisphere of Group B i.e., 4.69mm and the minimum was noted as 3.11 in the right side of Group C. The maximum AC-PC length was observed in the right hemisphere of Group B i.e., 29.88mm and minimum on the right side of Group C (21.2mm).

DISCUSSION

The subthalamic nucleus is a biconvex nucleus situated in the diencephalon and plays an important role in the function of basal ganglia. The medial tip of the subthalamic nucleus is connected with the limbic system and it has been postulated that the side effects of DBS like

apathy, depression, suicidal tendencies etc. could be due to the stimulation of the limbic area of nucleus. In the present study, the length and width of the subthalamic nucleus were recorded in the 3 age groups in the cadaveric study and analysed. It was observed that there was no statistically significant difference between the dimensions of the right and left cerebral hemispheres. It was also found that no significant change in the dimensions of the subthalamic nucleus occurred with age. The mean values obtained in our study are much less than results obtained by Mavridis et al while there was no significant difference between the mean values of right and the left side as in the current study. [6] Similar results were also observed by Patil et al and Daniluk et al, which could be due to racial variation. [7,8]

CONCLUSION

The present study reveals that there is no significant variation in anterior commissure- Posterior commissure diameter, length and width of subthalamic nucleus between the right and left side in the 3 different age groups. Also, no significant reduction in the size of the nucleus was

noted with increasing age. Thus, the values obtained in the present study can be used as reference for various invasive and non-invasive procedures on subthalamic nucleus.

REFERENCES

1. Pearce J. The subthalamic nucleus and Jules Bernard Luys(1828-97). *Journal of neurology, neurosurgery & psychiatry.* 2001; 71(6): 783-
2. Massey LA, Yousry TA. Anatomy of the Substantia Nigra and Subthalamic nucleus on MR imaging. *Neuroimaging Clinics of North America.* 2010; 20(1): 7-27
3. Nolte J. *The Human Brain.* 4th edition. Mosby Publications.1999.p.460-2
4. Standring S. *Gray's anatomy anatomical basis of clinical practice.* 40th edition. Churchill Livingstone Elsevier. 2008. p.332
5. Tamraz J, Comair Y, Luders H. *Atlas of regional anatomy of the brain using MRI.* Berlin: Springer; 2006.p.207
6. Mavridis I, Boviatsis E, Anagnostopoulou S. Anatomy of the human subthalamic nucleus: A combined morphometric study. *Anatomy Research International.* 2013;1-8
7. Patil P, Conrad E, Aldridge J, Chenevert T, Chou K. The Anatomical and Electrophysiological subthalamic nucleus visualized by 3-T magnetic resonance imaging. *Neurosurgery.* 2012; 71(6): 1089-1095
8. Daniluk S, Davies GK, Ellias SA, Novak P, NazzaroJM. Assessment of the variability in the anatomical position and size of the subthalamic nucleus among patients with advanced Parkinson's disease using magnetic resonance imaging. *Acta Neurochirurgica.* 2010; 152(2): 201-210

How to cite this article: Kohli M, Athira PA, Mahajan R. Morphometric study of subthalamic nucleus in adult human cadaveric brain. *Int J Health Sci Res.* 2018; 8(6):47-51.
