

Case Report

## **Congenital Arhinia - A Rare Case Report**

Dr. Himali Meshram, Dr. Prashant Bhadane

Department of Paediatrics, B.J.Wadia Hospital for Children, Mumbai.

Corresponding Author: Dr. Himali Meshram

---

### **ABSTRACT**

Congenital absence of the nose or arhinia is a rare form of birth defect of often associated with other facial abnormalities. Congenital Arhinia is a life threatening condition that requires a multidisciplinary team approach which starts from highly skilled neonatologist, anesthetist, ENT surgeon and pediatric surgeon in the delivery room. The associated anomalies of congenital arhinia often have a significant effect on the immediate as well as long-term outcome of the neonate. This case report presents a rare case of congenital arhinia and its management.

**Key words** - Arhinia, congenital, birth defect.

### **INTRODUCTION**

Congenital absence of nasal bones also known as congenital arhinia is an extremely rare malformation. It causes severe airway obstruction at the time of birth and feeding problems later during the course of time in the neonate. This defect is known to have associated facial anomalies, especially defects of the eyes, ears, palate, and midline defects described in the literature.

#### **Background –**

Congenital arhinia, also called nasal agenesis is partial or complete absence of the nose at birth in a neonate. It is an extremely rare condition, with only around 47 cases reported in the literature since the first report came in 1931. <sup>(1-19)</sup> Congenital arhinia generally classified as a craniofacial abnormality due to defective embryogenesis. Congenital arhinia is complex syndrome associated with microphthalmia or coloboma of olfactory bulbs, coloboma of iris, microtia, absence of nasal cavities and high arched palate as a part of syndromic malformation.

### **CASE REPORT**

A Full term girl was born by uncomplicated cesarean section. The 26 year old primigravidae mother reported a normal pregnancy with prenatal care including sonographic findings was being normal. No history of amniotic fluid imbalances or drug intake during pregnancy.

Just after delivery, the neonatologist found the baby with absent eyes and deformity of nose showing rudimentary and blind ending nostril. The root of nose was also absent (fig.1, 2). The neonate also had sub mucous cleft palate. Baby was breathing with his mouth and there was minimal respiratory distress. No other physical abnormality was seen. Laboratory findings were normal with no obvious abnormality found. Our case had mos46,XX/47,XX,+9 on chromosomal analysis.

Spiral axial CT scan with 3mm thick sections were obtained. It showed non visualisation of nasal bones and nasal septum. Cribriform plate and crista gali were not visualized. Right nostril and nasal cavity appeared rudimentary with non-visualization of bony turbinates. Par nasal

sinuses were not visualized. There was a defect of size 1.1 cm \* 7 mm in frontal bone in left paramedian position with exophytic soft tissue of size 9.2 \* 8.6 mm at level of defect suspecting maldeveloped left nasal placode.

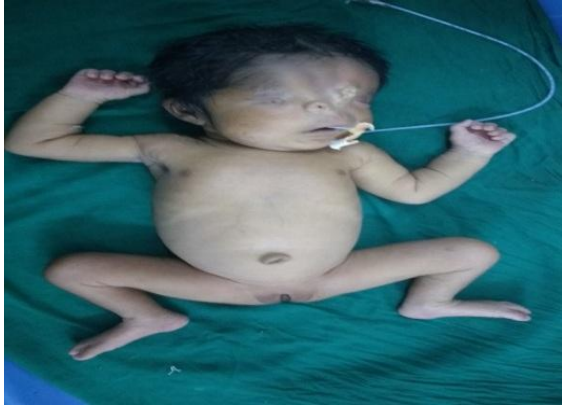

Figure 1 = Neonate

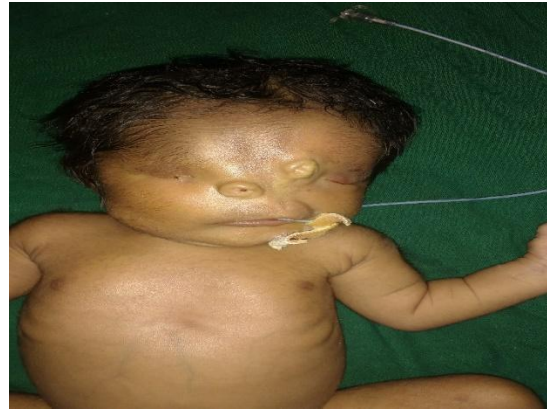

Figure 2 = Absent eyes and deformity of nose showing rudimentary and blind ending nostril

Both orbits were shallow, small with maldeveloped eyeballs (Right > Left) along with hypertelorism. The brain parenchyma was normal.

MRI Brain screening showed similar results with normal whole spine screening. Airway management and proper feeding was important to the management to this neonate.

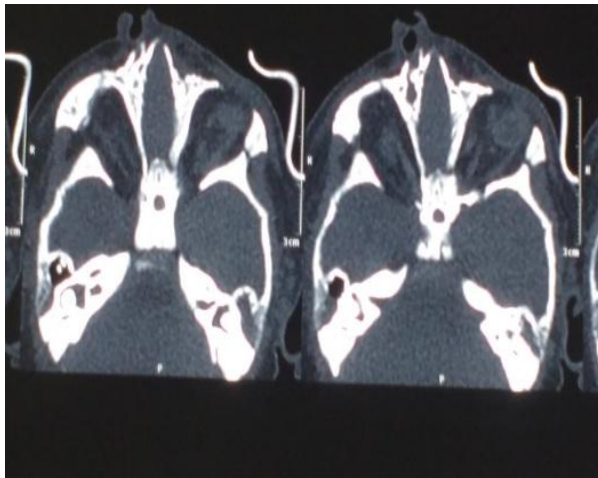


Figure 3 = CT scan images

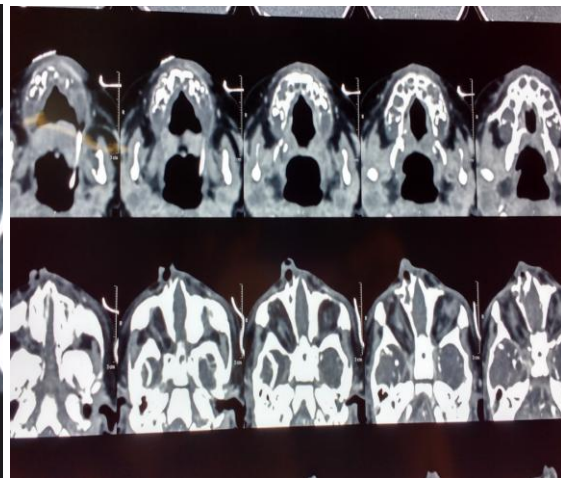


Figure 4 = MRI images

## DISCUSSION

The crucial development of major areas of facial region occurs between fourth and eighth embryonic weeks preceded by wavelike migrations of cranial neural crest cells from the region of trigeminal nerves to the face. The development of nose and nasal cavities occur between 3<sup>rd</sup> and 10<sup>th</sup> week of life. (20) At 24<sup>th</sup> days of life, the face is divided into a superior frontal process, paired bilateral maxillary processes in the mid-face and paired bilateral mandibular processes caudally respectively. (21) The

nasal alae are formed by the complete fusion of the nasal lateral and medial processes. The medial nasal processes attach in the midline with frontal prominence which results in the formation of frontonasal process which results in the origin to the nasal bones, columella, philtrum, upper lip and superior alveolar ridge. The nasal placodes are the local bulgings of surface ectoderm. The nasal placodes form the frontal process between the lateral and medial processes during 4<sup>th</sup> week of gestation. It invaginates to form pits of nasal

cavity during 5<sup>th</sup> week of gestation which later gives rise to nostrils. By 9<sup>th</sup> week of life, the cartilaginous nasal septum, which results from persistence of neural crest cells between the nasal cavities, directly overlies buccal cavity. The palatal shelves of the maxillae migrate medially as the septum migrates inferiorly. The posterior nasal cavities are separated from buccal cavity by the bucconasal membrane that ruptures forming communication between nasal and buccal cavities which occurs at 10<sup>th</sup> week. The primary posterior choanae formed as the nasal cavities canalize are filled by epithelial plugs which eventually resort to form the secondary posterior choanae and establish the potency of nasal cavities.

The pathogenesis of this malformation has not been fully understood. It is postulated that lack of development of the nasal apparatus results from medial failure and lateral nasal process growth. But there may be a possibility of overgrowth and premature fusion of the nasal medial process result in the formation of the atretic plate. (17) Many genes involved in facial development however, no consistent gene mutations have been identified, hence genetic testing is not yet available. The chromosomal analysis in the patients with congenital arhinia show normal results. (10) Our case had mos46,XX/47,XX,+9 on chromosomal analysis.

## CONCLUSION

Congenital arhinia is a rare birth defect of organogenesis, associated often with other anomalies which significantly influence the immediate and long-term outcomes of the neonate. It is a potentially life-threatening condition and requires the presence of a highly skilled neonatal resuscitation team at the time of delivery. Multidisciplinary team approach is required to optimize neonatal outcome.

## REFERENCES

1. Blair VP, Brown JB: Nasal abnormalities, fancied and real. *Surg Gynecol Obstet*, 1931; (53): 796–819

2. Gifford GJ, Swanson L, MacCollum DW: Congenital absence of the nose and anterior nasopharynx. Report of two cases. *Plast Reconstr Surg*, 1972; 50(1): 5–12
3. Lutolf U: Bilateral aplasia of the nose: a case report. *J Maxillofac Surg*, 1976; 4(4): 245–49
4. Muhlbauer W, Schmidt A, Fairley J: Simultaneous construction of an internal and external nose in an infant with arhinia. *Plast Reconstr Surg*, 1993; 91(4): 720–25
5. Galetti R, Dallari S, Bruzzi M et al: [Considerations concerning respiratory physiopathology in a case of total arhinia]. *Acta Otorhinolaryngol Ital*, 1994; 14(1): 63–69 [in Italian]
6. LaTrenta GS, Choi HW, Ward RF et al: Complete nasal agenesis with bilateral microphthalmia and unilateral duplication of the thumb. *Plast Reconstr Surg*, 1995; 95(6): 1101–4
7. Cusick W, Sullivan CA, Rojas B et al: Prenatal diagnosis of total arhinia. *Ultrasound Obstet Gynecol*, 2000; 15(3): 259–61
8. Olsen ØE, Gjelland K, Reigstad H, Rosendahl K: Congenital absence of the nose: a case report and literature review. *Pediatr Radiol*, 2001; 31(4): 225–32
9. McGlone L: Congenital arhinia. *J Paediatr Child Health*, 2003; 39(6): 474–76
10. Feledy JA, Goodman CM, Taylor T et al: Vertical facial distraction in the treatment of arhinia. *Plast Reconstr Surg*, 2004; 113(7): 2061–66
11. Hou JW: Congenital arhinia with *de novo* reciprocal translocation, t(3;12)(q13.2;p11.2). *Am J Med Genet A*, 2004; 130A(2): 200–3
12. Cho CH, Shakibaei M, Merker HJ, Klein M: [The rare malformation of nasal aplasia]. *Mund Kiefer Gesichtschir*, 2006; 10(2): 106–17
13. Graham JJ, Lee J: Bosma arhinia microphthalmia syndrome. *Am J Med Genet A*, 2006; 140(2): 189–93
14. Akkuzu G, Akkuzu B, Aydin E et al: Congenital partial arhinia: a case report. *J Med Case Rep*, 2007; 1: 97
15. Goyal A, Agrawal V, Raina VK, Sharma D: Congenital arhinia: A rare

- case. *J Indian Assoc Pediatr Surg*, 2008; 13(4): 153–54
16. Meng LJ, Huang ZL, Niu L: [Congenital arhinia: one case report]. *Zhonghua Er Bi Yan Hou Tou Jing Wai Ke Za Zhi*, 2009; 44(4): 343–44
17. Thornburg LL, Christensen N, Laroia N, Pressman EK: Prenatal diagnosis of total arhinia associated with normal chromosomal analysis: a case report. *J Reprod Med*, 2009; 54(9): 579–82
18. Fakhraee SH, Nariman S Taghipour R: Congenital arhinia: case report of a rare congenital anomaly. *Arch Iran Med*, 2011; 14(5): 355–56
19. Brusati R, Colletti G: The role of maxillary osteotomy in the treatment of arhinia. *J Oral Maxillofac Surg*, 2012; 70(5): e361–68
20. Nishimura Y: Embryological study of nasal cavity development in human embryos with reference to congenital nostril atresia. *Acta Anat (Basel)*, 1993; 147(3): 140–44
21. Lee KJ: Embryology of clefts and pouches. In: *Essential Otolaryngology Head and Neck Surgery*. Lee KJ, Lee KJ (eds.), Medical Examination Publishing: New York. 1991; 304–6

How to cite this article: Meshram H, Bhadane P. Congenital arhinia - a rare case report. *Int J Health Sci Res*. 2018; 8(5):402-405.

\*\*\*\*\*