

Original Research Article

Wound Healing with Collagen Sheet in Chronic Ulcers

Datta Prasad. M¹, B. Ananda Rama Rao²

¹Resident in Surgery, SVS Medical College, Maghabubnagar TS 509002

²Professor of Surgery, SVS Medical College, Maghabubnagar TS 509002

Corresponding Author: B. Ananda Rama Rao

ABSTRACT

Collagen Sponge sheet has unique properties like enhanced wound healing through neovascularization, anti adhesive effects, bacteriostatic, without inducing immunological reactions. There are no studies to quantify neovascularization with any agent applied to chronic non healing ulcers. This study is done to evaluate effects of healing in chronic ulcers as evidenced by quantum of neovascularization by collagen sheet application for a period of eight weeks in 15 patients with collagen sheet. Collagen sheet is commercially available. Patients are evaluated at first, second, fourth, sixth and eighth week. In the first two weeks there is faster rate of neovascularization as seen by counting the number of capillaries in an average of five high power fields (p-value <0.0001), later on there is congestion of vessels with formation of granulation tissue which peaks at fourth week (p-<0.0001), leading to reduction in ulcer size. There is significant reduction in ulcer size (p- 0.000) with collagen sheet. The cost effectiveness, readily availability, ease of application makes collagen sheet a better choice for treating chronic ulcers.

Key Words: Collagen Sheet, Chronic Non Healing Ulcer, Neovascularization, Wound Healing, Biological Dressings, Ulcer Biopsy

INTRODUCTION

Healing of an ulcer is a complex biological process, which needs interactions among different cell types along with growth of new blood vessels into the wound (neovascularization/angiogenesis), to promote adequate delivery of nutrients and regulatory factors required for tissue remodeling and regeneration. Chronic foot ulcers are defined as a slow or non-healing breakdown of epidermal and dermal tissue on the foot that duration of ulcer more than six weeks. Most of them are associated with venous disease, peripheral arterial disease, mixed arterio-venous disease and diabetes. In diabetes patients ulcers are caused by a variety of factors, in particular peripheral vascular disease and loss of sensation because of peripheral neuropathy ^[1] Further more chronic foot ulceration is a serious

morbidity leading to eventual limb loss. In diabetes, effective treatment of ulceration is key to the reduction in the number of amputations, as highlighted in the St Vincent Declaration. ^[2]

In chronic wounds, there is disruption of normal healing process due to either poor general health or local factors like inadequate blood supply to the wound. Healing of chronic leg ulcers constitute major clinical challenge not only because of high prevalence, refractory nature, impact on quality of life of patients, but also their economic consequences on health care system.

In this study neovascularization with collagen sheet studied. The minimum no. of capillaries seen per high power field evaluated with serial measurement from day 0 to 8th week. At day0 the range of

minimum no. of capillaries per high power field is 2 to 8 with mean 5.40. As the collagen sheet applied to the ulcer and capillary count measured till 8th week. At the end of 8th week the range of minimum no. of capillaries is 16 to 20 with mean 18.27. There is significant increase in number if capillary count as the treatment given 0 to 8 weeks. The p value is <0.0001.

Collagen plays a relevant role in cutaneous tissue repair and represents a valid therapeutic option when used as a bioactive advanced dressing in chronic wound management. It improves fibroblast deposition in the dermal matrix and stimulates angiogenesis, granulation tissue formation, and reepithelialisation. Fibroblasts mainly participate in the biosynthesis of collagen, which acts as a mould, precursor, plastic material, and cementing substance in the wound healing process. Biological dressings like collagen create the most physiological interface between the wound surface and environment, and are impermeable to bacteria. [3] Collagen dressings have other advantages like ease of application and being natural, non-immunogenic, non-pyrogenic, hypo-allergenic, and pain-free. [4,5]

The collagen sheet application enhanced wound healing by increasing the number of capillaries in the wound which ultimately forms the basis of matrix formation and subsequent wound healing. Rapid neovascularization is seen in first two weeks of application, followed by slow increase in number of capillaries with congestion around newly formed blood vessels and matrix formation. Collagen is commercially available and ease of application makes it more versatile and acceptable dressings for chronic non healing ulcers.

AIMS AND OBJECTIVES:

To study and quantify the increase in new blood vessel formation (neovascularization) and wound healing after application of collagen sponge sheet to chronic non-healing ulcers in a period of eight weeks.

MATERIALS AND METHODS

STUDY DESIGN:

This comparative, Prospective study was done in the Department of General Surgery, SVS Medical College and Hospital, Mahbubnagar; on 15 patients with chronic non-healing ulcers in lower limbs. Fifteen patients were applied with collagen sheet on chronic ulcer.

INCLUSION CRITERIA:

1. Patients between 30 to 60yrs of both sexes.
2. Chronic non healing ulcers on lower limb due to diabetes, varicose veins, and of non-malignant aetiology
3. Ulcers of size 4*4cms or more (i.e. equal to or more than 16cm² surface area of the ulcer) with no tendency of healing in past two months despite conventional treatment.

EXCLUSION CRITERIA:

1. Age of patient <30yrs and >60yrs
2. Patients with deep vein thrombosis
3. Significant arterial insufficiency
4. Severe neuropathy
5. Severe systemic disease
6. Renal insufficiency
7. Malignant ulcers
8. Parasitic ulcers

METHOD:

- Informed consent is taken from the patients.
- Detailed history of the patient with chronic non healing ulcer of the leg is taken.
- Debridement of ulcer is done to remove necrotic slough.
- The initial ulcer size is measured at its maximum diameters by using 0.5*0.5cm graph printed over transparent sheath up to one decimal in centimetres.
- Initial biopsy of 0.5cm is taken from floor of ulcer and sent for histopathology in 2% formalin solution. Routine histopathology of the specimen is carried out and under 40x magnification, the number of blood vessels present per field is counted at four corners of the field and centre; and average of five fields is taken.

- Collagen is packed in neutral glass vials containing sterile preservative liquid medium sterilized by Ethylene oxide and available in various sizes. Expose denuded area thoroughly cleaned. Selected right dimension collagen sheet is washed thoroughly in sterile normal saline. Apply local collagen sheet firmly on raw area with no air bubble in between.

RESULTS

STATISTICAL ANALYSIS:

Data was analyzed by Graph Pad Prism software version 6.01. Data was summarized by Mean \pm SD for continuous data. The comparison of capillary count and ulcer size between collagen sheath and amniotic membrane application on chronic non healing ulcers. For different time points was done by analysis of two way repeated measures test and followed by post-hoc multiple comparison tests. The comparison between different time points for the parameters no. of capillaries and ulcer size in the group's collagen sheath and amniotic membrane was done by analysis of one way repeated measures test and followed by post-hoc multiple comparison tests. All p values <0.05 were considered as statistically significant.

In this study neovascularization with collagen sheet studied. The minimum no. of capillaries seen per high power field evaluated with serial measurement from day 0 to 8th week. At day0 the range of minimum no. of capillaries per high power

field is 2 to 8 with mean 5.40. As the collagen sheet applied to the ulcer and capillary count measured till 8th week. At the end of 8th week the range of minimum no. of capillaries is 16 to 20 with mean 18.27. There is significant increase in number if capillary count as the treatment given 0 to 8 weeks. The p value is <0.0001 .

At the beginning of the study the number of capillaries in a high power field was very less (seven capillaries/hpf). After membrane application over ulcer, a hike in number of capillaries (12 to 16 capillaries/hpf) was noted in all the patients in the first two weeks of application. Later on, the rate of increase continued up to fourth week (20 capillaries/hpf). Beyond fourth week there was minimal increase in capillaries or almost static (more than 20). The increase in number of capillaries with time was found to be statistically significant (p-value=0.000). At the day 0 the mean of maximum number of capillaries is 10.67. At the end of 8th week the mean of number capillaries is 19.73. There is significant increase in number of capillaries at a given point of time when compared to previous week with p value <0.0001 . After application of collagen sheet, at the day 0 the mean ulcer size is 32.40 \pm 17.45 cm. At the end of 8th week the mean of ulcer size is 11.73 \pm 10.69cm. There is significant decrease in ulcer size at a given point of time when compared to previous week with p value <0.0001 .

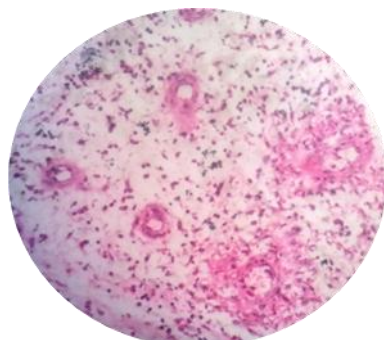


Fig-1. Day0 4-6 capillaries/hpf

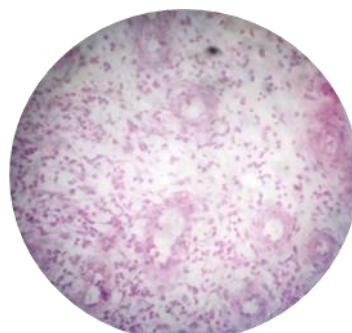


Fig-2. 1st week 8-10 capillaries/hpf

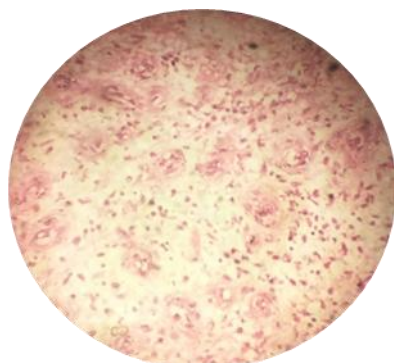


Fig-3.2nd week 10-12 capillaries/hpf

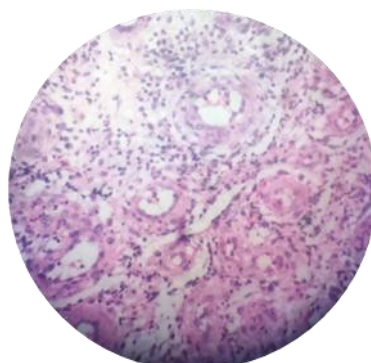


Fig-4. 4th week 12-15 capillaries/hpf & congestion with Stroma formation

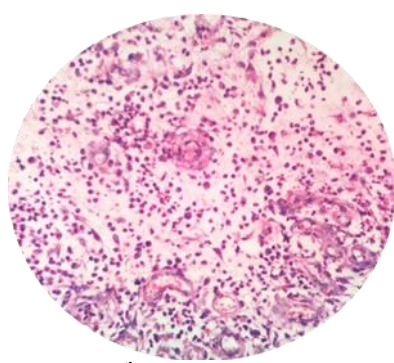


Fig-5.6th week.16-18capillaries/hpf with Increase in stroma

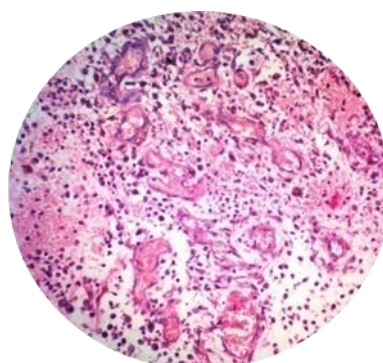
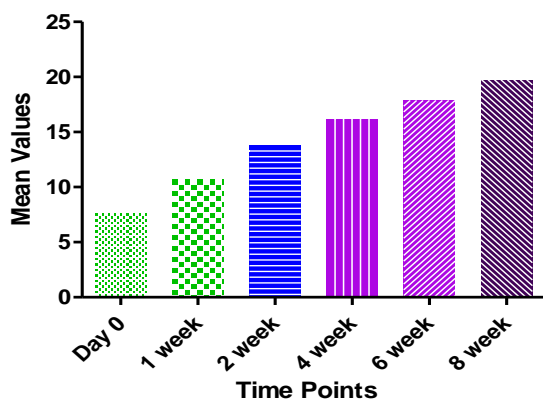


Fig-6.8th week 18-20 capillaries/hpf. with high stroma



Graph-1. No of capillaries vs time in weeks

Table-1.Capillary count progression in ulcer with application of collagen sheet

| Time | N | Range | Mean | SD | P-value |
|--------|----|----------|-------|-------|---------|
| Day 0 | 15 | 15 to 70 | 32.40 | 17.45 | <0.0001 |
| 1 week | 15 | 15 to 70 | 30.80 | 17.01 | |
| 2 week | 15 | 10 to 60 | 25.70 | 14.67 | |
| 4 week | 15 | 4 to 49 | 20.27 | 12.48 | |
| 6 week | 15 | 2 to 42 | 16.00 | 11.09 | |
| 8 week | 15 | 1 to 40 | 11.73 | 10.69 | |

Table-2Ulcersize progression with application of collagen sheet.

| Time | N | Range | Mean | SD | P-value |
|--------|----|----------|-------|--------|---------|
| Day 0 | 15 | 4 to 10 | 7.6 | 1.765 | <0.0001 |
| 1 week | 15 | 7 to 14 | 10.67 | 1.915 | |
| 2 week | 15 | 10 to 16 | 13.80 | 1.781 | |
| 4 week | 15 | 14 to 18 | 16.20 | 1.474 | |
| 6 week | 15 | 16 to 20 | 17.87 | 1.407 | |
| 8 week | 15 | 18 to 20 | 19.73 | 0.7037 | |

DISCUSSION

A wound is break in the integrity of the skin or the tissues often, which may be associated with disruption of structure or function. An ulcer is a type of wound with break in continuity of covering epithelium either skin or mucous membrane, due to molecular death. Wound healing is a complex method to achieve anatomical and functional integrity of disrupted tissue by various components, in an organised staged pathway. It is divided into 3 phases namely inflammatory, proliferative and maturational. [1]

The process of formation of new blood vessels called angiogenesis is very essential for wound healing. It begins with mechanical and chemical stimulation. [1] Increased muscle contraction leads to release of nitric oxide causing vasodilatation. Chemical stimulators being angiogenic proteins (angiopoietin), angiogenic growth factors like FGF 1, FGF 2, and VEGF etc activate receptors on endothelial cells in pre existing blood vessel, which release proteases that degrade the basement membrane thereby the

endothelial cells escape from parent vessel. These cells proliferate in the matrix forming sprouts then loops and become full fledged vessel lumen and get connected to neighbouring vessel. Angiogenesis inhibitor can be endogenous like delta like ligand 4(Dll4) or come from outside. [2]

The epithelium forms the physical barrier to prevent fluid loss and bacterial invasion. Epithelialisation includes sequence of events in the keratinocytes located in the basal layer – detachment, migration, proliferation, differentiation and stratification. Epidermal cells interact with extracellular matrix proteins like fibronectin through integrin receptors. Local release of EGF, KGF etc stimulate this process. Once the wound is bridged, the flattened cells become columnar and stratified. Later on, the surface layer keratinises.

Material used is collagen in sheet form produced from Bovine sources composed mostly Type 1 and Type 3 collagen. Collagen is packed in Neutral glass vials containing sterile preservative liquid medium sterilized by Ethylene oxide and available in various sizes. Collagen plays a relevant role in cutaneous tissue repair and represents a valid therapeutic option when used as a bioactive advanced dressing in chronic wound management. It improves fibroblast deposition in the dermal matrix and stimulates angiogenesis, granulation tissue formation, and reepithelialisation. [3] Fibroblasts mainly participate in the biosynthesis of collagen, which acts as a mould, precursor, plastic material, and cementing substance in the wound healing process. It would appear that aside from acting as a mechanical support and agent of fibroblast motility, heterologous collagen participates as a feeding substrate to the metabolic activity of the granulation tissue. The product acts locally without absorption and does not enter into the systemic structures of the body. Rather, it enters the fibroblastic cellular local metabolism, where it acts by stimulating the production of endogenous

collagen, which is responsible for wound healing.

The wound healing process involves phenomena such as proliferation, migration, and cell differentiation-all of which are influenced by the presence of collagen. In the final stage of repair with a continuity tissue solution, the maturation of collagen takes place and collagen fibers create a bridge between the edges of the damaged tissues, going on to form or favor a scar with elasticity and mechanical strength. [4,5]

The present study is a Prospective study done in SVS Medical College and Hospital, Mahbubnagar on 15 patients with chronic ulcers from November 2015 to November 2016. The patients are selected randomly following the inclusion and exclusion criteria. The various ulcers in this study are of diabetic, post infective, venous, traumatic, post burn etiologies.

ULCER SIZE: After application of collagen sheet, at the day 0 the mean ulcer size is 32.40+/-17.45 cm. At the end of 8th week the mean of ulcer size is 11.73+/-10.69cm. There is significant decrease in ulcer size at a given point of time when compared to previous week with p value <0.0001.

Di Mauro found that lyophilized type I collagen (LC) significantly improves wound healing in the treatment of diabetic ulcers. The mean time for wound healing in the group treated with LC was 32.4 +/- 8.6 days, and in the group treated with hyaluronic acid medicated gauze was 49.0 +/- 11.0 days (p < 0.001). [6]

Though, the role of collagen in promoting wound healing is well established, but it has not previously been tried extensively in the management of leg ulcers. The results of the present study are, therefore, encouraging. In addition, collagen dressing, unlike conventional dressing, is absorbed and does not have to be re-applied frequently. However, the ulcer should be debrided and cleaned before application. If there is evidence of infection, appropriate antibiotics should be administered.

Donaghue compared the efficacy of a collagen-alginate topical wound dressing with that of regular gauze moistened with normal saline in 75 patients diabetic foot ulcers. The mean percent reduction of the wound area was 80.6% in the collagen-alginate dressing group and 61.1% in the gauze-dressing group. Complete healing was achieved in 48% of the collagen-alginate dressing group and 36% of the gauze-dressing group. [7]

In a study by Vevesin 276 patients with diabetic foot ulcer, after 12 weeks of treatment, 51 (37.0%) Promogran'-a collagen/oxidized regenerated cellulose dressing-treated patients had complete wound closure as compared to 39 (28.3%) patients of control group (moistened gauze), but this difference was not statistically significant ($P=0.12$). In this study, author found an overall benefit of collagen on the rate of wound healing compared with moistened gauze.

In this study neovascularization with collagen sheet studied. The minimum no. of capillaries seen per high power field evaluated with serial measurement from day 0 to 8th week. At day0 the range of minimum no. of capillaries per high power field is 2 to 8 with mean 5.40. As the collagen sheet applied to the ulcer and capillary count measured till 8th week. At the end of 8th week the range of minimum no. of capillaries is 16 to 20 with mean 18.27. There is significant increase in number if capillary count as the treatment given 0 to 8 weeks. The p value is <0.0001 .

R Krishnan studied role of collagen sheet as a temporary cover for raw area on dogs and concluded that it prevents exogenous infections, promotes rapid epithelization, frequent dressing is not required, lesser time to heal as compared to other conventional dressing. [8] Jeschke G concluded that collagen matrix accelerates epidermal regeneration and locally increases growth factor concentration. [9] Snap L et al studied chronic ulcer with collagen sheet to conclude that it encourages early healing with uniformity in granulation. [10]

Chengcan Yao et al, found that wound healing was enhanced in traumatic ulcers with application of absorbable collagen sponge. [11] P Halankar found that there was hematoma beneath the collagen dressing but there was complete re-epithelization beneath the hematoma. [12]

CONCLUSION

The collagen sheet application enhanced wound healing by increasing the number of capillaries in the wound which ultimately forms the basis of matrix formation and subsequent wound healing. Rapid neovascularization is seen in first two weeks of application, followed by slow increase in number of capillaries with congestion around newly formed blood vessels and matrix formation. Collagen is commercially available and ease of application makes it more versatile and acceptable dressings for chronic non healing ulcers. This increase in blood vessels enhances formation of stroma and granulation tissue there by leading to reduction of wound size. Hence collagen sponge sheet is ideal choice in treating non healing ulcers.

REFERENCES

1. Pudner R, Wound management: The management of patients with a leg ulcer. *Journal of Community Nursing*, 1998. 12(3): 26–33.
2. Anon, The Saint Vincent Declaration on diabetes care and research in Europe. *Acta Diabetol*, 1989. 10(Suppl): 143–144.
3. Park SN, Lee HJ, Lee KH, Suh H. Biological characterization of EDC-crosslinked collagen-hyaluronic acid matrix in dermal tissue restoration. *Biomaterials*. 2003;24:1631–41..
4. Lazovic G, Colic M, Grubor M, Jovanovic M. The application of collagen sheet in open wound healing. *Ann Burns Fire Disasters*. 2005;18:151–6.
5. Horch RE, Stark GB. Comparison of the effect of a collagen dressing and polyurethane dressing on healing of split thickness skin graft donor sites. *Scand J PlastReconstSurg Hand Surg*. 1998;32:407–13.

6. Di Mauro et.al. Lyophilized collagen in the treatment of diabetic ulcers. Article *in* Drugs under experimental and clinical research 17(7):371-3. February 1991
7. Donaghue VM, Chrzan JS, Rosenblum BI, Giurini JM, Habershaw GM, Veves A. Evaluation of a collagen-alginate topical wound dressing in the management of diabetic foot ulcers. *Adv Wound Care.* 1998;11:114-119.
8. Krishnan R. Role of collagen sheet as temporary cover for raw area an experimental study. Published by Eucarepharma, Private Limited in Kollagen Monograph. *Ind J Plast Surg.* 14(1).
9. Marc G. Jeschke, Sandmann G, Schubert T, Klein D. Effect of oxidized regenerated cellulose/collagen matrix on dermal and epidermal healing and growth factors in an acute wound. *Wound Repair and Regeneration.* 2005;13(3): 324-331.
10. Snap L, Donahue K, Falanga V. Clinical classification of bioengineered skin use and its correlation with healing of diabetic and venous ulcers. *Dermatol Surg.* 2004; 30:1524-32.
11. Yao CYP, Wu H, Zha Z. Acceleration of wound healing in traumatic ulcers by absorbable collagen sponge containing recombinant basic fibroblast growth factor. *Biomed Materials.* 2006;1(1):33.
12. P Halankar, D Cunha-Gomes, C. Chaudhari. Collagen dressing in the management of donor site of split thickness skin grafts. *Bombay Hospital J.* 2005;47(2).

How to cite this article: Prasad MD, Rao BAR. Wound healing with collagen sheet in chronic ulcers. *Int J Health Sci Res.* 2018; 8(3):19-25.
