

*Case Report***Guiding Impacted Upper Incisor into Normal Alignment: A Case Report**Dr. Anwasha Adak<sup>1</sup>, Dr. Arpita Sarkar<sup>2</sup>, Dr. Subrata Saha<sup>3</sup>, Dr. Subir Sarkar<sup>4</sup>, Dr. Amit De<sup>5</sup>, Dr. Khushboo<sup>6</sup><sup>1</sup>Third year M.D.S. Student, <sup>2</sup>Second year M.D.S., <sup>3</sup>Professor, <sup>4</sup>Professor and HOD, <sup>6</sup>First year M.D.S. Student, Dept. of Pedodontics and Preventive Dentistry, Dr. R. Ahmed Dental College and Hospital, Kolkata.<sup>5</sup>Senior Lecturer, Dept. of Periodontics, Haldia Institute of Dental Sciences and Research, West Bengal.

Corresponding Author: Dr. Anwasha Adak

**ABSTRACT**

Tooth fails to erupt into normal arch position beyond its normal eruption period due to some local and systemic factors and this condition leads to impaction of that tooth. A 10 year old boy came with a complain of missing upper right central incisor. After clinical and radiographic examinations the condition was treated with surgical exposure of impacted tooth, followed by orthodontic traction and final alignment of incisor was done using 2x4 fix appliance therapy. Diagnosis of non-erupted upper anterior tooth and early treatment in mixed dentition period not only improve esthetics, speech, function but also improve psychosocial life of young child.

**Key words:** Impacted Incisor, Surgical Exposure, Orthodontic traction, Esthetic.

**INTRODUCTION**

The missing or unerupted upper incisors are the most concerning dental problems as it is easily noticed by parents and the children themselves in the mixed dentition period even though its incidence is very less. [1] A tooth is called impacted when there is retardation or halt in normal eruption process. Archer (1975) defined impacted tooth as one which is completely or partially unerupted and is positioned against another tooth or bone or soft tissue so that its further eruption is unlikely. [2] According to Kufinec and Shapira, [3] impaction is a condition in which a tooth is embedded in the alveolus so that its eruption is impeded and it is locked in position by bone or by adjacent teeth.

The maxillary incisor is designated as unerupted when there are - a) no history of prior extraction, b) eruption of contra-lateral incisor has occurred 6 months earlier or if both central incisors are unerupted and the lower incisors have erupted more than

one year before, or c) deviation from normal eruption sequence such as lateral incisors erupt before the central incisors. [4-6]

The etiology of impaction of permanent maxillary incisors are categorized into a) local, b) systemic and c) genetic factors such as- over retained or early loss of deciduous tooth, supernumerary teeth, tooth agenesis, tooth malformation or dilacerations, cysts or other pathological obstructions, dense mucoperiosteum or submucosa, arch length and tooth material discrepancy, endocrinal and nutritional disorders, certain syndromes etc. [7] Prevalence of impacted central incisor has been reported to be 0.06 to 0.2%. [8] The incidence of unerupted maxillary central incisor in the 5-12 year-old age group has been reported as 0.13%. [9]

**CASE REPORT**

A 10 year old boy reported to the department of Pedodontics and Preventive Dentistry of Dr. R. Ahmed Dental College

and Hospital, Kolkata with a chief complaint of missing upper right central incisor for last 2 yrs (Fig.1). There was no significant medical history. Clinical examination revealed orthognathic facial profile and presence of good facial balance in all proportions. An intraoral examination showed the child in mixed dentition stage

with erupted both upper and lower permanent incisors except upper right central incisor. On palpation a painless, hard, incompressible protuberance was felt in the labial sulcus at the mucogingival junction. Sufficient space was available for unerupted right permanent central incisor in the maxilla.

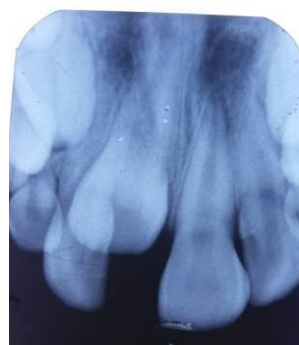
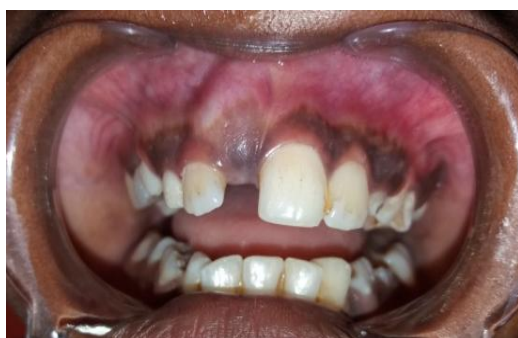

Fig.1: Intraoral view of the patient showing the unerupted maxillary permanent right central incisor.

Fig.2: Intraoral periapical radiograph showing impacted and distally inclined maxillary right central incisor.

The intraoral periapical radiograph (Fig.2) and oral pantomogram (Fig.3) showed that there was an ectopically placed upper right central incisor at the level of gingival 1/3 rd of root of upper right lateral incisor. There was a Class-I molar relationship .The overbite and overjet was within normal limits. The lower arch was mildly crowded.

#### **Treatment Plan:**

1. Surgical exposure of the impacted permanent upper right central incisor.
2. Orthodontic traction and fixed orthodontic treatment for proper alignment of the impacted incisor in the arch.

#### **Treatment Progress:**

In our present case surgical exposure of crown was done with closed eruption technique. Following this orthodontic traction and for proper alignment of impacted tooth 2x4 fix appliance therapy was used. Before surgical exposure brackets were bonded to the erupted left central incisor, right and left lateral incisors. Orthodontic bands with buccal tubes were

cemented onto the erupted upper permanent both first molars to gain sufficient anchorage. 0.019x0.025 inch stainless steel (SS) continuous archwire was placed. After surgical exposure, orthodontic button was bonded to the exposed labial surface of the impacted incisor (Fig.4). For the orthodontic directional tractional force 0.010 stainless steel ligature wire was ligated to the button. After full flap closure the other end of the ligature wire which was coming out of the flap was passively attached to the archwire (Fig.5). After healing of surgical area in about two weeks orthodontic traction force was initiated by tightening the ligature wire to the archwire (Fig.6). The tightening i.e extrusive force applied was 40gm at every 3 weeks interval. After the crown of the impacted incisor was sufficiently erupted out of the oral mucosa in about two months bracket was bonded to this tooth (Fig.7) and 0.012 Ni Ti arch wire placed followed by 0.014, 0.016 Ni Ti wire. Finally 17 x 25 SS wire were used for levelling of the teeth in the maxillary arch. This tooth alignment takes another 3 months.

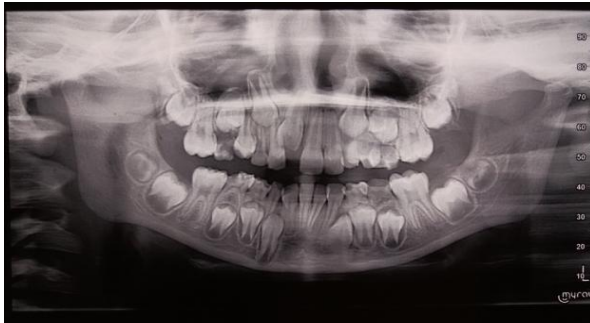

Fig.3: Panoramic radiograph showing ectopically present maxillary right central incisor.

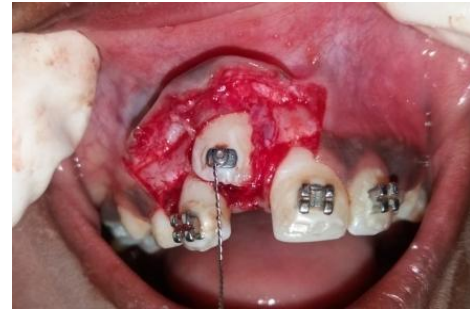

Fig.4: Surgical exposure of crown followed by bonding of orthodontic button and ligature wire.

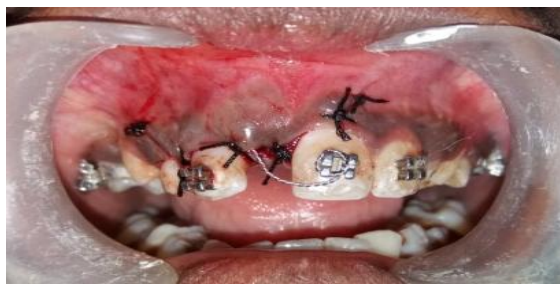

Fig.5: Full flap closure in its previous position and outer portion of ligature wire is kept passively.

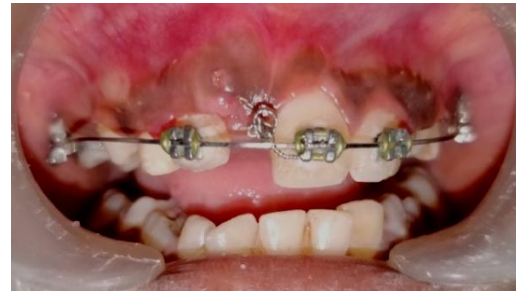

Fig.6: Initiation of extrusive force over impacted tooth by tightening the ligature wire.

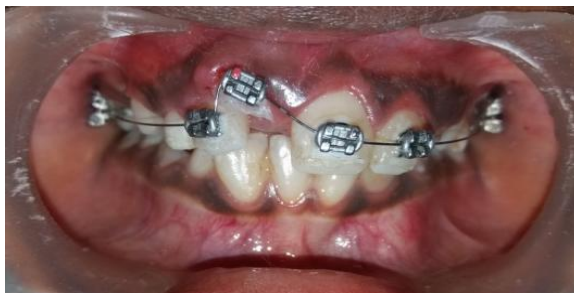

Fig.7: Bonding of bracket as the impacted tooth is visible followed by fix appliance therapy.

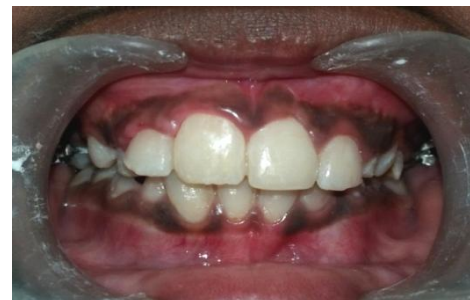

Fig.8: Maxillary central incisor is in normal alignment in the arch.

## RESULTS

The impacted maxillary right permanent central incisor was successfully positioned into proper alignment by closed eruption technique and orthodontic traction by fixed orthodontic therapy in about five months. After complete treatment the erupted incisor presented an acceptable gingival contour and attached gingiva (Fig.8). After removing the fixed appliance lingual bonded retainer was placed for post alignment stability and periodontal health.

## DISCUSSION

Impacted maxillary incisor occurs less frequently than the maxillary canine but it brings concerns to the parents in the early mixed dentition because the missing tooth

space causes unesthetic appearance. [10] There are several reports of successful treatment of impacted maxillary anterior teeth by proper crown exposure and orthodontic traction. Before treatment plan the following determining factors were considered for successful alignment of an impacted tooth are -a) The position and the direction of impacted tooth, b) The degree of root completion, c) The presence of space for the impacted tooth, d) presence of adequate width of attached gingival. [11,12]

In this case maxillary central incisor was impacted at the projection level of the gingival third of the contra-lateral completely erupted central maxillary incisor so it was treated by the surgical orthodontic approach, because spontaneous eruption

was not expected. Surgical exposure of crown can be performed in 3 accepted ways, [13] which include -a) Circular or window shaped excision of the oral mucosa that directly overlying the impacted tooth; b) Closed eruption technique in which the reflected flap that carries attached gingiva is fully replaced back in its previous position after an attachment has been bonded to the impacted tooth; c) Apically repositioning of the raised flap that includes the attached gingiva overlying the impacted tooth and expected to render adequate width of attached gingiva. Surgical exposure of crown was done in conservative way as it was a closed eruption technique where no gingiva or mucosa was removed. [14] As the tooth was present at the middle of the alveolus closed eruption technique was treatment of choice. Orthodontic button was bonded to the tooth as it is a miniature attachment it reduces the risk of fenestration. [15] After bonding and ligature wire placement flap was replaced into its original position. Controversy exists regarding the amount of time the clinician should wait to apply post surgical orthodontic forces after exposure and bonding. Some authors recommend application of force immediately after exposure. [16] Others recommend waiting for one [17] to two weeks. [18] This decision seems to be the individual preference of the clinician. Two weeks after surgical exposure, orthodontic traction was started. It has been reported that treatment of unerupted maxillary incisors with the closed-eruption technique simulates guided physiologic tooth eruption which can produce adequate attached gingiva and gingival contour with overall good long-term esthetic outcome. [19]

There might be some risk for adverse effects associated with this type of treatment which includes [20,21] a) Devitalization, loss of cervical bone; b) Periodontal disease if free mucosa left at cement-enamel junction of teeth; c) Pulp obliteration with opacity of clinical crown.; d) Increased crown length, uneven gingival

margins, gingival recession, less width of attached gingiva; e) Post alignment instability. So to avoid above mentioned conditions proper surgical techniques, controlled force and precise fixed orthodontic treatment and periodical review were accomplished and precautions were taken.

## CONCLUSION

The maxillary incisors and canines play a key role in an individual's smile for that reason they are often quoted as the 'social six'. A scant reports suggest any functional problems related to missing anterior teeth although some speech difficulties have been reported, especially with the 's' sound. As missing upper incisors are regarded as unappealing this may have an effect on self-confidence and general psychosocial interaction. Therefore, it is important to recognize the proper etiology of non-eruption and management of the problem as early as possible. Appropriate diagnosis and early interceptive orthodontic treatment is utmost important as it not only improve skeletal malrelationship but also eliminate functional interferences associated with disruption in eruption process.

## REFERENCES

1. Becker A. Early treatment of impacted maxillary incisors. *Am J Orthod Dentofacial Orthop.* 2002;121:586-7.
2. Archer WH. *Oral surgery.* 4th ed. Philadelphia: WB Saunders Co.1996.
3. Shapira Y, Kuftinec MM. The impacted maxillary canines: a review of concepts. *ASDC J Dent child.* 1995;63(5):317-324.
4. Scheiner MA, Sampson WJ. Supernumerary Teeth: A Review of the Literature and Four Case Reports. *Australian Dental Journal.* 1997; 42(3):160-165.
5. Ibricevic H, Al-Mesad S, Mustagrudic D, Al-Zoherjy. Supernumerary Teeth Causing Impaction of Permanent Maxillary Incisors: Consideration of Treatment. *J of Clin Paediatr Dent.* 2003; 27(4):327-332.
6. Yaqoob O, O'Neill J, Gregg T, Noar J, Cobourne M and Morris D. Management of Unerupted Maxillary Incisors. *Royal*

- College of Surgeons England Publication.* 2010.
7. Huber KL, Suri L, Taneja P. Eruption disturbances of the maxillary incisors: A literature review. *J Clin Pediatr Dent.* 2008; 32:221-30.
  8. Grover PS, Lorton L. The incidence of unerupted permanent teeth and related clinical cases. *Oral Surg Oral Med Oral Pathol.* 1985;59(4):420-425.
  9. Mac Phee, CG. The incidence of erupted supernumerary teeth in consecutive series of 4000 school children. *Br Dent J.* 1935; 58: 59–60
  10. Bishara SE. Impacted maxillary canines: a review. *Am J Orthod Dentofacial Orthop.* 1992; 159-71.
  11. Brin I, Zilberman Y, Azaz B. The unerupted maxillary central incisor: Review of its etiology and treatment. *ASDC J Dent Child.* 1982; 49:352-7.
  12. Tanaka E, Watanabe M, Nagaoka K, Yamaguchi K, Tanne K. Orthodontic traction of an impacted maxillary central incisor. *J ClinOrthod.* 2001; 35:375.
  13. Becker A. The orthodontic treatment of impacted teeth. Martin Dunitz: London. 1998.
  14. Vermette ME, Kokich VG, Kennedy DB. Uncovering labially impacted teeth apically positioned flap and closed eruption techniques. *Angle Orthod.* 1995;65:23-32.
  15. Noar JH, Gaukroger MJ. Customized metal coping for elastic traction of an ectopic maxillary central incisor. *J ClinOrthod.* 2000; 34: 585–89.
  16. Cunha RF, Boer FA, Torriani DD, Frossard WTG. Natal and neonatal teeth: review of the literature. *Pediatr Dent.*2001; 2: 23.
  17. Kokich VG, Mathews PG. Surgical and orthodontic management of impacted teeth. *Dent Clin North Am.*1993; 37: 181–204.
  18. Crawford LB. Impacted maxillary central incisor in mixed dentition treatment. *Am J Orthod Dentofac Orthop.*1997; 112: 1–7.
  19. Becker A, Brin I, Ben-Bassat Y, Zilberman Y, Chaushu S. Closed-eruption surgical technique for impacted maxillary incisors: Aporthodontic periodontal evaluation. *Am J Orthod Dentofac Orthop.*2002; 122: 9–14.
  20. Chaushu S, Brin I, Ben-Bassat Y, Zilberman Y, Becker A. Periodontal status following surgical-orthodontic alignment of impacted central incisors with an open-eruption technique. *Eur J Orthod.* 2003;25:579-84.
  21. Mostafa YA, Iskander KG, El-Mangoury NH. Iatrogenic pulpal reactions to orthodontic extrusion. *Am J Orthod Dentofacial Orthop.* 1991;99:33-3.

How to cite this article: Adak A, Sarkar A, Saha S et.al. Guiding impacted upper incisor into normal alignment: a case report. *Int J Health Sci Res.* 2018; 8(10):289-293.

\*\*\*\*\*