

Original Research Article

Histopathological Analysis of Superficial Lymph Adenopathy in Tertiary Care Hospital

Dr. Visalakshi P¹, Dr. Rajeswari P², Dr. Malliga S¹, Sivagangai²

¹Associate Professor, Department of Pathology, Govt Sivagangai Medical College,

²Associate Professor, IRT Perundurai Medical College, Perundurai,

Corresponding Author: Dr. Visalakshi P

ABSTRACT

Lymph node enlargement is very common clinical problem. It can occur in any age group and any site of the body. Detailed clinical history for signs and symptoms, size of lymph nodes, presence of generalized lymphadenopathy and hepatosplenomegaly help to arrive at provisional diagnosis. Various methods are available to examine the superficial lymph nodes like Fine needle aspiration Cytology, But Histopathological examination is a gold standard technique to evaluate the neoplastic and non neoplastic causes. Aim of this study is to statistically analyse the incidence of lymph node lesions in cervical region, axilla, and inguinal region in and around Madurai, Tamil Nadu.

Key words: superficial lymph adenopathy, histopathology, analysis.

INTRODUCTION

Lymph nodes are organized collections of lymph reticular tissue in the form of pink gray, kidney shaped, encapsulated organs. They are located at anatomically constant points along the course of lymphatic vessels. The common sites of distribution for clinical consideration are the cervical, axillary, supraclavicular and inguinal regions. [3]

The lymph node consists of lymphocyte aggregations, intermeshed with lymphatic sinuses supported by reticular fibre framework and surrounded by connective tissue capsule. The lymph node has cortex, para cortex, and medulla.

The lymph node enlargement is common outpatient complaint and it may be due to underlying systemic disease or regional disease. These can occur among all those people without age limit.

The normal immune response leads to proliferation and expansion of one or more of the cellular components of lymph

Nodes; it leads to significant lymph node enlargement. [4] Lymphadenopathy refers to nodes that are abnormal in size, consistency or number, caused by the invasion or propagation of either inflammatory cells or neoplastic cells into the nodes. Detailed clinical history of symptoms and signs, size of the lymph nodes, presence of generalized lymphadenopathy, hepatosplenomegaly help to arrive provisional diagnosis. Diagnostic lymph node biopsy is one of the frequent procedures in surgical practice. When node biopsy is indicated, selection of the most abnormal node will best enable the pathologist to determine a diagnosis. [5]

MATERIALS AND METHODS

This study was conducted in the Pathology Department, Madurai Medical College. The specimens were received from the Surgery Department, Government Rajaji Hospital, and Madurai. Clinical details

including age, sex, and anatomical site of node biopsy were obtained.

The biopsy specimens were fixed in 10% formalin. Gross morphological features such as size of nodes, shape, consistency, presence of necrosis and matting, presence of capsule were examined, after that 4-5 micron tick sections were made and stained with Haematoxylin and Eosin stain. Special stains such as Reticulin were used when required. Immuno his to chemistry was done in relevant cases.

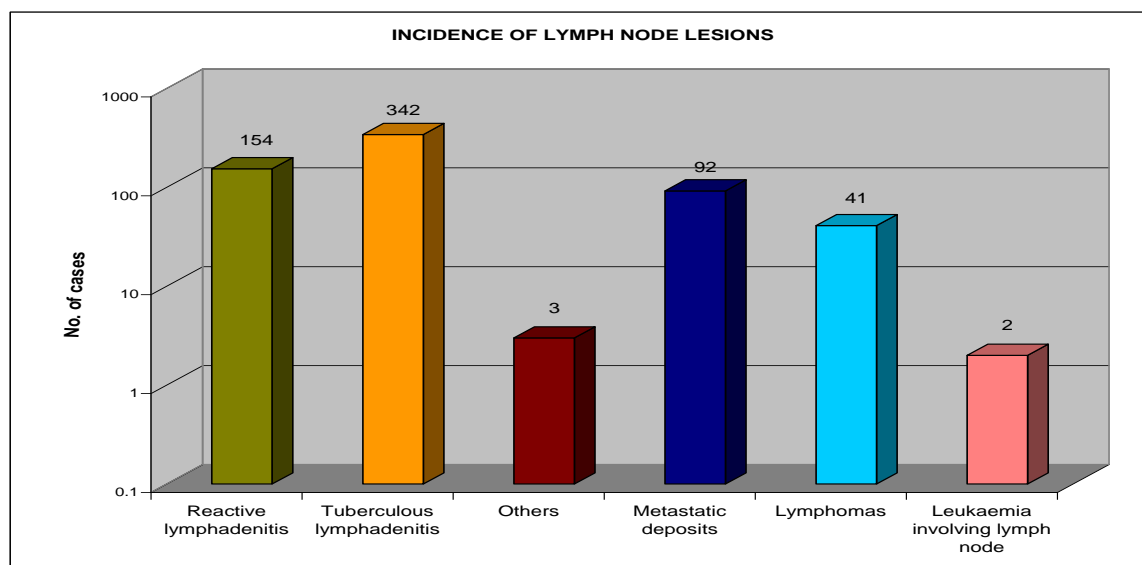
OBSERVATION AND RESULTS

In the two years study period 10,506 general biopsy materials were received from Government Rajaji Hospital, Madurai. Of these, Lymph node lesions accounted for 634 cases. Hence, the overall incidence of

lymph node lesion in this hospital was 6.03%

The total numbers of benign lymph node lesions were 499. Out of these, reactive lymphadenitis was 154 (24.3%) and tuberculous lymphadenitis was 342 (53.94%). Others were three in number (0.47%) (Kimura's disease-1, Dermatopathic Lymphadenitis-1 and Lepromatous Lymphadenitis-1). Thus over all incidence of benign lesion was 78.7%

Total numbers of malignant lesions were 135. Out of these, metastatic deposits were 92 (14.15%), Lymphomas were 41 (6.46%) and Leukemia involving the Lymph node was two (0.32%). Out of Lymphomas, Non Hodgkin's lymphoma was 18 and Hodgkin's lymphoma was 23. Hence, overall incidence of malignant lesion was 21.3% (Diagram 1 & 2)



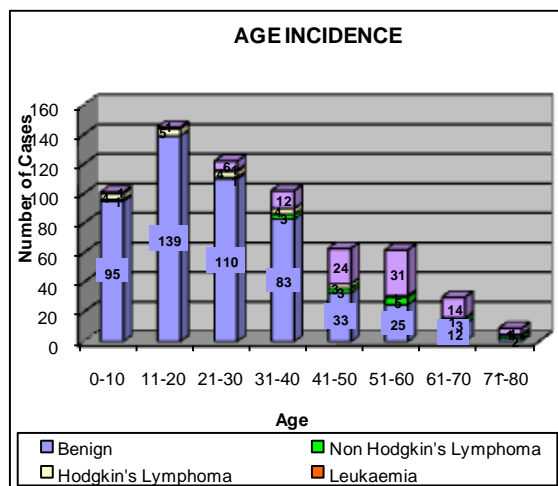
Details of lesions on Histopathological Examination of Lymph node

HP Diagnosis	Number of cases	Percentage (%)
Reactive Lymphadenitis	154	23.5%
Tuberculous Lymphadenitis	342	53.9%
Kimura' disease	1	0.15%
Dermatopathic Lymphadenitis	1	0.15%
Lepromatous Lymphadenitis	1	0.15%
Metastatic Deposits	92	14.15%
Non Hodgkin's Lymphoma	18	2.8%
Hodgkin's Lymphoma	23	3.6%
Leukemia involving the Lymph node	2	0.3%

Age incidence:

Benign lymph node lesions had peak age incidence in the second decade.

The age incidence of lymphomas ranges from 4 to 80 years. In that, Hodgkin's lymphoma occurs in young (from 4 years) as well as in the old age (up to 79). Non Hodgkin's lymphoma commonly occurs in patients with age group of 40 to 80years. Secondary carcinomatous deposit was commonly encountered in persons of 40 to 70 years.



The distribution of lymph node lesions according to age is shown in diagram 3.

Sex incidence:

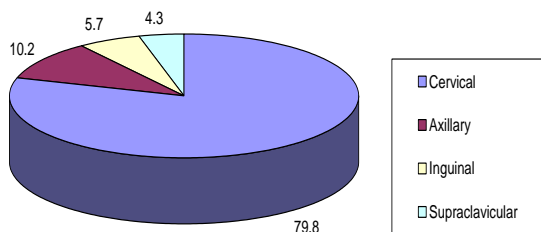
Out of the 499 benign lymph node lesions, 299 cases occurred in females (incidence 59.9%), 200 cases occurred in males (incidence 40.1%). Hence, male to female ratio in benign conditions were 1:1.5.

Out of 92 patients with secondary carcinomatous deposits, 33cases were females (35.9 %), 59 cases were males (64.1%) and out of 41 cases with lymphomas 12 cases were females (29.7%) 29 cases were males (70.3%)

Node Enlargement:

79.8 % of the patients had cervical node enlargement, 10.2% of patients had axillary node enlargement and only 5.7% of patients had inguinal lymphadenopathy, followed by supraclavicular node enlargement, which was only 4.3 %.

SITES OF NODE ENLARGEMENT (IN PERCENTAGE)



DISCUSSION

Even though Fine needle aspiration cytology of superficial lymph node is used to obtain the diagnosis, His to pathological diagnosis is the gold standard technique to diagnose superficial lymph node enlargement. [10,11]

Age Incidence:

In our study the age of the patients ranged between 3 and 70 years. (Diagram 2). The peak age incidence of non-neoplastic lymph node lesions were found to be in the second decade.

For metastatic lesions, the age ranged from 40 to 80 years, whereas lymphomas had bimodal peak at second and seventh decade.

Sex Incidence:

In the present study the male to female ratio was 1: 1.5

Site of Swelling:

Involvement of cervical lymph nodes were maximum (79.8 %) followed by axillary (10.2%), inguinal (5.7%), and supraclavicular node (4.3%) A similar incidence had been quoted by Kline et al (1984) [1] and Hema Arora (2001). [12]

Site of Swelling – A comparative study

Author (year)	Cervical	Axillary	Inguinal	Supra calvicular
Kline et al(1984) ⁵⁷	60.6%	28.2%	11.2%	-
Hema Arora(2001) ⁴⁶	75%	13%	6.15%	7.6%
Current study	79.8%	10.2%	5.7%	4.3%

Reactive Lymphadenitis:

Grossly the affected lymph nodes were enlarged and firm. His to pathologically reactive lymphadenitis showed follicular, sinus, or mixed patterns.

In follicular hyperplasia, histopathological examination showed marked enlargement and prominence of the germinal centers. (Fig 1)

Out of non-neoplastic lymph node lesions which formed 55.3%, the second most common diagnosis was reactive hyperplasia, which was second to the incidence of tuberculosis in the present study. This figure is correlating with the study of Bezabih M et al (2003) [2]

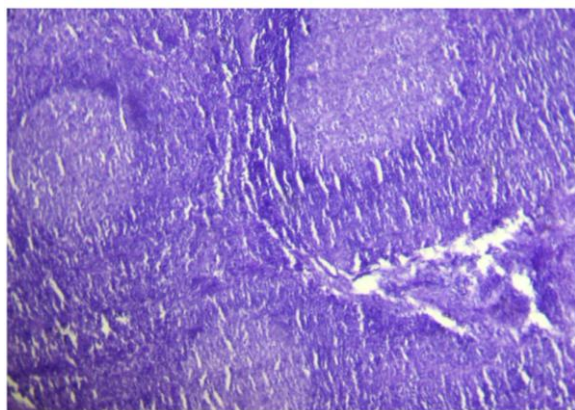


Fig 1. Reactive Lymphoid Hyperplasia- Follicular pattern showing enlarged Lymphoid follicles with prominent germinal centres. H &E X100

Tuberculous lymphadenitis:

Grossly the affected lymph nodes are matted and showed caseous necrosis. Histopathological examination of tuberculous lymphadenitis showed caseous necrosis, epithelioid cell granulomas and Langhans' giant cells. (Fig2)

Several studies showed that Tuberculosis is the predominant etiology of lymph node enlargement Khan et al [6] and Umer et al [7] studies showed the incidence of Tuberculosis were 33.3% and 55.4%. In our study the incidence of Tuberculosis was 53.94%. But the study of Oluwale et al [9] and Moore et al [8] showed the incidence of reactive hyperplasia was high. This might be due to variation in geography, immunological status of the patients and age of the patients.

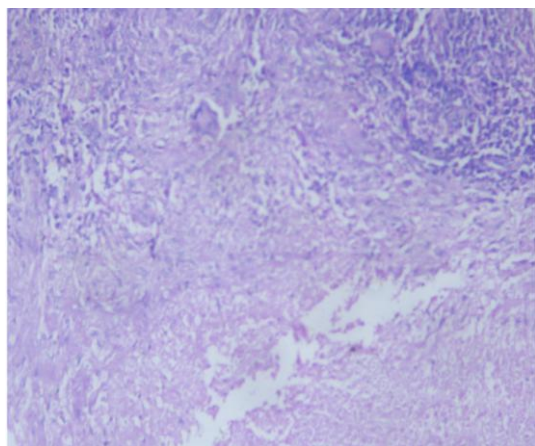


Fig 2. Tuberculous Lymphadenitis show caseous necrosis, epithelioid cell granulomas & Langhans giant cells. H & E X100

Lymphoma:

Non Hodgkin's Lymphoma

Grossly cut surface of enlarged lymph node showed gray white and fish flesh appearance.

Histopathological examination of Small Lymphocytic Lymphoma shows loss of architecture and replaced by diffuse proliferation of well differentiated, mature, small and uniform lymphocytes without cytologic atypia or significant mitoses. (Fig 5) Histopathologically Diffuse Large cell Lymphoma have diffuse pattern of involvement by large cells showing round to oval nucleus and two to three nucleoli, with increased mitotic activity.

In a case of Non Hodgkin's Lymphoma perinodal fatty infiltration was seen. (Fig3)

Reticulin stain in a case of Non Hodgkin's Lymphoma showed a fine, branching reticulin network with pericellular fibrils characterize the lymphoma. Peripheral smear showed atypical Lymphoid cells with clefting of the nucleus. Immuno histochemically three of Non Hodgkin's Lymphoma cases showed CD 20 positivity.

Hodgkin's Lymphoma:

Grossly the cut surface of Hodgkin's lymphoma showed nodular scarring in nodular sclerosis type whereas mixed cellularity type showed abundance of necrosis.

On microscopic examination of nodular sclerosis type of Hodgkin's lymphoma showed variable amount of fibrous tissue and characteristic lacunar type of RS cells. (Fig 4)

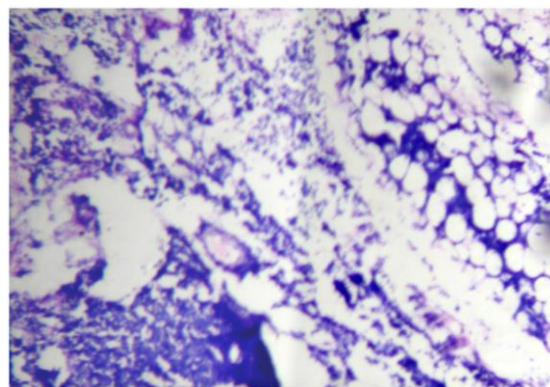


Fig 3. Non Hodgkins Lymphoma. Lymphoid cells are seen infiltrating the surrounding perinodal fatty tissue. H &E X1000

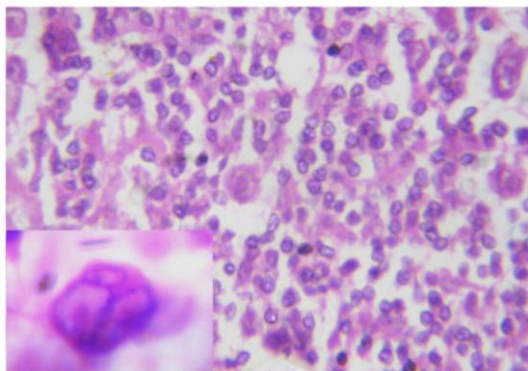


Fig 4. Hodgkins Lymphoma- Nodular sclerosis. Lacunar type of RS cells are seen in a fibroitic background. Insert show RS

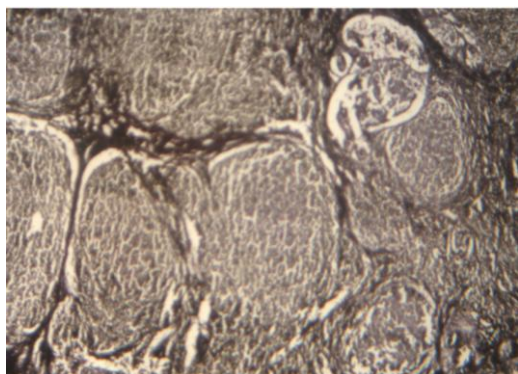


Fig5. Metastatic Squamous cell carcinoma shows thick reticulin fibres surrounding nests of tumour cells. Reticulin X100.

Immuno histochemical markers CD15 and CD 30 were positive in a case of Hodgkin's Lymphoma mixed cellularity type.

During the study period, one case was diagnosed histopathologically as reactive lymphadenitis. After six months, the same case was re-diagnosed as suggestive of Hodgkin's Lymphoma. Sometimes False negative results can be encountered due to small or inaccessible nodes, fibrosis, necrosis or sampling the wrong node.

Leukaemia Involving Lymph Node:

Histopathologically Acute Lymphoblastic Leukaemia involving the lymph node was appearing to begin at the center of the node residual lymph node structure was seen at the periphery.

Hence, in all cases of suspected lymphoma, details regarding haematological and smear findings and marrow features are essential for correlative study

METASTATIC DEPOSITS

Grossly metastatic deposits of malignant melanoma showed brownish melanin pigment deposits. Metastatic deposits of squamous cell carcinoma showed grayish white tumour areas.

Histopathologically, in malignant melanoma lymph node was partially replaced by melanoma cells showing marked pleomorphism and prominent melanin pigments.

Reticulin stain of squamous cell carcinoma showed thick reticulin fibres surrounding the cords and islands of carcinoma cells. (Fig6)

During the study period, metastatic squamous cell carcinoma was found in maximum number (41.3%) followed by adenocarcinoma (27.6%). This is correlating with the study of Hema arora et al. [12]

CONCLUSION

Our study concludes the incidence of superficial lymph adenopathy was 6.03%. The peak age incidence of non- neoplastic lymph node lesions was in the second decade. Hodgkin's lymphoma occurs in young (4 -30), and old age (45 -79). Non Hodgkin's lymphoma and metastatic deposits commonly occur in the old age. Common site of Lymph node enlargement was cervical group.

The most common Non neoplastic lesion in the present study was tuberculous lymphadenitis accounting 53.9% histopathologically. Among the malignant lesion, the incidence of metastatic deposits was high and accounting for 14.5% histopathologically the metastatic deposits, squamous cell carcinoma was the commonest one. Three out of 4 cases of Non Hodgkin's lymphoma had bone marrow involvement.

Even though various methods of investigations like Fine Needle Aspiration Cytology are available for diagnosing lymph node lesions, Histopathological Examination is simple, gold standard and confirmatory method to diagnose the enlarged lymph node

REFERENCES

1. Kline TS, Kannan V, Kline IK: Lymphadenopathy and Aspiration Biopsy Cytology: Review of 376 Superficial Nodes. *Cancer* 54: 1076-1081, 1984.
2. Bezabih M, Mariam DW: Determination of aetiology of superficial enlarged lymphnodes using fine needle aspiration cytology. *East Afr Med J*. Nov, 80 (11):559-63, 2003.
3. Stein H, Bonk A, Tolksdorf G, Lennert K, Rodt H, Gerdes J: Immunohistologic analysis of the organization of normal lymphoid tissue and non-Hodgkin's lymphomas. *J Histochem Cytochem* 1980; 28:746-760.
4. Longo, Fuci et al, *Harrison's Internal Medicine* 17th edition ch.-60 p 370-372.
5. Pangalis GA, Theodoros P. Clinical approach to lymphadenopathy. *Seminars in Oncology*, (Dec.) 1993; 20 (6):570-582.
6. Khan AU, Nawaz G, Khan AR, Raza. An audit of 75 cases of cervical lymphadenopathy. *J. Med. Sci.* 2011; 19: 95-97. [3] Longo, Fuci et al, *Harrison's Internal Medicine* 17th edition ch.-60 p 370-372.
7. Umer M F, Mehdi S H, Muttaqi A E, Hussain S A. Presentation and aetiological aspects of cervical lymphadenopathy at Jinnah Medical College Hospital Korangi, Karachi. *Pak J Surg* 2009; 25(4): 224-226.
8. Moore SW, Schneider JW, Schaaf HS. Diagnostic aspects of cervical lymphadenopathy in children in the developing world: A study of 1877 surgical specimens. *Pediatr Surg Int* 2003; 19:240-4.
9. Oluwale SF, Odesanmi WO, Kalidasa AM. Peripheral lymphadenopathy in Nigeria. *Acta Trop.* 1985; 42(1):87- 96.
10. Sibanda EN, Stanczuk G. Lymph node pathology in Zimbabwe: A review of 2194 specimens. *Q J Med* 1993; 86:811-7. 3.
11. Anjorin KA, Peripheral AS. Lymphadenopathy in Nigeria. *Afr J Med Med Sci* 2000; 29:233- 4.
12. Hema arora, P.V.Patil M.D: Role of fine needle aspiration cytology in superficial lymphadenopathy, District Hospital & KLES Hospital and Medical Research Centre, Belgaum

How to cite this article: Visalakshi P, Rajeswari P, Malliga S et al. Histopathological analysis of superficial lymph adenopathy in tertiary care hospital. *Int J Health Sci Res.* 2017; 7(8):72-77.
