

Case Report

Management of Open Apex Using MTA and Reinforcement of Weekend Root with Customized Fiber Post- a Case Report

Jahnavi. B¹, Dr. K. Sasidhar Reddy², Dr. S. Datta Prasad³, Bala Saraswathi. K¹

¹Post graduate, ²Professor, ³Professor & HOD,
Department of Conservative Dentistry and Endodontics, C. K. Stheja Institute of Dental Sciences and Research,
Tirupathi.

Corresponding Author: Jahnavi. B

ABSTRACT

Management of non-vital teeth with open apex is a challenge to dental practitioners. In this scenario, it is difficult to maintain the obturation material within the confines of root canal without encroaching into periapical area. Apexification aims to induce apical closure of the open root apex with hard tissue barrier, against which root filling can be compacted. Also, a thin dentinal wall of canal is matter of concern. Hence, the present case report present the use of MTA to form an apical plug in open apex followed by root canal obturation using thermoplasticized gutta-percha and reinforcement of weekend root with customized fiber post.

Key words: Dental trauma, Ellis class IV fracture, Open Apex, Custom Modified Fiber Post.

INTRODUCTION

The maxillary central incisors are the most common teeth affected during trauma. One of the aims of root canal treatment is to fill completely the root canal system in order to prevent re-infection. In teeth with incomplete root development as a consequence of pulp necrosis through trauma or caries, the absence of a natural constriction at the end of the root canal makes control of filling materials difficult (Seltzer 1988). Because of the lack of an apical constriction, an alternative to standard root canal treatment, apexification or root-end-closure, has been advocated (Seltzer 1988).^[1]

The general protocol for fractured, non-vital anterior teeth involves root canal treatment followed by protective permanent restorations for the coronal structure followed by review. Special situations arise in young patients when the pulps of anterior teeth lose vitality with resultant arrested

development of the roots. The open and sometimes divergent apical morphology and weak root dentine wall makes endodontic procedures challenging, and presents restorative problems. It is important to preserve these weakened teeth in young patients.^[2]

Mineral trioxide aggregate (MTA) has been shown to be a very effective root filling material for sealing immature root canals with open apices that could otherwise impose technical challenges in obtaining adequate obturation.^[3]

Therefore, present case report highlights the nonsurgical management of asymptomatic teeth with immature apices and large periapical radiolucencies using MTA and restoration of mutilated teeth using custom modified fiber post.

CASE REPORT

A 16 year old boy reported to the Department of Conservative dentistry and

Endodontics with fracture of right and left maxillary central incisors (Fig.1) History revealed that the patient had suffered trauma at the age of 8 years. On examination 11 and 21 had Ellis Class IV fracture with fracture of incisal one third involving the pulp chamber and was non-mobile. Radiographic

examination revealed an immature tooth with a wide open apex and a radiolucent area in proximity of the apex of the tooth (Fig.2). Thermal test, Electric pulp tests revealed abnormal response and non tender on percussion. The fracture involves the pulp chamber through the incisal edge.

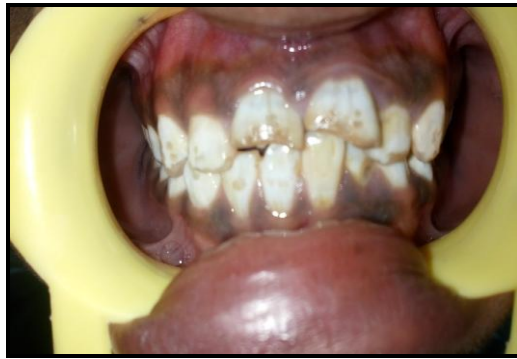

Fig. 1. Preoperative view

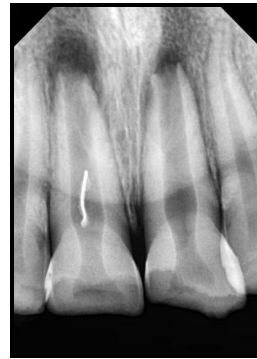

Fig. 2. Preoperative radiograph

Procedure:

After application of rubber dam, access cavity preparation was done and working length was determined and confirmed using periapical radiograph (Fig.3). At this stage, size 80 K-file (Mani) was loose within the canal and could easily pass beyond the apical limit of the canal. The canal was thoroughly cleaned using 80 K-file by circumferential filing and 3% sodium hypochlorite irrigation. To obtain

canal disinfection prior to MTA placement, canal was dried with paper points), calcium hydroxide was placed (Fig.4), and the access was closed with a sterile cotton pellet followed by a provisional restorative material IRM. The patient was then reappointed for continuation of treatment approximately 1 week from the initial appointment.

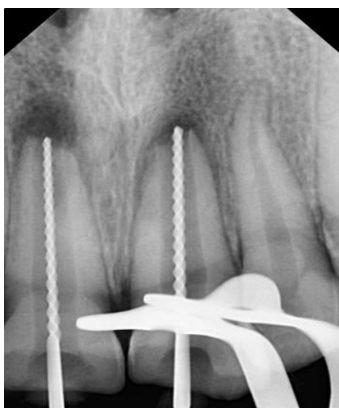

Fig. 3 Working length determination

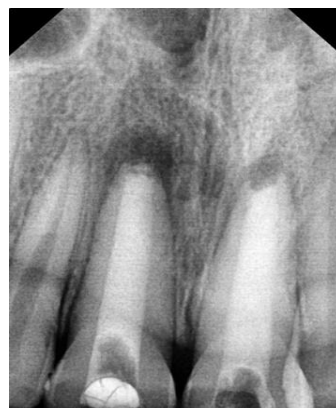

Fig. 4 Calcium Hydroxide dressing

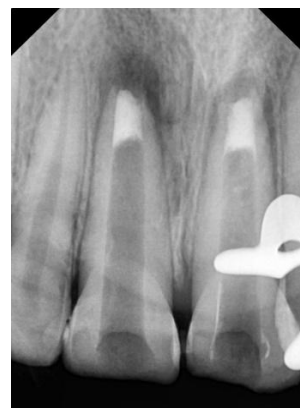

Fig. 5 MTA Plug of 4 mm

At the next appointment, rubber dam was placed as described above. The tooth was re-accessed, and calcium hydroxide was removed with 3% NaOCl irrigation and instrumentation. Before obturation, the canal was irrigated with 3% NaOCl and saline and the canal was then dried with

paper points. White ProRoot MTA (Maillfer, Dentsply, Switzerland) was then mixed with distilled water according to manufacturer's instructions and subsequently placed up to the apex with a fine-tipped MTA carrier (Fig.5). This procedure was repeated a number of times

until the thickness of MTA reached almost 3mm. The plug's position in canal was checked by radiographs. After application of MTA, a wet paper point was left within the canal for 24 hours, and temporary coronal seal was established with IRM.

The next day 3mm of obturation done with thermoplasticized technique by vertical condensation using ObturaII. (Fig.6). At the following appointment, restoration of tooth started with preparation of custom modified fiber post for Intra-radicular Rehabilitation of fractured anterior tooth. Peeso reamer no. three and four was used to prepare post space and to remove any undercut that may present on canal walls. The root canal was dried thoroughly. A translucent fiber post was selected (Maillefer, France) (Fig.7) and it was then etched with 37% phosphoric acid for 30 seconds (N-Etch; invoclarvivalent) and then washed dried with three-way syringe. Bonding agent (Tetric N-Bond; invoclarvivalent) was applied with micro tip brush and cured for 40 seconds on each side to facilitate the bonding between composite and fiber post material. Resin composite (Tetric N-Ceram; invoclarvivalent; Anano hybrid composite material), was then coated over the post and inserted into the canal adapting it precisely to replicate the canal anatomy (Fig.8). It was light cured intraorally for 5 seconds and subsequently was withdrawn and light cured extraorally for 20 seconds. This procedure continued in increments until the post had a snug fit inside the canal (Fig.9). The root canal walls were etched with 37% phosphoric acid for 15 seconds and then thoroughly rinsed with water and gently air-dried. Bonding agent (Adper Single Bond 2,3M ESPE, St. Paul, USA) was applied into the root canal with a microbrush applicator and cured for 20 seconds. Finally, custom modified fiber post was cemented with dual cure resin cement (Rely-X ARC, 3M ESPE, St. Paul, USA). Following this, the core (Fig.10) was prepared over the post and light curing was performed in order to completely polymerize the composite. A

final radiograph was taken to confirm the fit of post and core into the canal (Fig.11). Temporization was performed and the final zirconium crown was cemented after 1 week (Fig.10). The patient was recalled periodically over a follow up period of 12 months. A periapical radiographs demonstrated that custom modified fiber post and core remained well adapted to post space and the complete healing of periapical lesion (Figure 4D).

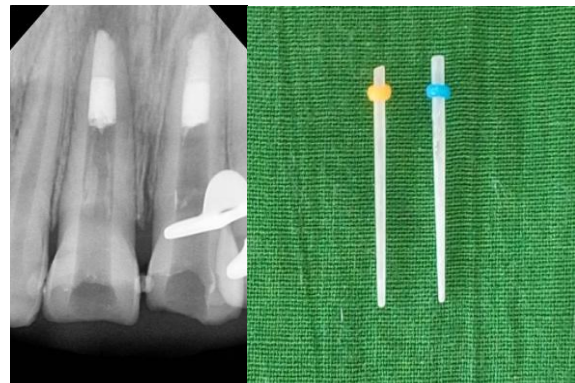


Fig.6 Thermoplasticized obturation

Fig.7 Fiber post

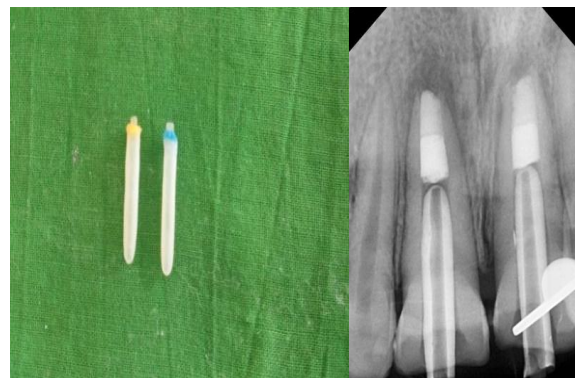

Fig.8 Modification of Fiber post with composite

Fig.9 Trail fitting of custom modified glass fiber post

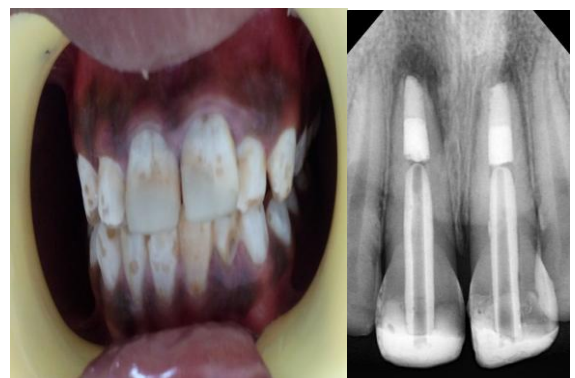

Fig.10 Clinical photograph of completed core restoration

Fig.11 Cementation of post with light cure GIC

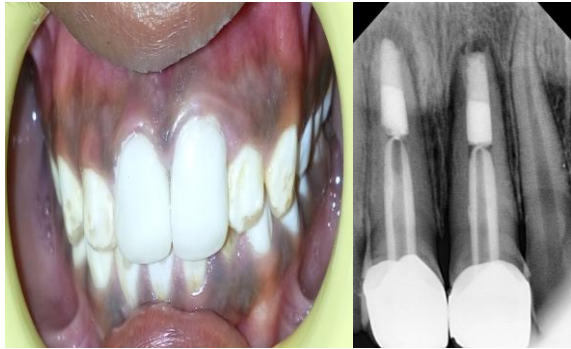

Fig.12 Cementation of Zirconium Crown

Fig.13 Radiograph after 12 months

DISCUSSION

The maxillary incisors are the most frequently injured teeth in the primary and permanent dentition. Teenage years cause a significant number of dental injuries as they engage in contact sports. [4] Ellis class IV fracture is defined as “the traumatized teeth that become nonvital with or without loss of crown structure.” The traumatic dental injury increases bacterial potential to invade dentinal tubules and therefore produce acute inflammation of pulp. [5]

In this case it has been not treated over a long period of time and its open cavity leads to increased demineralization of dentin. So that greater amount of infected soft dentin was removed during the cleaning and shaping of root canal.

The major problem in cases of a wide open apex is the need to limit the material, thus avoiding the extrusion of a large amount of material into the periodontal tissue. Using a matrix avoids the extrusion of the material into the periodontal tissues, reduces leakage in the sealing material and allows favorable response of the periodontal tissues. [6] Various materials have been used for formation of apical barrier during apexification. MTA obturation of open-apex teeth overwhelms the defects of conventional apexification procedures. In addition, MTA induces a constant formation of cementum with a high integrity and inclusive periradicular structure. Superiorly, MTA stimulates the periradicular/periodontal tissues repair. [7] Obturation was done with thermoplasticized gutta-percha, since it can be placed without

applying any compaction forces on thin dentinal walls in contrast to lateral condensation method. The root was very thinned for intra radicular rehabilitation through the cast post. So the present treatment was chosen as a choice because fiber post affords pleasant aesthetics and modulus of elasticity similar to that of dentin. [8]

To accommodate the remaining spaces around the post it was reinforced with composite material after the surface treatment of the post. The entire unit of post along with the luting cement will act as single unit to efficiently deliver forces to root. This will mimic the monoblock concept of adhesive obturation. Esthetic anatomic posts have advantages over the conventional cast metal posts; lower modulus of elasticity protects them from root fracture by reducing the forces that are transferred from the post to the root. A cast metal post would have a wedging effect resulting in root fracture. [7] The traditional custom-cast dowel core provides a better geometric adaptation to excessively flared or elliptical canals, and almost always requires minimum tooth structure removal. Custom cast post-and cores adapt well to canals with extremely tapered canals or those with a noncircular cross section and/or irregular shape, and roots with minimal remaining coronal tooth structure. This technique incorporates the advantages of both Fiber post and custom-made post. [9] Glass fiber posts were introduced as an aesthetic alternative; their use is based on the mechanical notion that materials restoring endodontically treated teeth should have similar mechanical properties with that of tooth substance. [10]

Several authors have stressed the use of fiber posts in such teeth requiring reinforcement as these posts have a favourable matching modulus of elasticity (30-40GPa) to dentin (15-25GPa) resulting in a biomechanical homogenized unit inside the root canal. [11] Composite resin bonds well to the dentinal walls after conditioning, bonding procedures and serves to reinforce

the weakened root. Modulus of elasticity of composite resin (20 GPa) is also close to that of dentin thus creating a more homogenous restorative system consisting of the post, resin cement, core material along with the tooth substance. In this way, distribution of stresses to the root is more even and there is less risk of a root fracture.

^[12] Post endodontic restoration done by using zirconium crown because of its conservative design of preparation and high translucence which enhances patient aesthetic needs. Another beneficial characteristic of zirconia is its ability to resist crack propagation through a property known as “transformation toughening,” the Zirconia particles that normally exist as a tetragonal crystal structure undergo phase transformation into a monoclinic crystal structure when a stress such as a crack tip is applied. Because the monoclinic crystal structure is larger than the tetragonal crystal structure, the crack is “sealed” before it propagate.

Due to limited number of case reported in literature we cannot perfectly predict the success rate of biological dentin post, however, Ambica K et al ^[13] and Kathuria A et al, ^[14] in their vitro study reported that dentin posts demonstrated higher fracture resistance than carbon fiber post & glass fiber posts. However, biological dentin post can be considered as promising alternative to various commercially available post systems.

CONCLUSION

MTA can be a favorable root filling for apexification. It results in good periapical seal and allows fabrication of individualized post which provides ample strength and eliminates the laboratory procedures. Composite resin bonds well to the dentinal wall after the acid etching and the tooth bonding procedure, and serves to reinforce the weakened root. The use of fiber post along with light curing composite resin facilitates complete polymerisation to the depths of the canal. The placement of identical size fiber post and composite core

build up ensures optimum resistance and retention form. Also, superior aesthetics and technique versatility are its additional advantages. Thus, even badly mutilated teeth need not necessarily be extracted. They can be restored with this technique to best serve the needs of the patient.

REFERENCES

1. R. Pace, V. Giuliani, L. Pini Prato, T. Baccetti & G. Pagavino. Apical plug technique using mineraltrioxide aggregate: results from a case series. *International Endodontic Journal*, 2007; 40: 478–484.
2. Bastone, E. B.; Freer, T. J. & McNamara, J. R. Epidemiology of dental trauma: a review of the literature. *Aust. Dent. J.*, 2000; 45(1):2-9.
3. Ambica Khetarpal, Sarika Chaudhary, Sangeeta Talwar, Mahesh Verma. Endodontic management of open apex using Biodentine as a novel apical matrix. *Indian Journal of Dental Research*, 2014; 25(4): 513-516.
4. Traebert, J.; Peres, M. A.; Blank, V.; Boell, R. da S. & Pietruza, J. A. Prevalence of traumatic dental injury and associated factors among 12-year-old school children in Florianopolis, Brazil. *Dent. Traumatol.*, 2003; 19(1):15-8.
5. Díaz, J. A. Crown fractures in upper maxillary central incisors; 24 months follow-up and clinical outcome in Children. *Int. J. Odontostomat.*, 2008;2(1):83-94.
6. Ambica Khetarpal, Sarika Chaudhry, Sangeeta Talwar, Mahesh Verma. Endodontic management of open apex using MTA and platelet – rich fibrin membrane barrier: A newer matrix concept. *J ClinExp Dent*. 2013;5(5): e291-4.
7. Rahul Kumar, SuvarnaPatil, Upendra Hoshing, Ashish Medha, Rushikesh Mahaparale. MTA Apical Plug and Clinical Application of Anatomic Post and Core for Coronal Restoration: A Case Report. *Iranian Endodontic Journal* 2011;6(2):90-94
8. Swati Bhosale, P. Mridula, M. Rameshkumar, S. Jayasree. Management of tooth with failed

- regeneration Procedure. *Journal of Interdisciplinary Dentistry*. 2014; 4(3):152-155.
9. Lenchner, N. H. & Lenchner, M. Biologic contours of teeth: Therapeutic contours of restorations, Part II. *Pract. Periodont. Aesthet. Dent.*, 1989; 1(5):18-21.
 10. Smith, C. T.; Schuman, N. J. & Wasson, W. Biomechanical criteria for evaluating prefabricated post-and-core systems: a guide for the restorative dentist. *Quintessence Int.*, 1998; 29(5):305-12.
 11. Asmussen, E.; Peutzfeldt, A. & Heitmann, T. Stiffness, elastic limit, and strength of newer types of endodontic posts. *J. Dent.*, 1999;27(4):275-8.
 12. Deshpande S S, Sarin S P, Parkhedkar R D, "Prosthetic rehabilitation of weakened root canals: a case report", *J Clin Diagn Rest*, 2008;3:1353-1356.
 13. Kaizer OB, Bonfante G, Pereira FilhoLD, et al. Utilization of biological posts to reconstruct weakened roots. *Rev Gaucha Odontol* 2008;56:7-13.
 14. Ambica K, Mabendran K, Talwar S, Verma M, Padmini g, Periasamy R. Static and fatigue loading of endodontically treated teeth restored with carbon fiber posts, and an experimental dentin post system: An in vitro study. *J Endod*. 2013;39(1): 96-100.

How to cite this article: Jahnvi B, Reddy KS, Prasad SD et al. Management of open apex using MTA and reinforcement of weekend root with customized fiber post- a case report. *Int J Health Sci Res*. 2017; 7(7):370-375.
