

Case Report

Zygomatic Air Cell Defect: A Digital Panoramic Retrospective Pilot Study

Dr. Sunita Kulkarni¹, Dr. Usha Rathod², Dr. Ashish Lanjekar³

¹Professor and HOD OMDR, ²Post Graduate Student OMDR, ³Reader OMDR
Dept of Oral Medicine and Radiology, Swargiya Dadasaheb Kalmegh Smruti Dental College & Hospital,
Nagpur.

Corresponding Author: Dr. Usha Rathod

ABSTRACT

Introduction- Pneumatized air cells present in the zygomatic process of the temporal bone are called as Zygomatic Air Cell Defects (ZACDs). This study was carried out to evaluate the prevalence of Zygomatic Air Cell Defects on panoramic radiographs.

Materials and method- A retrospective study of 200 panoramic radiographs was carried out in the Department of Oral Medicine and radiology department to evaluate the variations and characteristics of ZACDs.

Result- The prevalence of ZACDs in this study was 2.5%.

Conclusion- The prevalence of ZACDs in the present study was 2.5%. Further research with large data could provide further insights into this little known entity.

Keywords- Zygomatic air cell defect, Articular tubercle, Pneumatized articular eminence.

INTRODUCTION

The term zygomatic air cell defect was coined by Tyndall and Matteson in the year 1987 and the term pneumatized articular eminence was coined by the same investigators in 1985. Pneumatized air cells present in the zygomatic process of the temporal bone are termed Zygomatic Air Cell Defects (ZACDs). ZACDs have been defined as 'accessory air cells in the zygomatic process and articular eminence of the temporal bone, which appear similar to mastoid air cells and which do not extend further anteriorly than the zygomaticotemporal suture.'^[1]

The same has also been termed as pneumatized articular eminence and pneumatized articular tubercle. They classified ZACD into three types as Unilocular, Multilocular and Trabecular. It is presents as asymptomatic, non-expansile, nondestructive radiolucency. Unilocular

type appears as an oval radiolucent defect with well defined borders and the multilocular appear as numerous small cavities within and resemble mastoid air cells. It may become contraindications for performing surgical procedures such as eminectomy as they can become potential pathways for intracranial infections, when ZACDs have been demonstrated preoperatively on a radiograph.^[2,3,5]

Aims: To determine the prevalence, patterns of occurrence of zygomatic air cell defects using digital panoramic radiographs.

MATERIALS AND METHODS

200 digital panoramic radiographs were examined to evaluate the variations and characteristics of ZACDs.

Exclusion Criteria-

- 1.Patient with developmental malformation of face and jaw.
- 2.History of trauma to maxillofacial region.

2. Any pathologies in maxillofacial region.

METHODOLOGY -

A retrospective pilot study of 200 panoramic radiographs was carried out in the Department of Oral Medicine and radiology, Swargiya Dadasaheb Kalmegh Smruti Dental College and Hospital, Wanadongri Road, Hingna, District Nagpur. The study population comprised 200 panoramic radiographic between the age group fo 17-50 years. All radiographs were obtained with digital panoramic radiographic machine (orthophos xg system, version 2.53 sirona, Germany).

All the radiographs had been processed automatically using fujifilm medical dry laser imager fm-dl 100 Japan. The data collected were tabulated and subjected to statistical analysis.

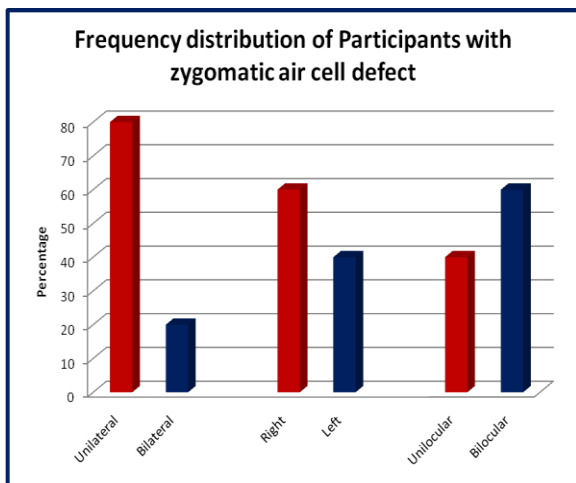
RESULT

Table 1: Prevalence of Zygomatic air cells among participants

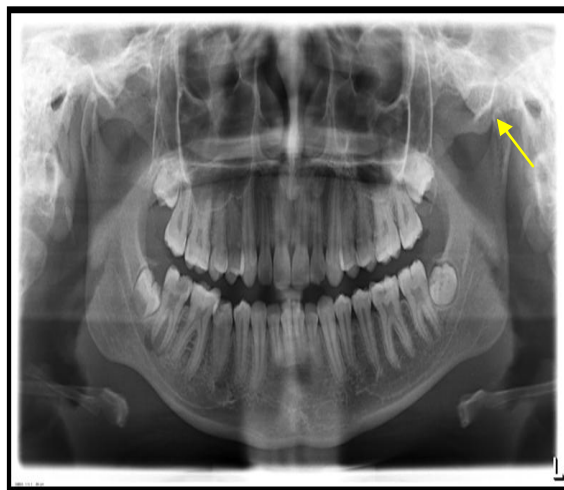
Total no of participants	Participants with Zygomatic air cells
200 (100%)	5 (2.5%)

Table 2: Frequency distribution of Participants with zygomatic air cell defect

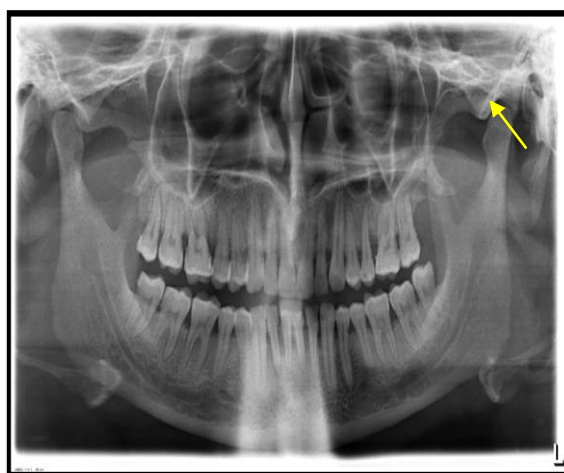
Characteristics		Frequency	Percentage
Sex	Male	3	60.0
	Female	2	40.0
Involvement	Unilateral	4	80.0
	Bilateral	1	20.0
Site	Right	3	60.0
	Left	2	40.0
Locule	Unilocular	2	40.0
	Multilocular	3	60.0



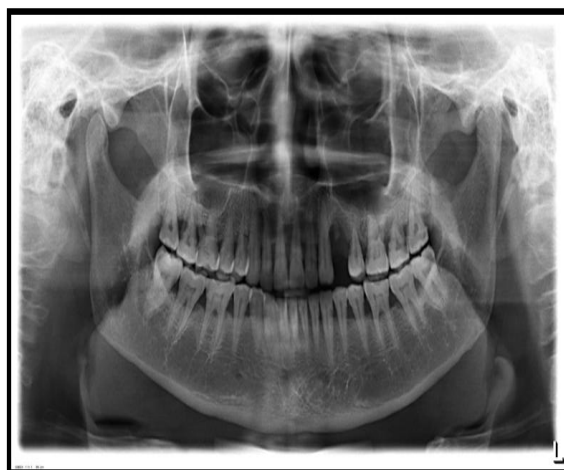Graph -1



Dig -1 Unilateral ZACD



Dig.2 - Unilateral ZACD



Dig.3-Bilateral ZACD

The prevalence of ZACDs in the present study was 2.5%. There were 4 unilateral ZACDs and 1 bilateral ZACDs. Among the 5, 3 occurred on the right side and 2 occurred on the left side. 2 were unilocular and 3 were multilocular

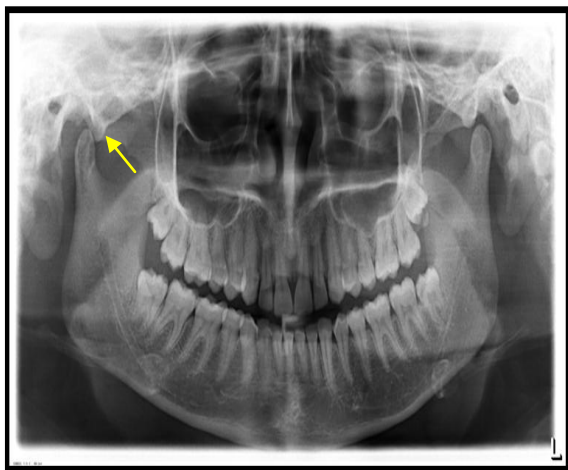


Fig.4-Unilateral ZACD

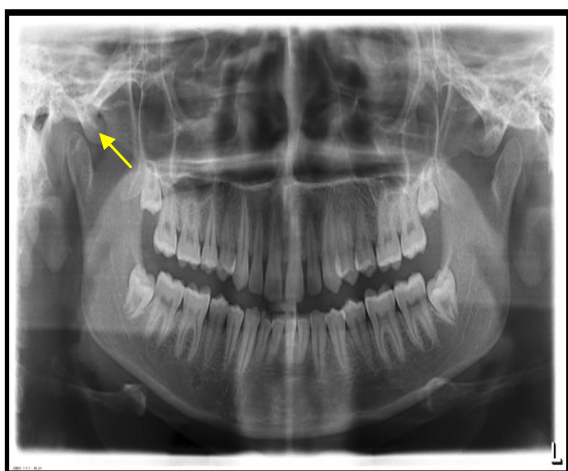


Fig.5-Unilateral ZACD

DISCUSSION

ZACDs appear radiographically as nonexpansile and nondestructive radiolucency in the zygomatic process of the temporal bone or the articular eminence and are clinically asymptomatic. These air spaces can be breached during maxillofacial trauma. Fracture or dehiscence of the glenoid fossa may lead to herniation of soft tissue contents into the middle ear and further result in the middle ear infections and mastoid effusion. They may serve as an entry port for mastoid tumors to extend into temporomandibular joint (TMJ). [3] Otitis or mastoiditis extending to the TMJ can result in ankylosis of TMJ. Pathologies such as the aneurysmal bone cyst, central hemangioma, eosinophilic granuloma, fibrous dysplasia and have been recognized to have involved the zygomatic processes of the temporal bone. If the zygomatic process of the

temporal bone or the articular eminence exhibits a unilocular or multilocular radiolucency which is incidental then it is suggestive of a ZACD. It is of prime importance that radiologists, diagnosticians, surgeons be aware of this entity so that precise identification can be made, which prevents unnecessary investigations and explorations and helps to prevent potential complication. In the study done by Carter et al the result was 32 were unilateral and 8 were bilateral, 24 cases of ZACD (77.4%) were unilateral and 7 cases (22.6%) were bilateral by Parker et al. and Srikanth et al., and in their study conducted in South Indian population 15 were unilateral and 6 were bilateral. [4]

CONCLUSION

Recognition of ZACDs and differentiation from other pathologies by oral and maxillofacial radiologists, oral surgeons and general dentists is extremely important to prevent any untoward complications. The prevalence of ZACDs in the present study was 2.5%. Further research with large data could provide further insights into this little known entity. [3]

REFERENCES

1. Carter LC, Haller AD, Calamel AD, Pfaffenbach AC. Zygomatic air cell defect (ZACD). Prevalence and characteristics in a dental clinic outpatient population. *Dentomaxillofacial Radiology*. 1999 Mar 1;28(2):116-22.
2. Orhan K, Delilbasi C, Orhan AI. Radiographic evaluation of pneumatized articular eminence in a group of Turkish children. *Dentomaxillofacial Radiology*. 2014 Jan 28.
3. Park YH, Lee SK, Park BH, Son HS, Choi M, Choi KS, An CH. Radiographic evaluation of the zygomatic air cell defect. *Korean Journal of Oral and Maxillofacial*

- Radiology. 2002 Dec 1;32(4):207-12.
4. Nagaraj T, Nigam H, Balraj L, Santosh HN, Ghouse N, Tagore S. A population-based retrospective study of zygomatic air cell defect in Bengaluru.
 5. Stoopler ET, Pinto AA, Stanton DC, Mupparapu M, Sollecito TP.
- Extensive pneumatization of the temporal bone and articular eminence: an incidental finding in a patient with facial pain. Case report and review of literature. Quintessence international. 2003;34(3):211.

How to cite this article: Kulkarni S, Rathod U, Lanjekar A. Zygomatic air cell defect: A digital panoramic retrospective pilot study. Int J Health Sci Res. 2017; 7(6):347-350.
