

Case Report

An Adjunctive Periodontal Surgical Procedure for Advancement of Plastic-Surgically Treated Cleft Lip: A Case Report

Dr. Hoti Lal gupta¹, Dr. Shahebaz Qureshi², Dr. Pradeep Kumar³, Dr. Faizan Sharif²

¹Professor & Head of the Department, ²PG Student, ³Reader,
Department of Periodontology & Oral Implantology, Rajasthan Dental College & Hospital, Jaipur.

Corresponding Author: Dr. Shahebaz Qureshi

ABSTRACT

In oral cavity, frenum is the normal anatomical landmark which attaches the lip and the cheek to the alveolar mucosa, gingiva and the underlying periosteum. The aberrations or abnormalities or deformities in the frenal attachment at times, may pose problems to gingival and periodontal health either due to an interference in the plaque control or due to a muscle pull. In addition to this, an abnormal frenum attachment can cause many problems such as aesthetic, functional problem, localized gingival recession and loss of sulcus depth. Therefore management of aberrant frenum is important. In the present case report the sequelae and management of aberrant frenum has been discussed.

Keywords: Aberrant frenum, Frenectomy, Labial frenum.

INTRODUCTION

ABBERANT FRENUM

Frenum is a fold of mucous membrane, usually with enclosed muscle fibers, that attaches the lips and cheeks to the alveolar mucosa and /or gingiva and underlying periosteum. [1] There are many frena that are usually present in a normal oral cavity, most commonly seen are maxillary labial frenum, the mandibular labial frenum, and the lingual frenum. [2] Primary function of the frenum is to provide stability of the upper and lower lip and the tongue. [3] Superior labial frenum extends over the alveolar process in infants and forms a raphe that reaches the palatal papilla. Through the growth of alveolar process as the teeth erupt, this attachment generally changes to assume the adult configuration. [4] But in some cases or situations, the infantile arrangement is retained and this high coronal attachment is generally associated with a hypertrophy of

the frenum. [5] Placek et al (1974) [6] has classified frenum depending upon the extension of attachment of fibres,

- **Mucosal** – when the frenal fibres are attached up to mucogingival junction.
- **Gingival** – when fibres are inserted within attached gingiva.
- **Papillary** – when fibres are extending into interdental papilla; and
- **Papilla penetrating** – when the frenal fibres cross the alveolar process and extend up to palatine papilla.

Abnormal or aberrant frena can be detected visually, by applying tension over it to see the movement of papillary tip or blanch produced due to ischemia of the region. According to Millar the frenum should be characterized as pathogenic when it is unusually wide or there is no apparent zone of attached gingiva along the midline, or the interdental papilla shifts when the

frenum is extended. [7] Frenum may jeopardize the gingival health when they are attached too closely to the gingival margin, either due to an interference in the plaque control or due to a muscle pull. [8] Clinically, papillary and papilla penetrating frenum are considered as pathological and have been found to be associated with loss of papilla, recession, diastema, difficulty in brushing, mal-alignment of teeth and it may also affect the denture fit or retention leading to psychological disturbances to the individual. [5]

According to Olivi et al, [9] clinical indications for frenum removal include:

- Anomalous frenum associated with inflamed gingiva, resulting from poor oral hygiene.
- Anomalous frenum associated with gingival recession.
- Maxillary frenum associated with a diastema after complete eruption of the permanent canines.
- Abnormal and/or anomalous maxillary frenum (Class III or IV), resulting in the presence of a diastema during mixed dentition
- Anomalous mandibular frenum with high insertion, causing the onset of gingival recession.
- Management of aberrant frenum is usually carried out with frenectomy and frenotomy procedures. Frenectomy is the complete removal of the frenum, including its attachment to the underlying bone, while frenotomy is the incision and the relocation of the frenal attachment. [1]

CLEFT LIP

Cleft lip (Cheiloschisis) is a most common congenital facial anomaly. It is due to non fusion of maxillary process with medial nasal processes (Globular process). A cleft lip can be either unilateral or bilateral. The oral clefts are congenital anomalies caused by the interaction between genetic and environmental factors. The oral clefts result from failure of migration of neural crest cells or non fusion of the facial

prominences between 4th and 8th weeks after conception.

INCIDENCE:-

- Most cases of Cleft lip are multifactorial.
- Cleft lip (Approximately 1/1,000 births) occurs more frequently in males 80% than in females, its incidence increases slightly with maternal age.
- If normal people have one child with a cleft lip, the chance that the next baby will have the same defect is 4%.
- If two siblings are affected, the risk for next child is 9%.

Esthetic concerns have led to an increased demand in seeking dental treatment for achieving perfect smile. Midline diastema in central incisors is one of the major esthetic problems encountered in adults. Since the presence of an aberrant frenum is one of the causative factors of the persistence of a midline diastema, it becomes essential to focus on the importance of frenum in terms of morphology and attachment. [10] The frenum is a mucous membrane fold that attaches the lip and the cheek to the alveolar mucosa, the gingiva, and the underlying periosteum. Oral cavity exhibits most notably the maxillary labial frenum, the mandibular labial frenum, and the lingual frenum. Labial frenum attachments are thin folds of mucous membrane containing muscle fibers originating from orbicularis oris muscle of upper lip which provides attachment to the alveolar mucosa and underlying periosteum. Developmentally, the maxillary labial frenum is a post-eruptive remnant of the ectolabial band that connects the tubercle of the upper lip to the palatine papilla. [11]

Unusually, wide frenum is characterized as pathogenic. Clinically, papillary and papilla penetrating frenal attachments are considered pathological and are associated with papillary loss, gingival recession, diastema formation, difficulty in brushing, misaligned teeth, and psychological disturbances. [12]

Frenal attachments that encroach on the marginal gingiva leads to distention of the gingival sulcus, favoring plaque accumulation, increasing the rate of progression of gingival recession and thereby leading to recurrence after treatment. [13] The management of an aberrant frenum can be accomplished by “frenectomy” or “frenotomy” procedures. The terms frenectomy and frenotomy signify operations that differ in degree of surgical approach.

Frenectomy is a complete removal of the frenum, including its attachment to the underlying bone whereas frenotomy involves relocation of the frenal attachment.

CASE REPORT

A 20 year old female, visited outpatient clinic of oral medicine & radiology and later was referred to periodontology & oral implantology, Rajasthan dental college & hospital, Jaipur, with a chief complaint of restricted lip

movement. Patient was examined intra orally and extra orally. On intraoral clinical examination MLLF (median lateral labial frenum) [23] was found. Cleft lip was plastic-surgically treated after her birth and had no complaints regarding it, except restricted lip movement due to aberrant frenum. There was no any past medical history. Radiological and blood investigation were carried out. Blood pressure was recorded and was under normal level.

The present surgical technique was undertaken at Rajasthan dental college and hospital, Jaipur. The patient underwent frenectomy for functional, aesthetic & periodontal reasons. Frenectomy was done with ‘modified technique’ (modification of classical technique).

Following treatment plan was proposed. Scaling and root planning as phase I therapy was carried out. It was decided to subject the patient for surgical procedure (frenectomy). Patient was explained about the procedure and consent was obtained.

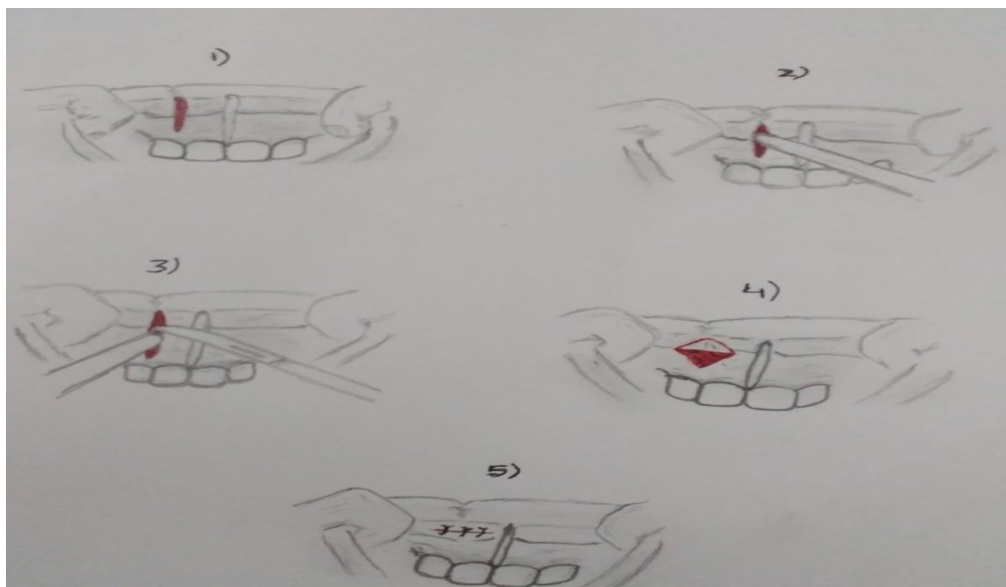


FIGURE- line diagram showing frenectomy procedure

- 1) MLLF (median lateral labial frenum)
- 2) Incision placed
- 3) Frenum engaged with heamostat and horizontal incision given
- 4) Triangular wound area
- 5) Interrupted Suture

PROCEDURE

On clinical examination, a gingival penetrating MLLF upper frenum was found. 2ml of local anesthesia containing 2 %

lignocaine hydrochloride with 1:80,000 adrenaline was infiltrated labially and incisive nerve block was administered. The frenum was engaged with a haemostat

which was inserted into the depth of the vestibule and incisions were placed on the upper of the frenum, the fibres inside mucosal surface were freed from bone attachments with the help of periosteal elevator. Surgical area was thoroughly irrigated with normal saline. The edges of the incised mucosa were sutured by using 4-0 vicryl with periosteum in form of interrupted sutures & periodontal pack (COE pack) was given to cover the exposed wound surface. Analgesic and antibiotics were prescribed. After 1 week sutures removed, healing was uneventful and no post-operative complications were noticed.



Figure-2 pre-operative image

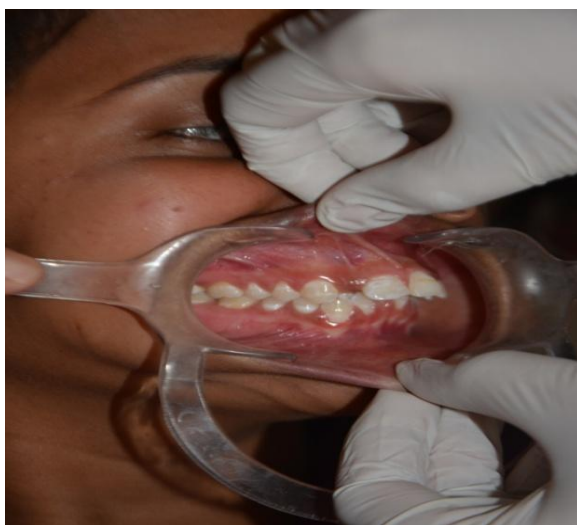

Figure-3 MLLF (median lateral labial frenum)

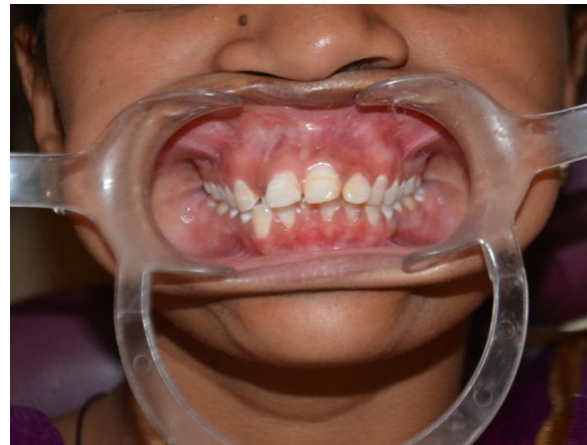

Figure-4 post operative image of treated aberrant frenum



Figure-5 post operative image after 2 month of follow up

DISCUSSION

The prevalence of different types of the labial frenum attachment and its significance in periodontal health is an important aspect of treatment plan. The mucosal type of the labial frenum attachment is found to be the most common, with a percentage of 46.6% in maxillary and 92.1% in mandibular arch. The second most frequent type of the labial frenum attachment is the gingival one which is 34.4% in the maxillary and 6.5% in the mandibular arch. The papillary type of the labial frenum attachment-3.1% in the upper and 0.2% in the lower jaw, always causes the pull syndrome and is associated with the appearance of pathologically changed midline interdental papillae. The papillary penetrating type of labial frenum attachment is 16.1% in the maxillary and 1.2% the mandibular arch. [4]

Frenum associated with Cleft lip treated individual is a rare entity. Unaesthetic smile is the main issue and problem for such cases. Such cases should be treated for regaining the lost smile and to reduce the forthcoming periodontal problems in future.

Abnormal frenum and muscle pull has been considered detrimental to periodontal health by pulling away the gingival margin from the tooth and thus contributing to accumulation of plaque and calculus, leading to inflammation and pocket formation. [14] Hirschfeld (1939) was the first one, who called upon the attention to the marginal attachment of the frenum, as an etiologic factor in periodontal disease and recommended its excision or complete removal. [15] A high frenal attachment may hinder the performance of adequate oral hygiene at some extent. [16] The conventional technique was introduced by Archer (1961) and Kruger (1964). This technique involves excision of frenum by using scalpel which includes interdental tissues and palatine papilla along with the frenulum. Presence of muscle fibers in aberrant frenum could play a co-destructive role by exerting forces along with elastic and collagenous components of the gingiva. Excisional surgery of aberrant labial frenum with conventional technique ensures removal of the muscle fibers which were supposedly connecting the orbicularis oris with the palatine papilla along with dense connective tissue up to the level of the alveolar bone in order to prevent its recurrence and eventual pathological sequelae. Also, it is always a safe surgical procedure with minimal complications. [10]

A number of modifications of the various surgical techniques including Miller's technique, V-Y plasty and Z-plasty have been introduced to manage problems associated with an aberrant labial frenum. [2]

The use of electrosurgery in the management of aberrant frenum has an advantage over the conventional technique such as minimal time consumption, mild bleeding and the minimal postoperative

complications. However, its disadvantages include burns, the risk of an explosion if combustible gases are used, interference with pacemakers and the production of surgical smoke. [17]

The recently introduced technique in the management of aberrant frenum is lasers. Some of the lasers used are diode, carbon dioxide, Nd:YAG, Er:YAG and Er, Cr: YSGG. [18-22] According to the studies done by Haytac et al [21] and Kara, [22] using CO2 laser and Nd: YAG laser, have shown that there was an improved patient perception in terms of postoperative pain and function than that obtained by the scalpel technique. However, the main disadvantages are high cost, requirement of sophisticated equipment, and reduced surgical precision resulting in an inadvertent laser-induced thermal necrosis and/or a photo acoustic injury.

CONCLUSION

The aberrant frenum can interfere with normal oral hygiene maintenance and can result in other mucogingival problems. The present case report suggests that early detection and correction of MLLF (median lateral labial frenum) associated with cleft lip by the clinician can positively affect the periodontal health and prevent further progression of periodontal disease.

ACKNOWLEDGEMENT

The authors sincerely thank the patient and teaching faculty of department of periodontology and oral implantology, RDCH, Jaipur for their contribution in this case report.

REFERENCES

1. Newman, Takei, Klokkevold, Carranza, Periodontal Plastic And Esthetic surgery, In F.A. Carranza (Ed), Carranza's Clinical Periodontology, 10 (Missouri: Saunders: An Imprint Of Elsevier Science 2006) 1023-1024.
2. M. Priyanka, R. Sruthi, T. Ramkrishnan, P. Emmadi, N. Ambalavanan N. An Overview Of Frenal Attachments. J Indian Soc Periodontol 2013; 17: 12-15.
3. S.M. Mintz, M.A. Siegel, P.J. Seider. An Overview Of Oral Frena And Their Association With Multiple Syndromes

- And Nonsyndromic Conditions. Oral Surg Oral Med Oral Pathol Oralradiolendod 2005;99:321-324.
4. SW Henry, MP Levin, Tsaknis PJ. Histological Features Of Superior Labial Frenum. J Periodontol 1976;47:25-28
 5. Anubha N, Chaubey KK, Aroravk, Narula IS. Frenectomy Combined With A Laterally Displaced Pedicle Graft. Indian J Dentsci 2010;2:47-51.
 6. Placek M, Miroslavs, Mrklas L. Significance Of The Labial Frenal Attachment In Periodontal Disease In Man. Part 1; Classification And Epidemiology Of The Labial Frenum Attachment. J Periodontol 1974;45:891-894.
 7. Miller P D Jr. The Frenectomy Combined With A Laterally Positioned Pedicle Graft; Functional And Aesthetic Consideration. J Periodontol 1985;56:102-106
 8. Millar PD. The Aberrant Frenum, Handbook Of PD Millar.2006. P.29-34 .
 9. Olivi G, Chaumanet G, Genovese MD, Beneduce C, Andreana S. The Er,Cr:YSGG Laser Labial Frenectomy: A Clinical Retrospective Evaluation Of 156 Consecutive Cases. Gen Dent 2010; 58:126-133.
 10. Devishree, Gujjari SK, Shubhashini PV. Frenectomy: A Review With The Reports Of Surgical Techniques. J Clin Diag Res 2012; 6(9):1587-159
 11. Lawande SA, Lawande GS. Surgical management of aberrant labial frenum for controlling gingival tissue damage: A case series. Int J Biomed Res 2013;4:574-8.
 12. Chaubey KK, Arora VK, Thakur R, Narula IS. Perio-esthetic surgery: Using LPF with frenectomy for prevention of scar. J Indian Soc Periodontol 2011;15: 265-9.
 13. Newman MG, Takei HH, Klokkevold PR, Carranza FA. Carranza's Clinical Periodontology. 10th ed. Philadelphia: WB Saunders Co.; 2006. p. 866-70.
 14. Bhaskar N, Garg A K, Gupta V. Review Article. Periodontics As An Adjunct To Clinical. Orthodontics: An Update. Indian Journal Of Multidisciplinary Dentistry 2013;3:756-761.
 15. Kesselerm.; Interrelationships Between Orthodontic And Periodontics; Am J Orthod;1976; 70:154-172.
 16. BmistinE, MachteiE, Becker. The Attached Gingiva In Children: Diagnostic Developmental And Orthodontic Considerations For Its Treatment. ASDC J Dent Child 1998;55:351-356.
 17. Cunha RF, Silva JZ, Faria MD. A Clinical Approach of Ankyloglossia In Babies: A Report Of Two Cases. J Clin Pediatr Dent 2008; 32:277-282.
 18. Epstein SR. The Frenectomy: A Comparison of Classic versus Laser Technique. Pract Periodontics Aesthet Dent 1991; 3:27-30.
 19. Gontijo I, Navarro RS, Naypek P, Ciamponi AL, Haddad AE. The Application Of Diode And Er:YAG Lasers In Labial Frenectomies In Infants. J Dent Child 2005; 72(1):10-15.
 20. Pie-Sanchez J, Espana-Tost AJ, Arnabat-Dominguez J, Gay-Escoda C. Comparative Study Of Upper Lip Frenectomy With CO2 Laser Versus The Er, Cr:YSGGLaser. Med Oral Patol Oral Cir Bucal2010; 17(2): E228-232.
 21. Haytac MC, Ozcelik O. Evaluation Of Patient Perceptions After Frenectomy Operations: A Comparison Of Carbon Dioxide Laser And Scalpel Techniques. J Periodontol 2006; 77(11):1815-9.
 22. Kara C. Evaluation Of Patient Perceptions Of Frenectomy: A Comparison Of Nd:YAG Laser And Conventional Techniques. Photomed Laser Surg 2008; 26(2): 147-152.
 23. Ranjana Mohan, Pankaj Kumar Soni, Munagala Karthik Krishna, Mohan Gundappa; Proposed classification of medial maxillary labial frenum based on morphology; Dental Hypotheses Jan-Mar 2014; 5 - 1

How to cite this article: Gupta HL, Qureshi S, Kumar P et al. An adjunctive periodontal surgical procedure for advancement of plastic-surgically treated cleft lip: a case report. Int J Health Sci Res. 2017; 7(4):468-473.
