

Original Research Article

Histopathological Study of Lesions of the Appendix

Dr. Medha P. Kulkarni¹, Dr. (Mrs.) Kalpana Ranjitsingh Sulhyan², Dr. Shaikhali M. Barodawala³,
Dr. Deepika Hanumanprasad Yadav⁴

¹Associate professor, ²Professor and Head, ³Senior Resident, ⁴Junior Resident,
Department of Pathology, Government Medical College, Miraj.

Corresponding Author: Dr. Deepika Hanumanprasad Yadav

ABSTRACT

The human appendix is a supposedly functionless organ, but can cause morbidity & mortality because it is likely to become infected. A two years study was performed to determine the incidence of various non-neoplastic and neoplastic lesions of the appendix. In each case, clinical findings were correlated with histopathological features. Out of 436 appendectomy specimens, 99.34% were involved by non-neoplastic lesions and 0.66 % by neoplastic lesions. Non- neoplastic lesions included acute appendicitis with/without perforation, chronic appendicitis, worm infestation and fibrous obliteration. Neoplastic lesions included 1 case each of neuroendocrine neoplasm (NET), adenoma & Non-Hodgkin lymphoma.

Keywords: Appendicitis, non-neoplastic, neoplastic.

INTRODUCTION

The appendix performs no known useful function in humans, but acute appendicitis is the most common abdominal emergency in childhood, adolescents & young adults. ^[1] The diagnosis of appendicitis can be difficult at times, occasionally taxing the skills of the most experienced clinician. ^[2] Histopathological examination still remains the gold standard for the confirmation of appendicitis. Not only the pathologic diagnosis of acute inflammation, unusual findings such as incidental tumors noted in the appendix highlight the importance of pathologic analysis of every single resected appendix. ^[3] Appendiceal tumors are unusual, the majority being neuroendocrine tumors (NET/carcinoids) while the remaining includes adenoma, adenocarcinoma, lymphomas & Kaposi sarcoma. ^[4] Hence the study was undertaken with the aim of determining the incidence of various lesions of the appendix and studying the gross and

microscopic features with clinico-histopathological co-relation.

MATERIALS AND METHODS

The present study was conducted in the Department of Pathology, Government Medical College, Miraj. Histopathological examination of resected appendices was done prospectively over a period of 2 years and 2 months from 1st June 2006 to 31st August 2008. In each case, a brief clinical history and physical examination along with the evaluation of available relevant investigations was carried out. The specimens were fixed in 10% buffered formalin. A detailed gross examination of the appendectomy specimen was carried out. The cut section was looked for luminal patency, presence of faecolith, pus, mucus and worms (parasites). 3 sections including one transverse from middle-third, one from resection margin and one longitudinal section from the tip were submitted for histopathology. Following the grossing of

the specimens, formalin fixed, paraffin embedded tissue blocks were cut using a rotary microtome and staining was done using Hematoxylin and Eosin. The histopathological findings were correlated with the clinical findings and final report was prepared.

RESULTS

A total of 436 cases were studied. 241/436 (55.27%) were males & 195 females (44.73%). The youngest patient was 1 year old and the oldest was 70 years old. Maximum numbers of appendicectomies were observed in 3rd decade of life. Appendices constituted approximately 9.33% of all specimens each year.

The most common symptom was right iliac fossa pain followed by generalized pain in abdomen and fever. Diagnostic accuracy of acute appendicitis was 95% while chronic appendicitis was correctly diagnosed pre-operatively in only 18.04% of cases. A huge number i.e. 141 out of 205 cases (68.78%) of chronic appendicitis were incorrectly diagnosed clinically as acute appendicitis. The most common lesion seen was chronic non-specific appendicitis in 205 (47.02%) cases followed by acute appendicitis with or without periappendicitis in 197(45.28%) cases. Number of acute appendicitis was more in males, 65 cases (63.72%) than females, 37 cases (36.28%). Acute appendicitis with perforation was also more common in males 58 (63.04%) than females

34(36.96%). Total 58 cases (13.30%) of periappendicitis were encountered.

We encountered one case each of Xanthogranulomatous appendicitis, neuroendocrine tumor (NET), adenoma and Non Hodgkin Lymphoma involving the appendix.

Table no.1 Showing the age and sex distribution of cases

Age Group (yrs)	Males	Females	Total	Percentage
0-10	16	12	28	6.42
11-20	78	63	141	32.33
21-30	76	63	139	31.88
31-40	46	37	83	19.00
41-50	11	14	25	5.70
51-60	07	04	11	2.5
61-70	05	02	07	1.6
71-80	02	-	02	0.45
TOTAL	241 (55.27%)	195 (44.73%)	436	100

Table no. 2 .Microscopic findings in appendicectomy specimen

INFLAMMATORY/NON-NEOPLASTIC			
Chronic Appendicitis with or without Periappendicitis		205	47.02
Acute Appendicitis with or without Periappendicitis		102	23.40
Acute Appendicitis with Perforation peritonitis		92	21.20
Acute Gangrenous appendicitis		03	0.68
Chronic appendicitis with E.Vermicularis		14	3.3
Fibrous Obliteration of the Appendix		15	3.4
Xanthogranulomatous appendicitis		01	0.22
Periappendicitis only		01	0.22
TOTAL		433	99.44

NEOPLASTIC CONDITIONS:

NEOPLASTIC CONDITIONS	NO. OF CASES n=436	Percentage (%)
Neuroendocrine Tumor	01	0.22
Non Hodgkin lymphoma	01	0.22
Adenoma	01	0.22
Total	03	0.66

Table No 3- Acute Appendicitis

Diagnosis	No of cases	Percentage (%)
Acute Appendicitis with or Without Periappendicitis	102	51.77
Acute Appendicitis with Perforation	92	46.70
Acute Gangrenous Appendicitis	03	1.53
Total	197	100

DISCUSSION

In the present study 436 appendectomy specimens were studied in Department of Pathology, Government Medical College, Miraj. The histopathological examination of the appendix serves two purposes. First it

allows the diagnosis of acute appendicitis to be confirmed; second, it may disclose additional pathologies that may not be evident intraoperatively but may impact patient management.

The age range was wide with slight male preponderance. This has been reported

by other studies also. [5,6] The mean length of appendix was 5.5cms in our study.

Chronic appendicitis constituted the single largest category of diagnosis 205/436 (47.02%) in the present study. Criteria for diagnosis of chronic appendicitis were evidence of active chronic inflammation with infiltration of the muscle coat & serosa by lymphocytes & plasma cells. [1] 184 out of 205 cases of chronic appendicitis showed hyperplastic lymphoid follicles with prominent germinal centres indicating stimulation of B cell mediated immune response. 15 cases of chronic appendicitis had associated periappendicitis (25.86%). Total number of acute appendicitis encountered was 197/436 cases.

Maximum number of cases, 139 (31.88%) were in the age group 21-30 years. Total numbers of cases from 11-30 years were 280 (55.42%). Herd M.E⁷ had 60.56% of patients in this age range. Unequivocal luminal obstruction usually in the form of a faecolith can be found in 35-40% patients with appendicitis. Other less common causes of obstruction include parasites, food residue, seeds, barium from radiographic studies and neoplasms of the caecum and proximal appendix itself. [8] Functional obstruction due to lymphoid hyperplasia has also been implicated. In infancy and old age when appendicitis is rare, lymphoid tissue is relatively scant whereas there is abundant lymphoid tissue in older children and young adults in whom appendicitis is common. [8]

Differential diagnoses of acute appendicitis include acute mesenteric adenitis, acute gastro-enteritis, intussusception, Crohn's enteritis, perforated peptic ulcer, ureteric stones and gynecologic disorders like pelvic inflammatory disease or ruptured ectopic pregnancy. [2]

Acute appendicitis (AA) with or without periappendicitis accounted for 102 cases, AA with perforation for 92 cases & acute gangrenous appendicitis for 3 cases. Periappendicitis associated with AA was found in 42 (72.5%) cases.

One of the complications of acute appendicitis is perforation. We had 97 cases

of perforation with acute appendicitis (49.23%). Cooley B [6] reported 33.75% incidence of perforation in acute appendicitis.

Both Nabipour F [5] and Lau W et al [10] report the rate of gangrenous appendicitis as 8% in their respective studies. We found it to be just 1.53% of all cases of AA. The discrepancy may be because of smaller sample size or early intervention.

14 cases (3.3%) of *E. Vermicularis* infestation were noted. Of them 42.86% were clinically diagnosed as acute appendicitis and 28.57% each as chronic and recurrent appendicitis. Mowlavi G.H et al [11] have stated that *E. vermicularis* is associated with chronic inflammatory changes in most of the cases rather than acute inflammation. In the present study all cases were associated with chronic inflammation of the appendix. Gordon [12] found 82% of these parasites to be luminal, not attached to the mucosa. In our study except for one case, all (92.85%) were luminal (Fig .1)

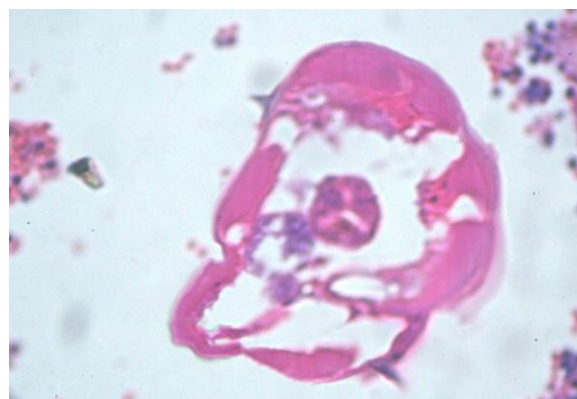


Figure 1. Photomicrograph showing *E. Vermicularis* in the lumen of appendix (H & E x400)

Fibrous obliteration of the appendix has been described under a plethora of terms such as neurogenic appendicitis, Neuromatosis of the appendix, neurogenic appendicopathy and axial neuroma. The incidence of fibrous obliteration is found to be steadily increasing with age. The process characteristically involves the distal tip, but it may progress for a variable length along the lumen, sometimes obliterating the entire

organ. Microscopically, the lumen is replaced by fibrous tissue & chronic inflammatory cells, usually accompanied by nerve cells & neuroendocrine cell proliferation. Neural tissue proliferation can be highlighted by neuron specific enolase & S-100 protein. [13]

We had 15/436 cases of fibrous obliteration of appendix. Periappendicitis is characterized by acute or chronic inflammation of serosa beyond that seen with surgical manipulation. It is associated with advanced appendicitis & spread of inflammatory processes from another site. Periappendicitis without significant mural or luminal inflammation may indicate other intra abdominal pathology including salpingitis, Meckel's diverticulitis, infectious colitis, peritonitis, urologic disorders & gastrointestinal perforation. [14]

In our study, we had total 58 cases of periappendicitis (13.30%). Of these, 42 cases (72.41%) were associated with acute appendicitis and 15 cases (25.86%) with chronic appendicitis. One case (1.73%) of isolated periappendicitis was noted. However, other details of the patient were not available. Fink A.S [15] reported 76.1% cases of periappendicitis associated with acute appendicitis and 3.4% with chronic appendicitis.

Xanthogranulomatous appendicitis is a rare entity characterized by an infiltrate composed of foam cells, scattered multinucleated histiocytes, abundant hemosiderin & luminal obliteration with spared lymphoid follicles. Various pathogenetic mechanisms have been proposed for xanthogranulomatous infiltration including deficiency in lipid transport, disturbance of leukocyte & macrophage chemotaxis, infection of *Proteus* & *Escherichia* species and lymphatic obstruction. [16] Birch P J et al have reported two cases of xanthogranulomatous appendicitis. [17] In our study, we had one case of this entity (0.22%). The appendix was received in two pieces. On microscopic examination the fragmented wall showed sheets of foamy

macrophages admixed with mononuclear cells, predominantly lymphocytes and polymorphs. The serosa also showed foamy macrophages.

Neuroendocrine tumors (NETs) are the most common neoplasms of the appendix accounting for 85% of all tumors & occurring in 0.02-1.5% of all appendectomy specimens. They are classified into three subtypes, EC cell NET, L cell NET & mixed adenoneuroendocrine tumors. [4]

Criteria for diagnosis of appendiceal NETs are: a) Collection of cells demonstrating definite insular pattern of growth with extension of cells into or through the muscular wall. b) Gross nodule or an expansion of the appendix. [13]

In our study, a single case of neuroendocrine tumor of the appendix was encountered in a 35 yr old male. Grossly the appendix was enlarged and turgid measuring 6cm in length. The cut section showed a tiny 0.8cm yellowish circumscribed nodule at the tip. Microscopically in addition to acute appendicitis there was a tumor composed of monotonous round to polygonal cells having centrally located nuclei with salt & pepper chromatin and scant to moderate amount of eosinophilic cytoplasm arranged in insular pattern (Fig.2).

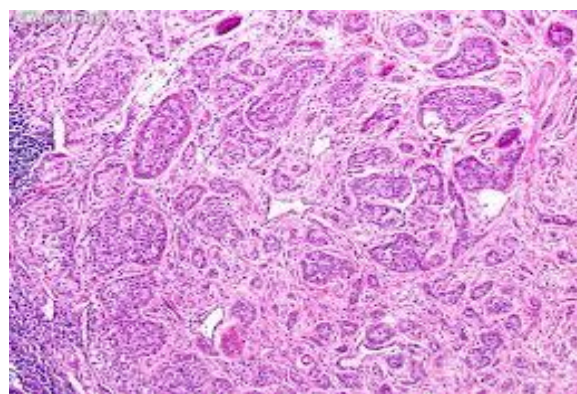


Figure 2- Photomicrograph showing NET with monotonous cells arranged in insular pattern (H & E x 400)

According to WHO 2010 criteria, our case belonged to NET G1 class. Carcinoid syndrome is extremely rare in appendiceal tumors & is almost always

related to widespread metastasis, usually to the liver & retroperitoneum. [4]

The spectrum of mucinous appendiceal tumors includes adenoma, low grade appendiceal neoplasms and mucinous adenocarcinomas. The term cystadenoma is no longer recommended for appendix. [4] Chan W et al [3] reported only 6 cases of mucinous cystadenoma (0.05%) in their study of 12,513 appendices.

In our study, we had a single case of adenoma of the appendix. The patient was a 45 years female with clinical diagnosis of chronic appendicitis. Grossly, the appendix was dilated, but external surface did not show any mucin deposits. Cut section revealed luminal mucin with marked thinning of the wall. Microscopy showed wall of appendix lined by a single layer of columnar cells with apical mucin vacuole and basally oriented hyperchromatic nuclei. (Fig.3) Mitotic figures were not seen. There was no extra-appendiceal mucin. Also the muscular wall was intact without any invasion by neoplastic epithelium. The surgical resection margin of the appendix was free.

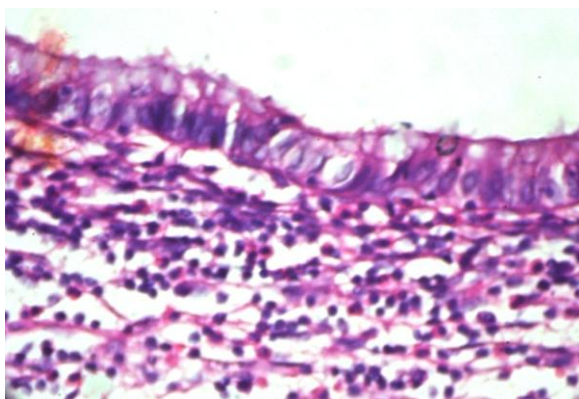


Fig.3 - Photomicrograph showing adenoma. The lining neoplastic cells show hyperchromatic basal nuclei & apical mucin vacuole. (H & E x400)

Lymphomas usually involve the appendix as part of more generalized intestinal spread. Presentation with primary disease of the appendix is rare. [4] Chan W et al [3] reported two cases of appendiceal involvement (0.015%) by lymphoma secondary to disseminated primary intestinal disease. Collins DC [18] reported 11 cases of

appendiceal NHL in a 40 year study of 71,000 specimens. We had a single case of NHL in our study.

CONCLUSION

Histopathological examination of every appendix is necessary for confirmation of acute or chronic appendicitis. Besides, parasitic infestations, neoplasms of appendix and unusual conditions like xanthogranulomatous appendicitis can be diagnosed only on histopathology.

REFERENCES

1. Shepherd NA, Warren BF, Williams GT (Eds). Morson and Dawson's Gastrointestinal Pathology. 5th edition. Wiley-Blackwell Science 2013.
2. Williams NS, Bulstrode JK, O'Connell PR (Eds). Bailey and Love's Short Practice of Surgery. 26th edition, CRC press, London 2013.
3. Chan W, Fu KH. Value of routine histopathological examination of appendices in Hong Kong. J Clin Pathol 1987; 40: 429-433.
4. Hamilton S.R., Aaltonen L.A. (Eds.): World Health Organization Classification of Tumours. Pathology and Genetics of Tumours of the Digestive System. IARC Press: Lyon 2010.
5. Nabipour F. Histopathological Features of Acute Appendicitis in Kerman-Iran from 1997-2003. Am J EnvSci 2005; 1:130-132.
6. Duzgun AP et al. Unusual findings in appendectomy specimens: Evaluation of 2458 cases and review of Literature. Ind J Surg 2004;66:221-226.
7. Herd ME, Cross PA, Dutt S. Histological audit of acute appendicitis. J Clin Pathol 1992; 45:456-458.
8. Schwartz's Principles of Surgery. Brunicaardi FC(Ed), 9th edition, The McGraw Hill Companies, United States of America, 2010.
9. Cooley B. Surgical Pathology of Acute Appendicitis. Human Pathology 1981; 12(10): 870-878.
10. Lau WY, Fan ST, Yiu TF et al. The clinical significance of routine

- histopathologic study of the resected appendix and safety of appendiceal inversion. *Surg Gynecol Obstet* 1986; 162(3):pg256-258.
11. Mowlavi GH, Massoud J, Mobedi I et al. Enterobius Vermicularis: A controversial cause of appendicitis. *Iranian J Publ Health* 2004;33(3):pg27-31.
 12. Gordon H. Appendicealoxuriasis and appendicitis. *Arch Pathology* 1933;16 (2):177-194.
 13. Sternberg's Diagnostic Surgical Pathology. Mills SE (Ed), 5th edition, Lippincott Williams & Wilkins, Philadelphia, 2010.
 14. Odze RD, Goldblum JR, Crawford JM (Eds). *Surgical Pathology of the GI Tract, Liver, Biliary Tract and Pancreas*. 1st eds. Saunders: An imprint of Elsevier 2004.
 15. Fink AS, Kosakowski C, Hiatt JR, Cochran AJ. Periappendicitis is a significant clinical finding. *American J Surg* 1990; 159:564-568.
 16. MadoK, Mazaki T, Henmi A, Masuda H, Takayama T. Xanthogranulomatous appendicitis. *Indian J Surg* 2013; 75 : 405-6
 17. Birch PJ, Richmond I, Bennett MK. Xanthogranulomatous appendicitis. *Histopathology* 1993; 22: 597-598.
 18. Collins DC. 71,000 human appendix specimens. A final report summarizing 40 years study. *Am J. Proctol* 1963; 14: 365-381.

How to cite this article: Kulkarni MP, Sulhyan KR, Barodawala SM et al. Histopathological study of lesions of the appendix. *Int J Health Sci Res.* 2017; 7(4):90-95.
