

Case Report

Osteosarcoma in Pregnancy - A Rare Case Report

Dr. Vinu Choudhary¹, Dr. Romana Maldar²¹Senior Resident, Dept of Obs&Gynae., Sawai Man Singh Medical (SMS) College & Hospital, Jaipur, Rajasthan²Associate Professor, Dept. of Obs&Gynae., J.N. Medical College, Belgavi, Karnataka

Corresponding Author: Dr. Vinu Choudhary

Received: 03/02/2017

Revised: 22/02/2017

Accepted: 28/02/2017

ABSTRACT

We are presenting a rare case of osteosarcoma in pregnancy who presented to OPD with the complaint of swelling in left knee joint since one month. A provisional diagnosis of primigravida 35 weeks period of gestation with? cellulitis of left thigh ? Osteoarthritis of left knee joint was made. X ray left of femur(AP, lateral)- fracture distal shaft of left femur. MRI of left leg - neoplastic etiology, high grade juxtacortical osteosarcoma of distal shaft of left femur. A final diagnosis of primigravida 35 weeks period of gestation with osteosarcoma of left lower end of femur was framed. Patient was taken up for elective preterm LSCS on 24-11-15 and delivered female child, 2.2 kg. Bone biopsy of the lesion was also taken in same sitting. Histopathology confirmed the diagnosis of osteosarcoma. Patient underwent amputation above mid left thigh on 8 December 2016.

Keywords- Osteosarcoma, pregnancy, MRI, caesarean section, amputation, chemotherapy.

CASE REPORT

A 22 years old, primigravida, with 8 months of amenorrhoea appreciating fetal movements well, presented to OPD with the complaint of swelling in left knee joint since one month which gradually extended till mid thigh associated with restriction of mobility of left lower limb. No history of trauma was given .She also gave history of on and off fever since 15 days. Menstrual history- LMP-23/3/15, EDD- 28/12/15, past cycles- 4 days/30 days/ regular. Past history and family history- not significant. General physical examination-PR- 94/min, BP-108/76 mm/hg, afebrile, uterus-34 weeks, cephalic, relaxed, Fetal heart sound 154 bpm and regular. Local examination of left leg- swelling of left knee joint extending till mid thigh, restriction of mobility of knee joint, diffuse in nature, firm in consistency, congestion present, local temperature raised, tenderness present. A provisional diagnosis

of primigravida 35 weeks period of gestation with? cellulitis of left thigh? Osteoarthritis of left knee joint was made. Investigations -Hb- 10.8 gm/dl, TLC-14,800/cumm, Platelet count- 3,15000,PS-normocytic hypochromic anaemia with neutrophilic leucocytosis, alkaline phosphatase- 736U/ml, uric acid-3.8 mg/dl, urea-14 mg/dl, serum creatinine- 0.8 mg/dl. X ray left of femur(AP, lateral)- fracture distal shaft of left femur.MRI of left leg - neoplastic etiology, high grade juxtacortical osteosarcoma of distal shaft of left femur. Transabdominal scan was done for growth - AC -28 cm (73%), BPD-16 cm(78%), HC-30 cm(86%), FL-6 cm(80%), placenta – anterior and expected fetal weight- 2.1kg on Hadlock. A final diagnosis of primigravida 35 weeks period of gestation with osteosarcoma of left lower end of femur was made. Oncosurgery opinion was seeked and bone biopsy of the involved area followed

by amputation and chemotherapy was suggested. So, the plan of management involved termination of pregnancy after giving antenatal steroids for lung maturity. Patient was taken up for elective preterm LSCS on 24-11-15 and delivered female child, 2.2 kg. Bone biopsy of the lesion was also taken in same sitting. Histopathology confirmed the diagnosis of osteosarcoma. Patient underwent amputation above mid left thigh on 8 December 2016. Further plan of management included post operative chemotherapy with methotrexate once patient is stabilized.

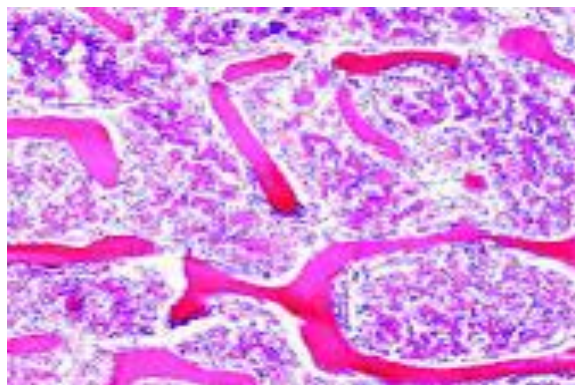


Figure 4- Histopathology of osteosarcoma showing atypical pleomorphic cells

DISCUSSION

The occurrence of malignancy during pregnancy is relatively rare with incidence of 0.07 to 0.1 % of all malignant tumours. [1] The most common malignancy during pregnancy is breast malignancy, cervical malignancy. The use of therapeutic modalities such as surgery, chemotherapy and radiation therapy for maternal health and well being has to be weighed against the potential risk to the baby. The incidence of osteosarcoma in pregnancy is not known exactly but 30 case reports have been reported till to date. Lower extremity being the most common site for tumour location in 47% followed by upper extremity in 35%, pelvis in 18%. [2] Osteosarcoma in pregnancy presents with pain in 59%, detection of mass in 47%, pathological fracture in 29 % of cases. The most common sites are the femur (42%, with 75% of tumors in the distal femur), the tibia (19%, with 80% of tumors in the proximal tibia), and the humerus (10%, with 90% of tumors in the proximal humerus). Other likely locations are the skull or jaw (8%) and the pelvis (8%). [3]

For some malignancies like osteosarcoma which are chemosensitive, a delay in therapy may affect the prognosis. A discussion regarding indicated preterm delivery should take place between physician and patient. Beta HCG is considered to be one of the markers of osteosarcoma, but since it is already raised in pregnancy, difficult to diagnose during pregnancy. Antenatally, it is known to cause

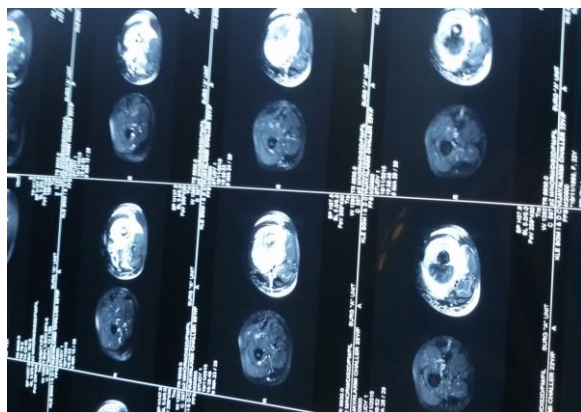
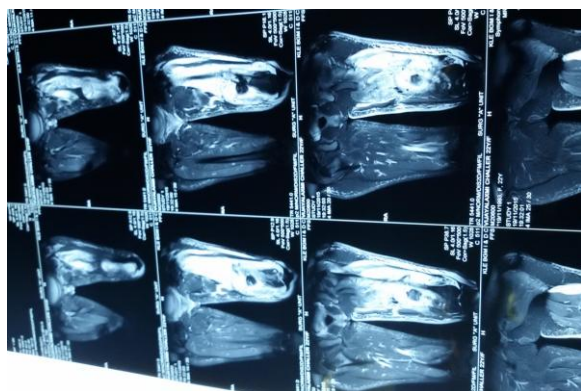



Figure 1,2&3-MRI of left leg showing juxtacortical Osteosarcoma of distal shaft of femur.

IUGR as it is known to affect placenta, but the cause is not known. In our case placenta was sent for HPR, no pathology was detected on HPR.

In case of osteosarcoma, prognosis is dependent on extent of pathological necrosis and presence of metastasis. Early delivery with administration of corticosteroids depending on gestational age may be indicated in such cases. Osteosarcoma commonly occurs in the long bones of the extremities near the metaphyseal growth plates.^[4] Osteosarcoma that has spread from the initially affected bone to one or more sites in the body, distant from the site of origin, is called metastatic. The most common site to which osteosarcoma spreads, or metastasizes, is the lungs. In the present case report chest x ray was done to look for any metastasis, report being normal. Metastatic osteosarcoma is typically difficult to control, though patients with lung metastases have a better prognosis than patients with distant metastases. It is reported that less than 20% of patients with metastatic^[5] osteosarcoma survived without

recurrence of their cancer. However, survival has improved with the development of more effective chemotherapy.

REFERENCES

1. AJCC cancer staging 5thedn Philadelphia Lippincott- Raven 1997
2. Merimsky Gestation related malignant musculoskeletal tumours Sackler faculty of medicine
3. Maxwell et al. Maternal and neonatal outcome in pregnancies complicated by bone and soft tissue tumour ACOG 2004
4. Azim H.A., Jr, Peccatori F.A., Pavlidis N. Treatment of the pregnant mother with cancer: a systematic review on the use of cytotoxic, endocrine, targeted agents and immunotherapy during pregnancy. Part I: solid tumors. *Cancer Treat Rev.* 2010;36(2):101–109.
5. Pavlidis N., Pentheroudakis G. Metastatic involvement of placenta and foetus in pregnant women with cancer. *Recent Results Cancer Res.* 2008;178:183–194.

How to cite this article: Choudhary V, Maldar R. Osteosarcoma in pregnancy - a rare case report. *Int J Health Sci Res.* 2017; 7(3):388-390.
