

Case Report

Mandibular Incisor Extraction: An Alternative Treatment Option

Dr. Nishant Negi¹, Dr. K. S. Negi²¹Lecturer, Deptt. of Orthodontics and Dentofacial Orthopedics; ²Professor, Deptt. of Orthodontics, H. P. Govt. Dental College and Hospital; Shimla, Himachal Pradesh- 171001; India

Corresponding Author: Dr. Nishant Negi

*Received: 16/01/2017**Revised: 16/02/2017**Accepted: 22/02/2017*

ABSTRACT

Mandibular incisor extraction is sometimes employed by orthodontists as an alternative treatment option in cases of Bolton discrepancy and moderate crowding. With adequate knowledge and technical acumen regarding suitability of cases for single lower incisor extraction, this alternative treatment option could be used to achieve faster results with minimal dento-facial manipulations. This case report describes single lower incisor extraction treatment along with indications, contraindications, advantages, disadvantages and special considerations involved in this treatment modality.

Key words: Lower incisor extraction, Bolton Discrepancy, Black triangles.

INTRODUCTION

The extraction of teeth to resolve crowding has been an accepted strategy for decades. There is often debate regarding merits of an extraction versus non-extraction approach, clearly there are some patients who are not ideal candidate for either of the treatment options. In these instances mandibular incisor extraction has been advocated as the middle of the road approach between nonextraction and 4 premolar extractions where space requirement and facial esthetics do not call for greater dental movements. A few case reports have discussed this treatment modality as an alternative extraction option in cases of anterior tooth size discrepancies, crowding or to harmonize with an absent or peg shaped maxillary lateral incisor. [1-3] This case report presents a case of this unusual extraction option, describing the indications, contraindications, advantages, disadvantages, mechanics and special

precautions concerning this treatment modality.

CASE REPORT

A 13 yr old female patient reported to our clinic with complaint of irregular lower front teeth. She had Angle's class I molar relationship with crowded maxillary and mandibular arches, deep bite of 6mm and deep curve of spee [Figure 1]. There was Bolton discrepancy indicating mandibular anterior excess. She had a pleasing mild convex profile, normal nasolabial angle and mentolabial sulcus and competent lips. Cephalometric evaluation revealed skeletal Class I pattern with vertical growth tendency and retroclined incisors [Figure 2, Table 1].

Treatment objectives

Our treatment objectives included correction of crowding, deep bite, deep curve of spee and of achieving class I functional occlusion.

Table 1. Cephalometric Measurements

Sr. no.	Measurements	Pre-tt	Post-tt
1.	FMA (°)	35	36
2.	IMPA (°)	82	85
3.	SNA (°)	80	81
4.	SNB (°)	79	79
5.	ANB (°)	1	2
6.	Interincisor angle (°)	143	136
7.	Max inc to NA(mm/°)	5/19	6/22
8.	Mand inc to NB(mm/°)	5/18	6/20
9.	Steiner's S line to upper lip (mm)	-1	0
10.	Steiner's S line to lower lip (mm)	-.5	1

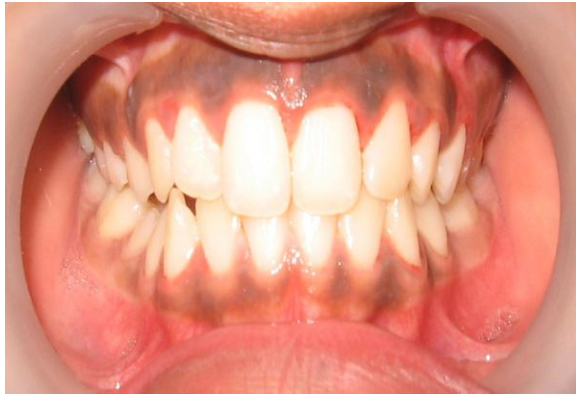

Fig 1 Pre-treatment photograph.

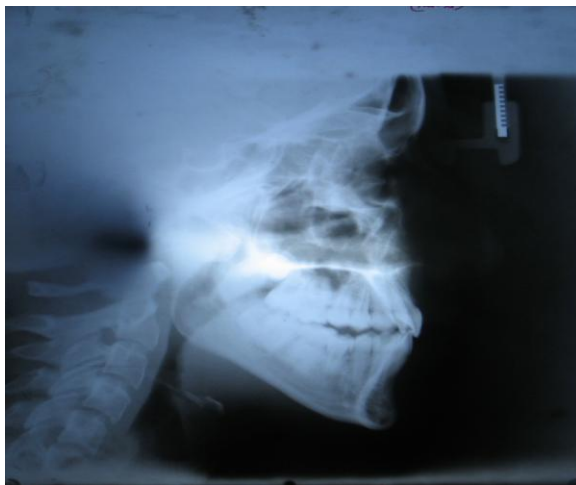

Fig 2 Pre-treatment radiograph.

Treatment alternatives

Non extraction treatment would have resulted in proclined maxillary and mandibular incisors with lip procumbency. As patient had a pleasant soft tissue profile, this treatment option was discarded.

Second treatment option involved interproximal reduction. However, significant amount of enamel reduction would have been required. This could have exposed our patient to risk of sensitivity, increased caries and poor cosmetics.

Third option of premolar extraction could have resulted in flattening of otherwise pleasant profile.

We decided to extract single mandibular incisor as our patient had around 4mm of TSAL discrepancy with Bolton's anterior tooth excess in mandibular anterior region. In addition, this option allowed us to maintain pleasing profile of our patient.

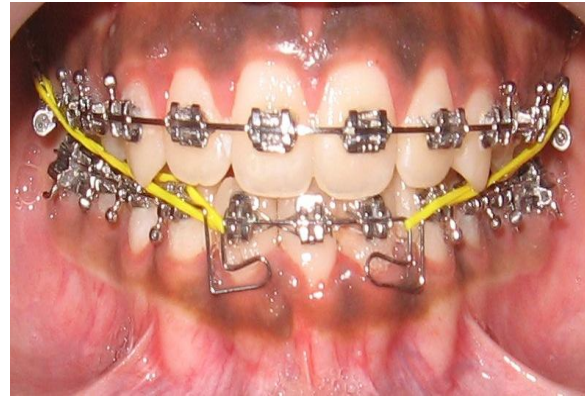


Fig 3 Stage photograph.

Treatment progress

This case was treated with pre-adjusted appliance [MBT, .022 slot]. Mandibular right central incisor was extracted. After alignment and leveling, Class III elastics were applied to L-shaped loops in .018"SS arch wire to close lower anterior space [Figure 3]. Final finishing was done using .019x025" SS archwires. After 18 months of active treatment, case was debonded and patient was given Hawley's retainer in maxillary arch and fixed retainer for mandibular arch.

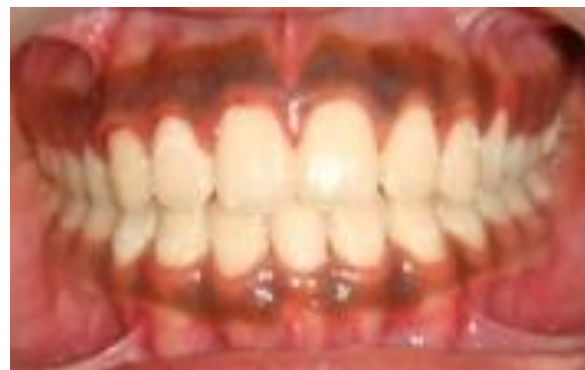

Fig 4 Post-treatment photograph.

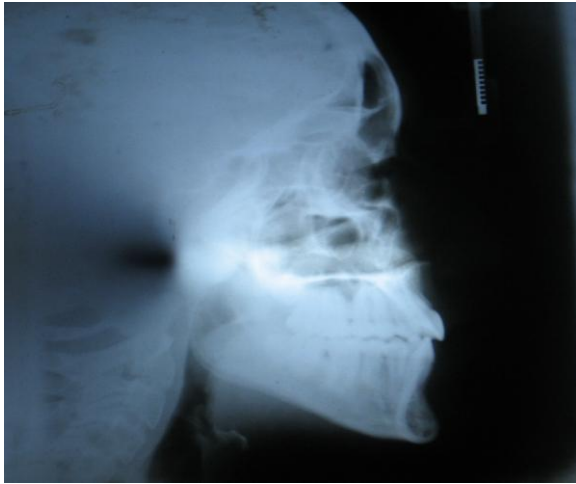

Fig 5 Post-treatment radiograph.

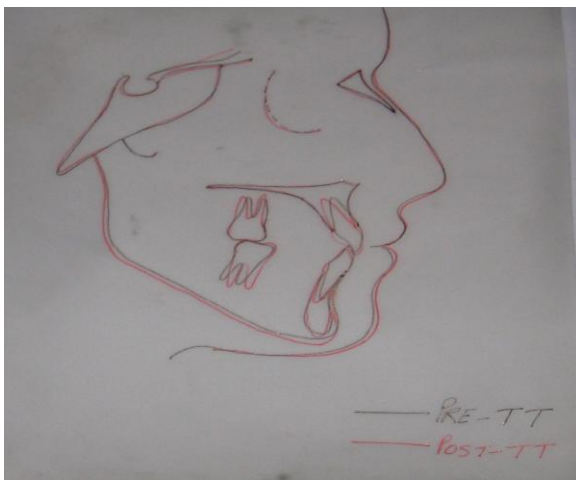


Fig 6 Cephalometric superimposition.

Treatment results

We were able to achieve Class I functional occlusion with normal overjet and overbite [Figure 4]. There was mild incisor proclination and protrusion of both lips [Fig.5, 6, Table1]. Her deep bite was resolved by proclination and relative intrusion. Her soft tissue esthetics was maintained.

DISCUSSION

Intentional extraction of a lower incisor, in carefully selected cases can enable the orthodontist to produce enhanced functional occlusal and cosmetic results with minimum orthodontic manipulations.

Indications

1. Mandibular incisor entirely excluded from the arch or severely damaged. [4]

2. Class III cases where incisors are crowded and not have to be excessively retroclined to close spaces. [5]
3. Class I and mild Class III malocclusions with mild openbite tendencies. [6]
4. Congenitally missing maxillary central incisors and presence of significant mandibular anterior crowding. [7]
5. Resolving anterior tooth-size discrepancy.

Contraindications

1. Excessive overjet and overbite- as mandibular incisor extraction can further increase overjet and overbite.
2. Mild crowding and minimal Bolton discrepancy cases which can be better managed by interproximal reduction.
3. Incisors with triangular form- as there is tendency of creation of triangular dark spaces on space closure. [8]

Advantages

Single incisor extraction may allow practitioner to use simpler mechanics with minimum orthodontic movements and reduced treatment time. In addition, it may satisfy the requirements of maintaining arch form without expansion of intercanine width. [9]

Disadvantages

1. There is tendency to develop deep bite and disturbed buccal occlusion.
2. In absence of Bolton discrepancy, closure of incisor space will result in increased overjet. [2]
3. Extraction site may reopen over the long-term.
4. There are chances of development of open gingival embrasures or “black triangles”.

Special considerations

1. It is advisable to use Bolton index or other guides like Neff coefficient to determine maxillary to mandibular tooth size discrepancies. These in conjunction with TSALD, will indicate whether removal of large lateral incisor or smaller central incisor is indicated. Incisors closest to crowding, farther

outside the natural arch, severely rotated or ankylosed is usually the best candidate for extraction.

2. A careful and realistic diagnostic setup can be an important aid in determining whether the occlusal result would be an acceptable and consistent with the treatment objectives. It can also demonstrate the amount of interproximal enamel that might be removed from the upper incisors, if that is to be considered.
3. Indiscriminate inter-proximal reduction can result in sensitivity, caries and longer contacts affecting esthetics.
4. Efforts should be made to reduce the appearance of black triangles, which are considered as the most common esthetic complications in cases involving mandibular incisor extraction. [10] It occurs mainly in regions that present thin gingiva and bone loss in interproximal contact, triangular shaped incisors, roots with divergent orientation and presence of periodontal diseases. This risk can be reduced by limiting the distance from the crestal bone to the contact area to less than 5mm. It can be accomplished by converging the roots, slenderization followed by translation of incisors and composite or veneers build ups.
5. Care should be taken to prevent excessive tipping of adjacent incisors into the extraction space. [2]
6. Every effort should be made to achieve canine rise or posterior group function on working side, and an absence of cuspal interference on non-working side.
7. Excessive overjet may be managed either by maxillary anterior width reduction, or by retroclination of

maxillary incisors and proclination of mandibular incisors.

Conflicting Interest (If present, give more details):none.

REFERENCES

1. Bayrom M, Ozer M. mandibular incisor extraction treatment of a Class I malocclusion with Bolton discrepancy: A case report. *Eur J Dent* 2007;1:54-59.
2. Uribe F, Nanda R. Considerations in mandibular incisor extraction cases. *J ClinOrthod* 2009;43:45-51.
3. Simao TM, Valladares-Neto J, Rino-Neto J, de Poiva JB. Iatrogenic absence of maxillary canine: Bolton discrepancy treated with mandibular incisor extraction. *Am J OrthodDentofacOrthop* 2013;143:713-23.
4. Riedel RA, Little RM, Bui TD. Mandibular incisor extraction: Postretention evaluation of stability and relapse. *Angle Orthod* 1992;62:103-16.
5. Canut JA. Mandibular incisor extraction: indications long-term evaluation. *Eur J Orthod* 1996;18:485-9.
6. Faerovig E, Zachrisson BU. Effects of mandibular incisor extraction on anterior occlusion in adults with Class III malocclusion and reduced overbite. *Am J OrthodDentofacOrthop* 1999;115:113-24.
7. Miller RJ, Duong TT, Derakhshon M. Lower incisor extraction treatment with invisalign system. *J ClinOrthod* 2002;36:95-102.
8. Owen AH. Single lower incisor extractions. *J ClinOrthod* 1993;27:153-60.
9. Riedel RA. Retention and relapse. *J ClinOrthod* 1976;10:454-72.
10. Pithon MM, Santos AM, Couto FS, Freitas LMA, Coqueriro RS. Comparative evaluation of esthetic perception of black spaces in patients with mandibular incisor extraction. *Angle orthod* 2012;82:806-11.

How to cite this article: Negi N, Negi KS. Mandibular incisor extraction: an alternative treatment option. *Int J Health Sci Res.* 2017; 7(3):366-369.
