

Original Research Article

Expression Analysis of p53 and Cyclooxygenase-2 in Oral Lichen Planus

Zafar Iqbal Bhat^{1,3}, Akanksha Marwah¹, Md.Zafaryab³, Nita Khurana², Aadithya B Urs¹, Mahesh Verma¹,
Vijay Garg², A.K. Agarwal², Sunita Gupta¹, M.M.A Rizvi³

¹Maulana Azad Institute of Dental Sciences, ²Maulana Azad Medical College & LNJP Hospital,

³Genome Biology Lab. Department of Biosciences, Jamia Millia Islamia,
Department of Oral Medicine & Radiology, Maulana Azad Institute of Dental Sciences, New Delhi.

Corresponding Author: Zafar Iqbal Bhat

Received: 09/11/2016

Revised: 11/02/2017

Accepted: 17/02/2017

ABSTRACT

Background: Oral lichen planus (OLP) is a chronic inflammatory disease of unknown origin. WHO classifies OLP as a potentially malignant disorder; however, the underlying mechanisms initiating development of cancer in OLP lesions have not been understood. The p53 tumor suppressor plays an important role in many tumors and an increased expression of p53 protein has been seen in OLP lesions. Cyclooxygenase-2 (COX-2) is a key enzyme for inflammatory processes and cellular proliferation, which has also been observed to over express in this chronic inflammatory condition. The aim of this study was to find the expression of p53 and COX2 in histopathologically diagnosed specimens of OLP and to explore the possible correlation between them.

Method: This study was conducted on 60 histopathologically diagnosed cases of OLP and 10 normal oral mucosa specimens as controls. Immunohistochemistry was performed to find out the p53 and COX -2 protein expression.

Result: The expression of p53 was positive in 80% of the cases of OLP as compared to normal oral mucosa, however, COX-2 expression was positive in 83.34%. No significant correlation was found between p53 and COX-2.

Conclusion: p53 and COX-2 have shown significant increase in expression in OLP cases as compared to normal, therefore these two markers can be used for routine histopathological examination to identify OLP lesions for development of OSCC.

Keywords: COX2, Oral Lichen Planus, p53

INTRODUCTION

Oral lichen planus (OLP) is a chronic inflammatory disease of skin and mucosa ⁽¹⁾ affecting approximately 1–2% of the adult population. The disease occurs more frequently in women than in men (1.4:1) and is more common in middle aged and elderly than in young people. ⁽²⁾ Autoimmunity has been suggested as playing a role in the pathogenesis of OLP. ⁽³⁾ An association between chronic inflammation and an increased risk of malignant development is known. ⁽⁴⁻⁶⁾ WHO

classifies OLP as a “potentially malignant disorder” ⁽⁷⁻⁸⁾ with reported malignant transformation rate of 0% to 2.1%. ⁽⁹⁻¹²⁾ The transformation of normal oral mucosa to lichen planus is a complex multistep process, which requires changes in normal keratinocyte DNA replication, cell division, cell death and cell-to-cell adhesion. Hence, it is necessary to see the expression of factors whose disturbed differentiation pattern triggers the intense immune response directed against the epithelial cells seen in OLP.

p53 is an important nuclear protein which is involved in the regulation of the cell cycle. (13) Mutations in *TP53* are frequent genetic changes in OSCC as well as in other human cancers. (14-16) There are numerous studies on p53 expression in OLP, and their results vary significantly, with most of them having found an increase in expression of p53 in OLP lesions as compared with normal tissue, with reported expression percentages ranging from 0-100%. (17-24)

A protein which is directly connected to inflammation and also suggested to be involved in cancer development is cyclooxygenase-2 (COX-2). (25,26) COX-2 expression is implicated in the pathogenesis of many diseases and is also over-expressed in many tumors. (27) Several processes important for cancer development are influenced by Cox -2, such as cell proliferation, apoptosis and angiogenesis. (28-32) In OLP, an up-regulation of COX-2 expression has been found. (33-35)

The aim of this study is to find out the expression of p53 and COX-2 in histopathologically diagnosed specimens of OLP and to explore the possible correlation between them.

MATERIALS AND METHODS

Sample Collection: Patients reporting to Department of Oral Medicine and Radiology, Maulana Azad Institute of Dental Sciences, Delhi who were clinically suspected as having OLP were selected. Biopsy was performed in these patients. Formalin-fixed, paraffin-embedded sections from sixty patients who were histopathologically diagnosed as OLP, were included in the study. We also included 10 sections of normal mucosa as control. Approval from institutional ethical committee & prior informed consent was taken from all the patients.

Immunohistochemistry Staining Procedure: Immunohistochemical staining technique was performed to examine the p53 and COX2 protein expressions. 2-3 μ m thick sections of each case, clinically and

histologically diagnosed with OLP, were cut from formalin-fixed, paraffin-embedded tissue blocks and mounted on lysine coated slides for immunohistochemical staining. The sections were deparaffinized by placing the slides in oven with 56° C dry heat for 15 min and rehydrated using xylene and acetone solutions. Endogenous peroxidase activity was blocked by incubating sections in methanol containing hydrogen peroxide (0.3%, v/v) for 30 min. They were then washed in Phosphate Buffered Saline (PBS). Thereafter, antigen retrieval was carried out via a microwave in 0.01 M citrate buffer, pH 6.0, by heating the sections for 30 mins, along with intermittent cooling, followed by overnight incubation with the respective antibodies COX 2 (Genway Biotech, Inc.) and p53 (SkyTek Laboratories) at 4°C. The slides were washed with PBS and incubated with secondary followed by tertiary antibody, each for 30 mins and again washed with PBS. Diaminobenzidine (DAB) was applied to the sections and washed with distilled water after 5-7 minutes. Finally, the slides were counter stained with hematoxylin and mounted with D.P.X. mountant.

Breast cancer tissue as a positive control for p53 and Colon carcinoma tissue as a positive control for COX 2 were included in each experiment.

Assessment of immunohistochemical Results: Brown nuclear staining for p53 and cytoplasmic staining for COX2 was considered as positive.

A quantitative analysis for evaluation of expression of p53 and COX 2 was done using an extent score based on the percentage of positively stained cells (Table 1)

Statistical Analysis: Statistical analysis was performed by using SPSS (statistical package for social sciences), version 19.0 for windows.

Pearson correlation coefficient of correlation (r), χ^2 test and Fischer's exact test was used to find the expression of these markers as well as the co-relation between

the two markers, and p-value <0.005 was considered as significant.

RESULTS

Patient Characteristics: 60 patients with OLP were included in the study (Group 1) along with 10 healthy controls (Group 2). The mean age of group 1 was 46.7 years with a standard deviation of 12.632, and that of group 2 was 51.3 years with a standard deviation of 14.275 (Table 2).

p53 and COX-2 Expression: Immunohistochemical analysis of p53 protein revealed a significant increase in its expression (overall positivity included nuclear staining) in OLP cases. In histologically normal oral tissues, very mild detectable nuclear staining for p53 was observed. p53 expression was indicated as brown nuclear staining predominantly more in the basal layer (Figure 2). Significant increase in p53 expression was observed in OLP cases (Figure 1), and it was found to be statistically significant with P-value <0.05. Maximum number of cases staining positive fell under extent score 1 (1-25%) (Table3). For OLP cases, p53 immunoreactivity was

observed in 80 % (48/60) cases (Mean Av. stained cells= 7.94%) (Table 5). Significant increase in COX2 expression (overall positivity included cytoplasmic staining) was observed in OLP cases, wherein COX 2 expression was observed in inflammatory cells and endothelial cells. The maximum number of cases staining positive fell under the extent score 3 and 4 (i.e. 51-100%) (Table 4). COX 2 over-expression was observed in 83.34% (50/60) of the OLP cases (Mean Av. stained cells= 45.21%) (Table5). Staining was predominantly observed in suprabasal layer of the epidermis. In some sections, inflammatory cells in the dermis and endothelial cells lining the blood vessels also showed positive expression (Figure 4).

However, the correlation between these two markers was found statistically non significant (Table 6).

Table 1: Staining extent score chart for immunohistochemical analysis

Percentage of positive cells stained	Extent score
0%	0
1-25%	1
26-50%	2
51-75%	3
76-100%	4

Table 2: Patient Characteristics

	Total no.	Mean Age	Male	Female
Group 1	60	46.7±12.632	45.0% (27)	55.0% (33)
Group 2	10	51.30±14.275	50% (5)	50% (5)
Total Count	70		45.71% (32)	54.28% (38)

Table 3: Percentage of positively stained cells for p53, categorized according to the extent score for Groups 1 & 2

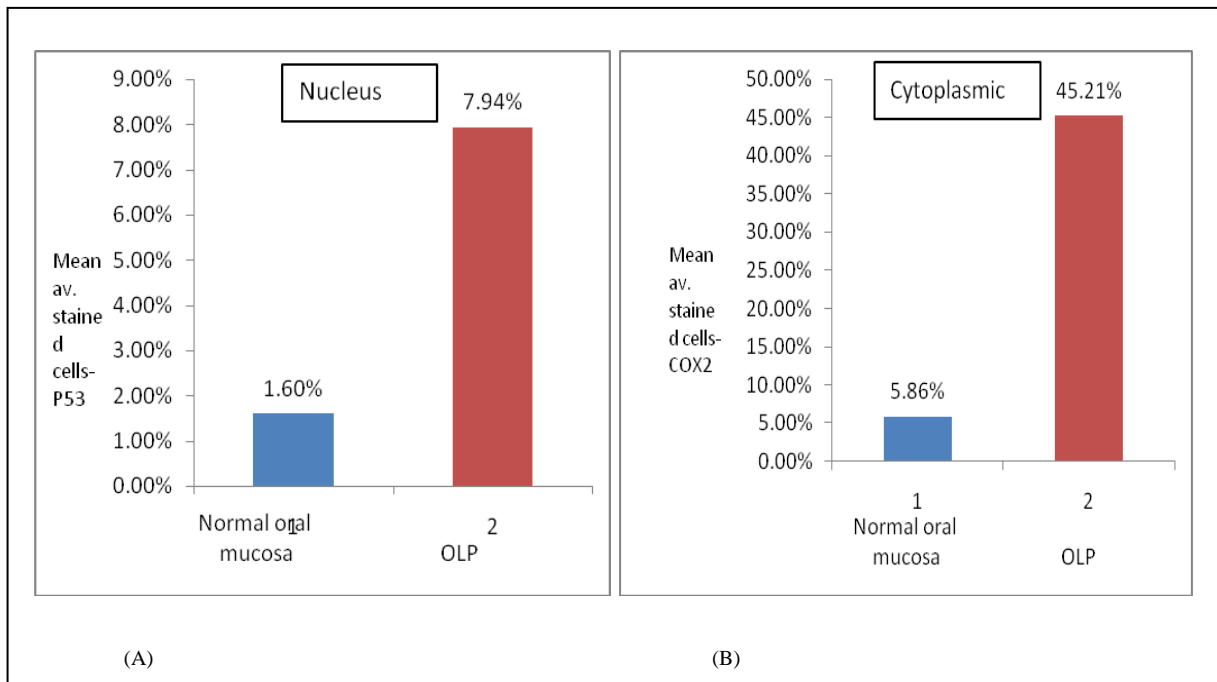
Marker	Extent Score	Percentage (No. of Cases)		Total
		Group 1	Group 2	
P53	0	28.34% (17)	70.0 % (7)	34.285% (24)
	1	68.34% (41)	30 % (3)	62.85 % (44)
	2	3.34% (2)	0 % (0)	2.85 % (2)
	3	0%(0)	0 % (0)	0 % (0)
	4	0% (0)	0 % (0)	0 % (0)

Table 4: Percentage of positively stained cells for COX 2, categorized according to the extent score for Groups 1 & 2

Marker	Extent Score	Percentage (No. of slides)		Total
		Group 1	Group 2	
COX2	0	16.67%(10)	60.0 % (6)	22.85 % (16)
	1	16.67 % (10)	30 % (3)	18.57 % (13)
	2	15.0 % (9)	10 % (1)	14.285 % (10)
	3	25.0% (15)	0 % (0)	21.42 % (15)
	4	26.67%(16)	0 % (0)	22.85 % (16)

Table 5: Mean av. stained cells for p53 and COX 2 expression and their comparison in OLP and normal oral mucosa

	P53	COX-2
No. of cases studied	60	60
Positive criteria for immunohistochemical staining	Nucleus	Cytoplasm
No. of cases showing positive expression	Nuc.= 80% (48/60)	Cyt.=83.34% (50/60)
Mean av. stained cells:	OLP-	Nuc.= 7.94%
	Normal oral mucosa-	Cyt.= 45.21%
P-value	Nuc.= 1.6%	Cyt.= 5.86%
	0.01	0.01



Bar graph representing a comparison of the mean av. stained cells between normal oral mucosa & OLIP for the expression of (A) p53 (B) COX 2

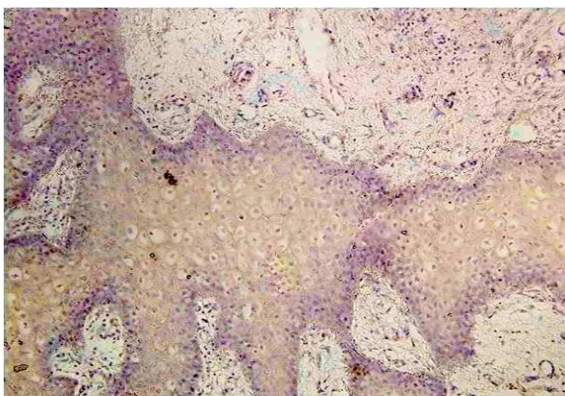


FIG. 1

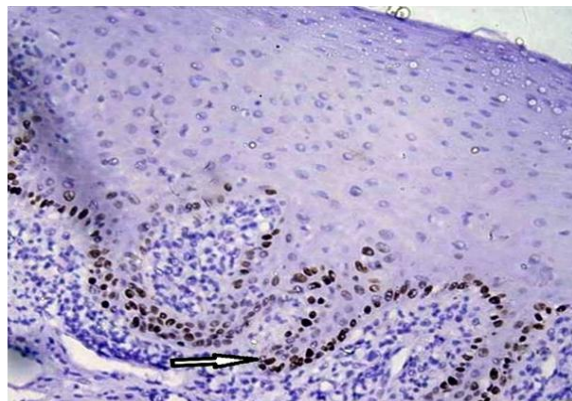


FIG. 2

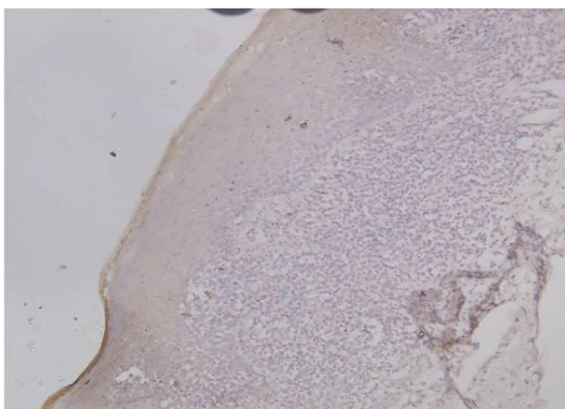


FIG.3

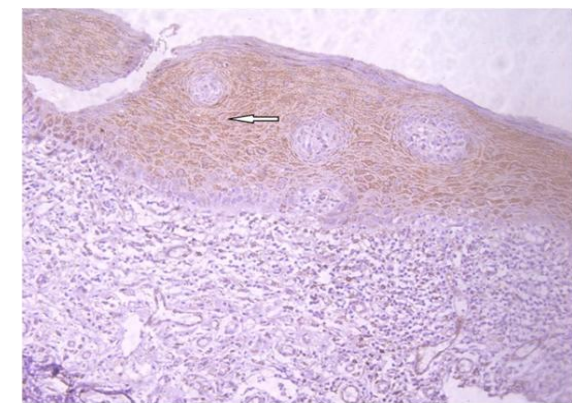


FIG. 4

Fig 1: Microphotograph depicting negative p53 expression in normal oral mucosa as done by immunohistochemical staining

Fig 2: Microphotograph depicting strong p53 nuclear positivity as observed predominantly in the basal layer in OLIP. Immunohistochemical staining showed a strong brown staining in the nucleus.

Fig 3: Microphotograph showing immunohistochemical staining to check COX 2 expression in normal oral mucosa which showed brown staining observed only in inflammatory and endothelial cells.

Fig 4: Microphotograph showing Cytoplasmic expression of COX 2 protein as determined by immunohistochemical analysis, which was observed mostly in the suprabasal layers of the epidermis.

Table 6: Non-significant correlation between the expression of p53 and COX 2 was observed.

		P53	COX2
P53	Pearson Correlation	1	.135
	Sig. (2-tailed)	.	.349
	N	50	50
COX2	Pearson Correlation	.135	1
	Sig. (2-tailed)	.349	.
	N	50	50

DISCUSSION

There are numerous studies concerning OLP, but the exact cause and pathogenesis of the disease is still unclear. Autoimmunity is suggested to play a part in the pathobiology of OLP involving auto cytotoxic T- cells. One of the hallmarks of OLP is the sub-epithelial chronic inflammation, and chronic inflammation is known to be connected to increased risk of malignant transformation. (4-6) Malignant transformation of OLP has, however, been a question of controversy. Development of epithelial dysplasias and OSCC in patients with OLP lesions, illustrates the need to investigate potential risk markers in OLP patients. Numerous attempts have been performed to identify such markers, but so far no significant objective marker has fulfilled the premises.

To analyze the malignant potential of potentially malignant disorder such as those in OLP, it is important to consider that oncogene activation and inactivation of tumor suppressor genes which occur precociously in carcinogenesis. (23)

P53 is a tumor suppressor gene, whose activity stops the formation of tumors. Alteration in p53 expression and/or absence of activity of wild-type. p53 has important roles in cancer development in humans. (36,37) p53 induction by mediators of inflammation may primarily induce a growth suppressive response that contributes to preserve cell viability and genetic integrity, suggesting that p53 may act as an important homeostatic factor during inflammation. (38) The presence of TP53 mutations during inflammation results in p53-dependent growth suppression, thus providing a selective advantage for clonal

expansion to cells that have acquired a mutation in TP53. (39) The immuno-histochemical detection of p53 and the mechanism underlying p53 over-expression in OLP is also subject to controversy. (40) However the expressions of p53 and active proliferation status in OLP have been reported. (18) It is estimated that p53 over-expression constitutes a form of cell response to the hyper-proliferative state frequently seen in OLP. (41,42) Previous investigations of p53 expression in OLP have been inconclusive, from reporting no expression to getting a positive expression in up to 91% of the lesions. (20,21,23) These anomalies could represent early steps in cancer development. Previous studies have reported that changes in expression of p53 due to various factors such as DNA damage also affects the expression of some inflammatory products, COX2 being one of them.

The expression of the COX-2 enzyme is a normal physiological event in inflammatory processes, and is involved in tissue repair by promoting angiogenesis, proliferation, and cell differentiation, however, this could have a negative effect, such as development of cancer, when inflammation is chronic as occurs in OLP. (34)

Previous studies by Han *et al.*, (43) have concluded that induction of p53 or DNA damage leads to the expression of COX 2 in a p53-dependent manner. P53-mediated COX 2 induction promotes cell survival in response to p53 or DNA damage which suggests that COX 2 favors the cellular outcome of survival over apoptosis in response to p53. This result demonstrates that COX-2 counteracts p53-mediated apoptosis. On the other hand, a study done by Subbaramaiah *et al.*, (44) was the first study describing the negative regulatory effect that p53 has on COX-2 expression and suggested that p53 in its wild form represses COX-2 by interfering with its transcription.

In this study, we screened 60 of the OLP biopsies for p53 expression. About

80% of the OLP specimens (48/60) stained positive for nuclear p53 with percentage of positively stained cells ranging from 1-50%, which is in agreement with the study of Taniguchi *et al.* (20) Very mild expression of p53 was seen in normal oral mucosa thus confirming the fact that mutant form of p53 is indeed over-expressed in OLP cases. Baweja *et al.*, (45) was reported that a strong expression of mutant form of p53 correlated with a greater risk of malignant transformation of potentially malignant lesions. Many other studies have also reconfirmed the same. (46-51) Thus patients with a significant increase in expression of this protein should be on a long term follow up due to the risk of the OLP lesions undergoing malignant transformation.

However, the results of COX-2 have revealed positive expression in 83.34% of the investigated OLP cases in basal and Para-basal cell layers. Similarly, a varying degree of COX-2 expression was observed in inflammatory cells in the dermis and endothelial cells lining the blood vessels, in most of the cases which is in concordance with other studies. (33,34) Studies on squamous cell carcinoma of the head and neck have revealed elevated expression of COX-2 as well as in cancers of other organs with negative expression in normal oral mucosa. (28,32,35,52) The presence of COX-2 may indicate a biological function in chronic inflammation and potential cancer development in OLP lesions, which supports the suggested link between chronic inflammation and the development of oral squamous cell carcinoma in OLP, and thus COX-2 can be one of the potential predictive factor for the risk of cancer development in OLP.

The correlation between p53 and COX2 expressions, the present finding showed a non significant correlation, however further studies with larger samples are needed to find out the relation between these two markers. Emanuela *et al.*, stated that the correlation between TP53 mutation status and levels of COX 2 expression is highly variable (38) with some of the studies

showing a positive correlation with wild type or mutant TP53, while some showing no co-relation at all. Various reasons proposed for such discrepant results depend on tumor site and histology and also upon the transcriptional mechanism responsible for COX-2 promoter activation. Hence, although a close relationship between the expressions of p53 and COX 2 has been reported in several studies, it remains unknown as to why no co-relation was observed in this study. This may suggest the possibility of tissue-specific modulation of COX-2 gene regulation.

As a conclusion, in this study a significant increase in expression of p53 and COX 2 in OLP cases has been observed as compared to normal oral mucosa, which can, therefore be used as significant sensitive markers to select OLP lesions at risk for development of OSCC. However the patient material is limited with respect to further development of epithelial dysplasia and OSCC, so additional studies on larger patient material along with a long term follow up is necessary to further validate the clinical value of these markers.

ACKNOWLEDGMENTS

The author wishes to acknowledge University Grants Commission for financial support and Mr. Rajesh Ahuja is also acknowledged.

Ethical Approval

Approval from institutional ethical committee was taken and the procedures performed were in accord with the ethical standards of the committee on human experimentation of the institution. Prior informed consent was taken from all the patients.

Conflicting Interest: Nil

REFERENCES

1. Dissemmond J. Oral lichen planus: an overview. *J Dermatol Treat.* 2004; 15:136–140.
2. Axell T., Rundquist L. Oral lichen planus – a demographic study. *Community Dent Oral Epidemiol.* 1987;15:52–56.
3. Sugerma P.B., Savage N.W. Oral lichen planus: causes, diagnosis and

- management. Aust Dent J. 2002;47:290–297.
4. Clevers H. At the crossroads of inflammation and cancer. Cell. 2004;118:671-674.
 5. Coussens LM, Werb Z. Inflammation and cancer. Nature. 2002; 420:860-867.
 6. Philip M, Rowley DA, Schreiber H. Inflammation as a tumor promoter in cancer induction. Semin Cancer Biol. 2004; 14:433-439.
 7. Pindborg J.J.R.P., Smith C.J., Van der Waal. World Health Organization international histological classification of tumours. Histological typing of cancer and precancer of the oral mucosa. 2nd ed. Springer; Berlin.1997
 8. S. Warnakulasuriya, N. W. Johnson, and I. Van Der Waal, “Nomenclature and classification of potentially malignant disorders of the oral mucosa,” Journal of Oral Pathology and Medicine. 2007;36: 575–580.
 9. Torrente-Castells E, Figueiredo R, Berini-Aytés L, Gay-Escoda C. Clinical features of oral lichen planus. A retrospective study of 65 cases. Med Oral Patol Oral Cir Bucal.2010; 15:685–90.
 10. Van der Meij EH, Mast H, van der Waal I. The possible premalignant character of oral lichen planus and oral lichenoid lesions: A prospective five-year follow-up study of 192 patients. Oral Oncol. 2007;43:742–8.
 11. Ingafou M, Leao JC, Porter SR, Scully C. Oral lichen planus: a retrospective study of 690 British patients. Oral Dis. 2006; 12:463–8.
 12. Hsue SS, Wang WC, Chen CH, Lin CC, Chen YK, Lin LM. Malignant transformation in 1458 patients with potentially malignant oral mucosal disorders: a follow-up study based in a Taiwanese hospital. J Oral Pathol Med. 2007; 36:25–29.
 13. Vousden KH, Prives C. 2009. Blinded by the Light: The Growing Complexity of p53. Cell; 137:413-431.
 14. Bertram JS. The molecular biology of cancer. Mol Aspects Med. 2000;21:167-223.
 15. Nylander K, Dabelsteen E, Hall PA. The p53 molecule and its prognostic role in squamous cell carcinomas of the head and neck. J Oral Pathol Med .2000;29:413-25.
 16. M. Gasco and Crook T. The p53 network in head and neck cancer. Oral Oncology 2003; 39:222–231.
 17. Dekker NP, Lozada-Nur F, Lagenaur LA, MacPhail LA, Bloom CY, Regezi JA. Apoptosis-associated markers in oral lichen planus. J Oral Pathol Med. 1997; 26:170-175.
 18. Schifter M, Jones AM, Walker DM: Epithelial p53 gene expression and mutational analysis, combined with growth fraction assessment, in oral lichen planus. J Oral Pathol Med. 1998;27:318-324
 19. Hirota M, Ito T, Okudela K, Kawabe R, Yazawa T, Hayashi H, Nakatani Y, Fujita K, Kitamura H. Cell proliferation activity and the expression of cell cycle regulatory
 20. Taniguchi Y, Nagao T, Maeda H, Kameyama Y, Warnakulasuriya KA. Epithelial cell proliferation in oral lichen planus. Cell Prolif 2002;35:103-109.
 21. Lee JJ, Kuo MY, Cheng SJ, Chiang CP, Jeng JH, Chang HH, Kuo YS, Lan WH, Kok SH. Higher expressions of p53 and proliferating cell nuclear antigen (PCNA) in atrophic oral lichen planus and patients with areca quid chewing. Oral Surg Oral Med Oral Pathol Oral Radiol Endod. 2005;99:471-478.
 22. Ebrahimi M, Wahlin YB, Coates PJ, Sjostrom B, Nylander K. Decreased expression of p63 in oral lichen planus and graft-vs.-host disease associated with oral inflammation. J Oral Pathol Med. 2006;35:46-50.
 23. Acay RR, Felizzola CR, de Araujo N, De Sousa S. Evaluation of proliferative potential in oral lichen planus and oral lichenoid lesions using immunohistochemical expression of p53 and Ki67. Oral Oncol. 2006;42:475-480.
 24. Gonzalez-Moles MA, Scully C, Gil-Montoya JA. Oral lichen planus: controversies surrounding malignant transformation. Oral Dis. 2008;14:229-243.
 25. Rajakariar R, Yaqoob MM, Gilroy DW: COX-2 in inflammation and resolution. Mol Interv. 2006;6:199-207.

26. De Moraes E, Dar NA, de Moura Gallo CV, Hainaut P. Cross-talks between cyclooxygenase-2 and tumor suppressor protein p53: Balancing life and death during inflammatory stress and carcinogenesis. *Int J Cancer*. 2007;121:929-937.
27. Wang MT, Honn KV, Nie D. Cyclooxygenases, prostanooids, and tumor progression. *Cancer Metastasis Rev*. 2007;26:525-534.
28. Lin DT, Subbaramaiah K, Shah JP, Dannenberg AJ, Boyle JO. Cyclooxygenase-2: a novel molecular target for the prevention and treatment of head and neck cancer. *Head Neck*. 2002; 24:792-799.
29. Prescott SM, Fitzpatrick FA: Cyclooxygenase-2 and carcinogenesis. *Biochim Biophys Acta*. 2000;1470:69-78.
30. Sun Y, Tang XM, Half E, Kuo Boldrup L, Coates PJ, Hedberg Y, Sjostrom B, Dahlqvist A, Nylander K. Expression of p63, COX-2, EGFR and beta-catenin in smokers and patients with squamous cell carcinoma of the head and neck reveal variations in non-neoplastic tissue and no obvious changes in smokers. *Int J Oncol*. 2005; 27:1661-1667.
31. Tsujii M, DuBois RN. Alterations in cellular adhesion and apoptosis in epithelial cells overexpressing prostaglandin endoperoxide synthase. *Cell*. 1995;83:493-501.
32. van der Woude CJ, Kleibeuker JH, Jansen PL, Moshage H. Chronic inflammation, apoptosis and (pre-) malignant lesions in the gastro-intestinal tract. *Apoptosis*. 2004; 9:123-130.
33. Sun Y, Tang XM, Half E, Kuo MT, Sinicropo FA. Cyclooxygenase-2 overexpression reduces apoptotic susceptibility by inhibiting the cytochrome c-dependent apoptotic pathway in human colon cancer cells. *Cancer Res*. 2002; 62:6323-6328.
34. Neppelberg E, Johannessen AC. DNA content, Cyclooxygenase-2 expression and loss of E-cadherin expression do not predict risk of malignant transformation in oral lichen planus. *Eur Arch Otorhinolaryngol*. 2007; 264:1223-1230
35. Lysitsa S, Samson J, Gerber-Wicht C, Lang U, Lombardi TCOX-2 expression in oral lichen planus. *Dermatology*. 2008; 217:150-155.
36. Hainaut P, Hollstein M. p53 and human cancer: the first ten thousand mutations. *Adv Cancer Res* 2000;77:81-137.
37. Olivier M, Eeles R, Hollstein M, Khan MA, Harris CC, Hainaut P. The IARC TP53 database: new online mutation analysis and recommendations to users. *Hum Mutat* 2002;19:607-14.
38. Nazir Ahmad Dar, Claudia Vitoria de Moura Gallo and Pierre Hainaut Emanuela de Moraes. Cross-talks between cyclooxygenase-2 and tumor suppressor protein p53: Balancing life and death during inflammatory stress and carcinogenesis. *Int. J. Cancer* 2007;121:929-937.
39. Yamanishi Y, Boyle DL, Rosengren S, Green DR, Zvaifler NJ, Firestein GS. Regional analysis of p53 mutations in rheumatoid arthritis synovium. *Proc Natl Acad Sci USA* 2002;99:10025-30.
40. Hosseini F, Khalili M, Rohani B. Immunohistochemistry Analysis of P53 and Ki-67 Proteins in Oral Lichen Planus and Normal Oral Mucosa. *Iranian J Publ Health*.2009;38:37-43.
41. Gonzalez-Moles MA, Gil-Montoya JA, Ruiz-Avila I, Esteban F, Bascones-Martines A. Differences in the expression of p53 protein in oral lichen planus based on the use of monoclonal antibodies Do7 and pAb 240. *Oral Oncology*. 2008; 44:496-503.
42. Crosthwaite N, Teale D, Franklin C, Foster GA, Stringer BM. p53 protein expression in malignant, premalignant and non-malignant lesions of the lip. *J Clin Pathol*. 1996;49:648-53.
43. Han JA, Kim JI, Ongusaha PP, et al. P53-mediated induction of COX-2 counteracts p53- or genotoxic stress-induced apoptosis. *EMBO J*. 2002;21:35 - 44
44. Subbaramaiah K, Altorki N, Chung WJ, Mestre JR, Sampat A, Dannenberg AJ. Inhibition of cyclooxygenase-2 gene expression by p53. *J Biol Chem*.1999;274: 10911-5.
45. Pankaj Baweja, Vidya Monappa, Geetha Krishnanand. P53 immunohistochemical staining patterns

- in benign, premalignant and malignant lesions of the oral cavity: A study of 68 cases. *J Interdiscipl Histopathol.* 2013;1: 113-120
46. Ogden GR, Kiddie RA, Lunny DP, Lane DP. Assessment of p53 protein expression in normal, benign and malignant oral mucosa. *J Pathol.* 1992;166:389-394.
47. Field JK, Spandis DA, Malliri A, Gosney JR, Yiagnosis M, Stell PM. Elevated p53 expression correlates with a history of heavy smoking in squamous cell carcinoma of the head and neck. *Br J cancer.* 1991;64:573-577.
48. Langdon JD, Partridge M. Expression of the tumour suppressor gene p53 in oral cancer. *Br J Oral Maxillofac Surg.* 1992;30:214-220.
49. Boyle JO, Hakim J, Koch W, Riet PVD, Hruban RH, Roa RA, et al. The incidence of p53 mutations increases with progression of head and neck cancer. *Cancer Res.* 1993;53: 4477-4480.
50. Nylander K, Stenling R, Gustafsson H, Zackrisson B, Roos G. p53 expression and cell proliferation in squamous cell carcinoma of the head and neck. *Cancer.* 1995;75:87-93.
51. Xie X, Clausen OPF, Angelis PD, Boysen M. The prognostic value of spontaneous apoptosis, bax, bcl-2, and p53 in oral squamous cell carcinoma of the tongue. *Cancer.* 1999; 86:913-920.
52. Se Min Jang, Young Jin Jun, Woong N. Clinicopathologic significance of cyclooxygenase-2 over expression in colorectal adenocarcinoma. *Basic and applied Pathology.* 2010; 3:14-20.

How to cite this article: Bhat ZI, Marwah A, Md. Zafaryab et al. Expression analysis of p53 and cyclooxygenase-2 in oral lichen planus. *Int J Health Sci Res.* 2017; 7(3):126-134.
