

Case Report

## Pediatric Graves' Disease: A Case Report

Badi Alenazi , Ahmed Alanazi, Abdullah Alshaya, Sharifah Al Duraibi, Ayman Mousa,  
Tariq Aseifan, Samiah Alenazi

Pediatric Department in Al Yammamah Hospital, Riyadh, Saudi Arabia

Corresponding Author: Badi Alenazi  
Email: Badi1300@gmail.com

### ABSTRACT

Graves' disease (GD) is the most common cause of hyperthyroidism in children. Antithyroid drugs (ATD) are recommended as the initial treatment, but the major concern is the high relapse rate (30%) as remission is achieved after a first course of ATD. Alternative treatments, such as radioactive iodine or thyroidectomy, are considered in cases of relapse, lack of compliance, or ATD toxicity. Here we present a case report of 4 years old Saudi girl who presented with neck swelling tremor, nervousness, protrusion of both eyes and sleep disturbances. She diagnosed as Graves' disease and started on carbimazole treatment.

**Key words:** Hyperthyroidism, Graves disease, Thyroid, Methimazole, Propylthiouracil, Radioactive iodine.

### INTRODUCTION

Hyperthyroidism is a rare but serious disease in childhood. <sup>(1)</sup> The most common cause is Graves' disease (GD), an autoimmune disorder resulting from thyrotropin (TSH) receptor stimulation by autoantibodies. Other causes include Acute or subacute thyroiditis, chronic lymphocytic thyroiditis, administration of thyroid hormones and/or iodides, McCune-Albright syndrome, TSH-secreting pituitary tumors and Thyroid hormone resistance. <sup>(2)</sup> Here we present classical case of graves' disease in young girl with literature review.

### CASE REPORT

A 4 years old girl presented to pediatric endocrine outpatient clinic with history of weight loss, bilateral eyes protrusion for 6 months. There is of nervousness, increase in the appetite, and sleep disturbance, palpitation, diarrhea, sweating and tremor for 3 months prior to presentation. The mother noticed swelling in

the middle of child neck. It was started gradually not associated with pain or difficult in swallowing. No history of muscle pain, weakness, hair loss, shortness of breath, skin rash or depression. Patient was not on medication. There is no past medical and surgical history. Vaccination was up to date. Developmental parameters were appropriate for age. She was on family diet with average appetite. No consanguinity between parents. She has 3 other sibling all live and healthy. There is strong family history of thyroid disease. Patient's grandfather had benign thyroid cancer treated by thyroidectomy and radiation therapy, her aunt had benign thyroid cancer treated by thyroidectomy. Her grandmother and her uncle had hyperthyroidism. On examination, he was not dysmorphic, weight, height were at 25<sup>th</sup>, 25<sup>rd</sup> percentile respectively. The patient had a heart rate of 109 beats per minute. Blood pressure of 108/65 mm Hg. Hand examination revealed fine tremor and sweating, Eye examination

reveled significant exophthalmos. (Figure1). There is diffuse non tender midline swelling move with swallowing and not move with protruding tongue, not extent to upper chest. No bruit on auscultation (Figure 2).

Examination of chest showed equal air entry with no added sound. Cardiac examination was unremarkable. There was no hepatosplenomegaly, no skin changes. Child had normal muscle tone and power. Child can walk. Musculoskeletal examination was unremarkable, Tanner stage examination showed prepubertal stage.

Investigations showed Hemoglobin 13 g dl, white blood cell (WBC)  $9 \times 10^3/\mu\text{L}$ . Serum urea and electrolytes were normal. Liver function tests were normal, renal profile was normal.

Hormonal analysis reveled

Ft3: 48.95 pmol/l (3.5-7.7 pmol/l)

Ft4 :> 100 pmol/l (n 12-22 pmol/l)

TSH : <0.005 pmol/l (n 0.27-4.2 pmol/l)

Thyroid-stimulating Ig of 166 % (normal,  $\leq 125$ )

Ultrasound of neck showed both thyroid lobes and isthmus are mild enlarged with heterogeneous echo pattern and very high vascularity on color Doppler. Few submental lymph nodes are enlarged. (figure3) Radioactive iodine (or technetium-99) uptake not available in our center.

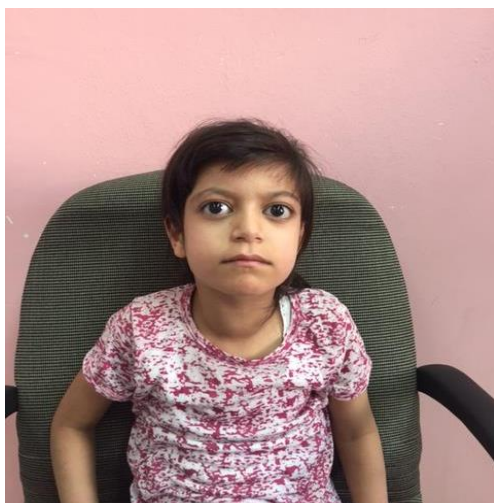

Figure 1: Bilateral exophthalmos

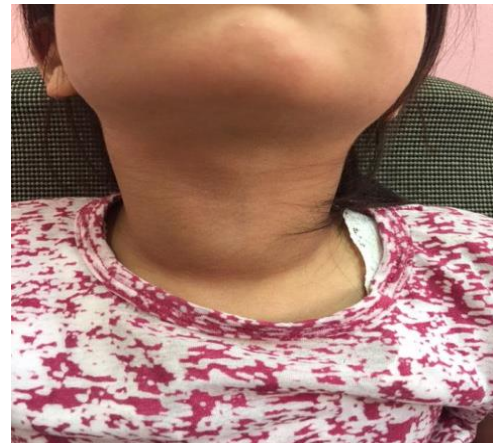

Figure 2: anterior Medline neck swelling (goiter)

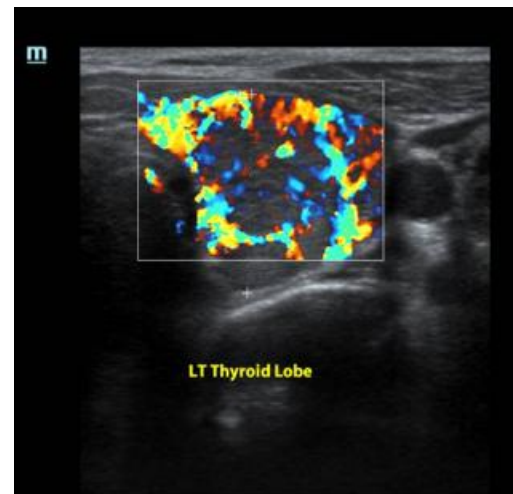


Figure 3: US neck revealed very high vascularity on color Doppler on left thyroid lobe.

## DISCUSSION

GD is more frequent in female than in male patient in both adult and children. It can occur at any age during childhood, but it increases in frequency with age, peaking during adolescence. The incidence is about 0.1per 100 000 person-years in young children to 3 per 100 000 person per years in adolescents. <sup>(1)</sup> The cause of GD remains unclear, but it is believed to result from a complex interaction between genetic factors, environmental factors and the immune system. The immune system produces an antibody [TSH receptor antibody (TRAb)] that stimulates the thyroid gland to produce excess thyroid hormone. Genetic susceptibility to the disease is thought to be polygenic. <sup>(2)</sup> The thyroid-stimulating immunoglobulin (TSI) binds to and stimulates the TSH receptor on the thyroid cell membrane resulting in

follicular cell growth, vascularity increase, and in excessive synthesis and secretion of thyroid hormone. The thyroid gland typically displays lymphocytic infiltration, with T-lymphocyte abnormality and absence of follicular destruction. T cells activate local inflammation and tissue remodelling by producing and releasing cytokines, leading to B-cell dysregulation and increase in autoantibody production. An imbalance between pathogenic and regulatory T cells is thought to be involved in both the development of GD and its severity. <sup>(3)</sup>

The symptoms of hyperthyroidism include excessive physical activity, flushing, palpitations, tremor, tachycardia weight loss, accelerated linear growth, reduced bone mineralization, and poor school performance. In pediatric GD, ophthalmopathy occurs in less than 50% of patients and is usually mild when present. <sup>(4)</sup> Hyperthyroidism is non self-limiting disease so, treatment is mandatory. Therapeutic approaches for GD include the antithyroid drugs (ATDs) propylthiouracil (PTU) or methimazole (MMI), radioactive iodine (<sup>131</sup>I), or surgery. <sup>(5-6)</sup> ATD therapy is usually recommended as the initial treatment for hyperthyroidism in children and adolescents. The most commonly used ATDs are carbimazole and its active metabolite, methimazole (MMI) and propylthiouracil (PTU). These drugs inhibit thyroid hormone synthesis by interfering with the thyroid peroxidase-mediated iodination of tyrosine residues in thyroglobulin. PTU can also block the conversion of thyroxine (T<sub>4</sub>) to triiodothyronine (T<sub>3</sub>), whereas MMI cannot. Both MMI and PTU are associated with minor reactions (rash, urticaria, arthralgia, gastrointestinal problems) in about 5% to 25% of cases. The frequency of agranulocytosis is between 0.2 and 0.5% for both drugs, and other rare but serious side effects include drug-induced hepatitis. <sup>(2)</sup> PTU is not recommended anymore because of the high risk of PTU-induced hepatitis. <sup>(7)</sup> The initial starting dose of MMI (or carbimazole) is 0.5 to 1 mg/kg/day, with a

maximum dose of 30mg per day. After two to four weeks, when thyroid hormone secretion is effectively blocked and thyroid hormone levels have normalised, the initial dose is gradually reduced by 30 to 50%. <sup>(8)</sup> Less than 30% of children achieve lasting remission after about 24 months of ATD. <sup>(9-11)</sup>

Near-total thyroidectomy and RAI therapy are the definitive therapeutic options, but both carry a high risk of permanent hypothyroidism. However, hypothyroidism is preferable to hyperthyroidism as it is easier to treat, and hyperthyroidism is associated with serious morbidities such as cardio-vascular diseases and osteopenia. <sup>(1)</sup> Total (or near-total) thyroidectomy is often currently preferred to subtotal (or partial) thyroidectomy to reduce the risk of recurrent hyperthyroidism. <sup>(11)</sup> Levothyroxine replacement therapy should be initiated within days of surgery and the patient should be subject to long-term follow-up. Complications such as hypoparathyroidism, vocal cord palsy due to recurrent laryngeal nerve injury, and keloid formation are relatively rare when the operation is performed by a paediatric surgeon with extensive experience and are estimated at about 15%. For patients with recurrent hyperthyroidism after surgery, RAI treatment is recommended. <sup>(11)</sup> Surgery is often recommended only in patients with a large goiter or with ophthalmopathy. For other Cases, however, there is still some debate about whether RAI treatment or surgical ablation should be preferred as the definitive treatment for paediatric GD. <sup>(12)</sup>

RAI treatment is effective in children with hyperthyroidism due to GD, and most patients can be successfully treated with a single oral dose. Low dose aims to cure hyperthyroidism without resulting in hypothyroidism, but the relapse rate is high. <sup>(13)</sup> Hypothyroidism is likely to occur after treatment, and appropriate doses of L-T<sub>4</sub> must therefore be administered throughout the patient's life. If hyperthyroidism persists 3 to 6 months after therapy, retreatment with I 131 is indicated.

However, RAI should be avoided in very young children because of an increased potential risk of neoplasia. Concerns about potential thyroid malignancy, hyperparathyroidism and high mortality rates have highlighted the need for a large, randomised control study with long-term follow-up to settle this issue definitively. (13-15) Remission of GD is defined as being biochemically euthyroid or hypothyroid for one year or more after the discontinuation of ATDs. (9-10)

## CONCLUSION

In our patient who is 4 years old girl presented to endocrine OPD with complaints of neck swelling tremor, nervousness, protrusion of both eyes and sleep disturbances. There is strong family history of thyroid diseases. On examination, she had goiter, exophthalmos and fine tremor. On investigation, patient had hyperthyroidism and positive thyroid-stimulating Immunoglobulin. On the basis of these findings, he was diagnosed as graves' disease, and was started on carbimazole and propranolol. Clinician should keep in mind that Graves' disease is the most common cause of hyperthyroidism in children.

## REFERENCES

1. Lavard L, Ranlov I, Perrild H, Andersen O, Jacobsen BB. Incidence of juvenile thyrotoxicosis in Denmark, 1982-1988. A nationwide study. *Eur J Endocrinol* 1994; 130:565-568.
2. Juliane Léger, Jean Claude Carel. Hyperthyroidism in Childhood: Causes, When and How to Treat. *J Clin Res Pediatr Endocrinol*. 2013 Mar; 5(Suppl 1): 50–56.
3. Saitoh O, Nagayama Y. Regulation of Graves' hyperthyroidism with naturally occurring CD4+CD25+ regulatory T cells in a mouse model. *Endocrinology* 2006; 147: 2417-2422.
4. Rivkees SA, Sklar C, Freemark M: Clinical review 99: The management of Graves' disease in children, with special emphasis on radioiodine treatment. *J Clin Endocrinol Metabol* 1998, 83:3767–3776.
5. Weetman AP: Grave's disease 1835–2002. *Horm Res* 2003, 59(Suppl 1):114–118.
6. Chapman EM: History of the discovery and early use of radioactive iodine. *JAMA* 1983, 250:2042–2044.
7. Rivkees SA, Mattison DR. Ending propylthiouracil-induced liver failure in children. *N Engl J Med* 2009;360:1574-1575.
8. Cooper DS. Antithyroid drugs. *N Engl J Med* 2005;352:905-917.
9. Glaser NS, Styne DM. Predictors of early remission of hyperthyroidism in children. *J ClinEndocrinolMetab* 1997;82:1719-1726.
10. Hamburger JI. Management of hyperthyroidism in children and adolescents. *J ClinEndocrinolMetab* 1985;60:1019-1024.
11. Zimmerman D, Gan-Gaisano M. Hyperthyroidism in children and adolescents. *Pediatr Clin North Am* 1990; 37: 1273-1295.
12. Lee JA, Grumbach MM, Clark OH. The optimal treatment for pediatric Graves' disease is surgery. *J ClinEndocrinolMetab* 2007;92:801-803.
13. Rivkees SA, Cornelius EA. Influence of iodine-131 dose on the outcome of hyperthyroid children. *Pediatrics* 2003; 111:745-749.
14. Read CH Jr, Tansey MJ, Menda Y. A 36-year retrospective analysis of the efficacy and safety of radioactive iodine in treating young Graves' patients. *J Clin Endocrinol Metab* 2004;89:4229-4233.
15. Metso S, Jaatinen P, Huhtala H, Auvinen A, Oksala H, Salmi J. Increased cardiovascular and cancer mortality after radioiodine treatment for hyperthyroidism. *J Clin Endocrinol Metab*. 2007 Jun;92(6):2190-6.

How to cite this article: Alenazi B, Alenazi A, Alshaya A et al. Pediatric graves' disease: a case report. *Int J Health Sci Res*. 2017; 7(12):330-333.

\*\*\*\*\*