

Case Report

Apical Barrier Formation using Calcium Hydroxide for the Management of Fractured Central Incisors with Open Apex: Report of Two Cases

Sunil Kumar M¹, Mahantesh Chinagundi², Sonal Sahasrabudhe³, Adeeba Khanum⁴Professor¹, Asst Prof², PG Students^{3,4}Dept of Orthodontics & Dentofacial Orthopedics, Faculty of Dental Sciences
M.S. Ramaiah University of Applied Sciences, Bangalore

Correspondence Author: Sunil Kumar M

*Received: 17/12/2015**Revised: 13/01/2016**Accepted: 19/01/2016*

ABSTRACT

Dental injury to immature permanent incisors is the commonly encountered problem in young children during the turbulent years of transition into adolescence. The management of such teeth is complicated due to the presence of wide open apices. In such cases definitive endodontic treatment has to be postponed till an apical 'stop' or hard tissue barrier is formed for condensation of gutta-percha. This article presents two cases of fractured immature permanent incisors with open apex treated successfully with calcium hydroxide to induce apical hard tissue bridge formation.

Key words: Apexification; Calcium hydroxide; Central Incisors.

INTRODUCTION

The permanent immature teeth have an important role in the development of occlusion and psychological development of the children. Dental trauma of incisors may compromise the function and esthetics of children during the turbulent years of growth and development. Apexification is a procedure which helps to preserve many compromised, immature permanent teeth with nonvital pulps by endodontic and restorative means. [1] Apexification is defined as a method to induce calcific barrier in a root with an open apex or continued apical development of an incomplete root in teeth with necrotic pulp. [2] Cvek has shown successful apical barrier formation in 96% cases treated with calcium hydroxide as the intra-canal medicament. [3] Calcium hydroxide is known to induce osteodentine or osteocementum or bone-like material in the apical region which forms a hard tissue bridge located at the tip of the root or may

appear as an irregular mass of calcified tissue traversing the apical one third of the root. [4] The past literatures on apexification have shown that it may take 5-20 months in order to induce this calcified barrier in the apical region. [3] The renewal of calcium hydroxide paste during this period seems to be controversial. Some authors suggest that renewal of calcium hydroxide is necessary in teeth with wide apex and inflammatory exudates while others have shown that single application is sufficient to induce apical barrier formation. [5] This case report documents two cases of successful apexification by renewal of calcium hydroxide paste in an infected canal and without replacement of paste in a non-contaminated canal.

CASE REPORTS

CASE 1: A female patient of age 10 years reported complaining broken and discoloured upper front tooth. The pain was located to single tooth which was

discoloured and tender on percussion. The patient revealed a history of trauma in the same tooth 3 years before and treatment was not initiated during that period. The patient did not present any contributory medical history. On clinical examination, the permanent maxillary left central incisor (21) was severely fractured and was thus classified as Elli's Class IV type of fracture (Figure 1). An occlusal radiograph revealed fracture involving the pulp in relation to maxillary permanent left central incisor with wide open apex and an impacted mesiodens palatal to 11 (Figure 2). The central incisor did not respond to pulp vitality tests. Apexification was the treatment of choice for this case and calcium hydroxide medicament was used to promote apical closure. An access cavity was prepared parallel to the long axis of the central incisor to gain straight line axis to the canal. The necrotic pulp was extirpated with hedstrom files (H-files) thoroughly along with copious irrigation with normal saline. The working length was established within 1 mm of the radiographic apex for cleaning and shaping of the canal. The remnant pulp tissue on the lateral dentinal walls was debrided till the previously determined working length. The canals were then dried with paper points followed by placement of calcium hydroxide paste with a plugger till the apex which was prepared by mixing calcium hydroxide powder with normal saline. A radiograph was taken to confirm the extension of the calcium hydroxide paste in the canal (Figure 5). Access cavity was restored with glass ionomer cement and patient was recalled after 1 month. In the second visit, a radiograph was taken followed by replacement of the calcium hydroxide medicament with fresh mixture and access cavity restored with glass ionomer cement. During this visit the patient was informed about the palatally impacted mesiodens and surgical extraction was advised. In the third visit the palatally placed mesiodens was surgically removed without causing any

damage to the adjacent central incisor roots (Figure 3). Then the patient was recalled every three months for the follow-up of the apical barrier formation in 21. The patient returned only after 6 months for the check up but without any symptoms in 21. A radiograph was taken which revealed apical barrier formation without increase in root length or thickening of dentinal walls. Clinically this apical barrier was confirmed by using paper point and a K-file to check for any resistance or apical 'stop'. After the apical barrier was determined the tooth was obturated with tailor-made gutta-percha technique followed by an interim restoration (polycarbonate crown) to protect the tooth till the definitive treatment is given (Figure 4).

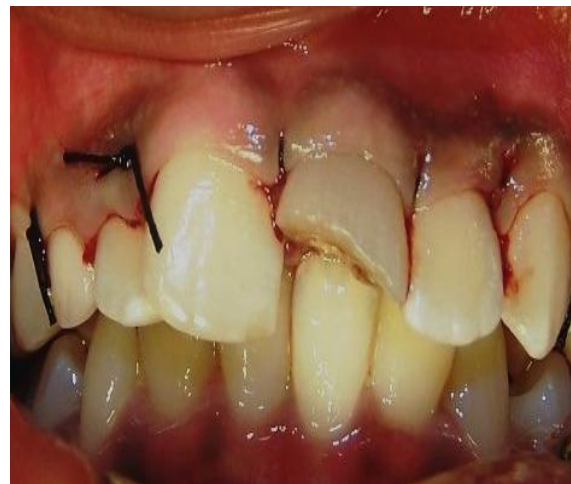

Figure 1 – Frontal view showing fractured 21 with discolouration

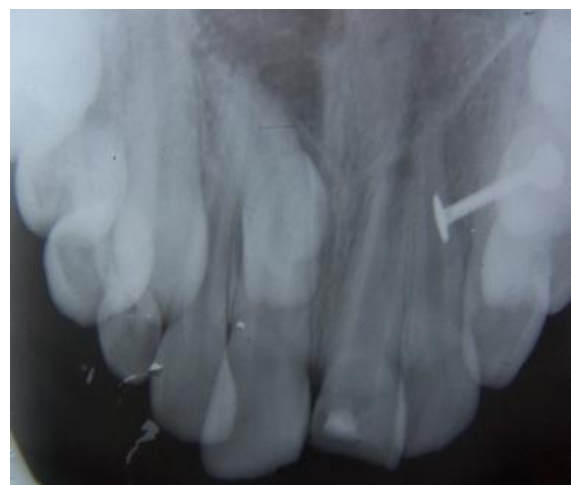

Figure 2 – Occlusal radiograph showing open apex in 21 and impacted mesiodens in relation to 11

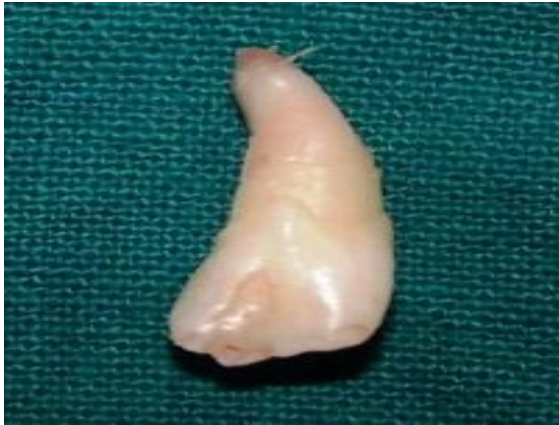

Figure 3 – Specimen of mesiodens after surgical extraction

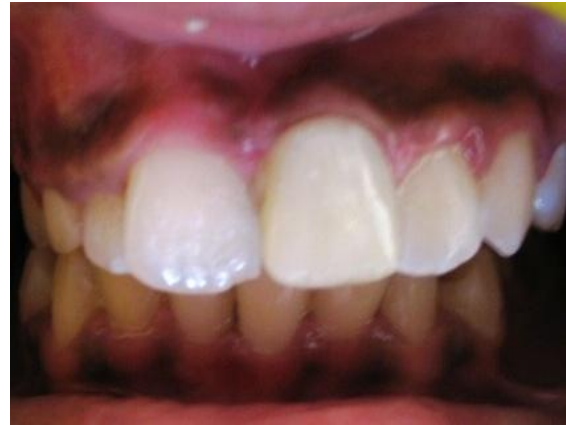

Figure 4 – Post-operative view with interim restoration of polycarbonate crown in 21

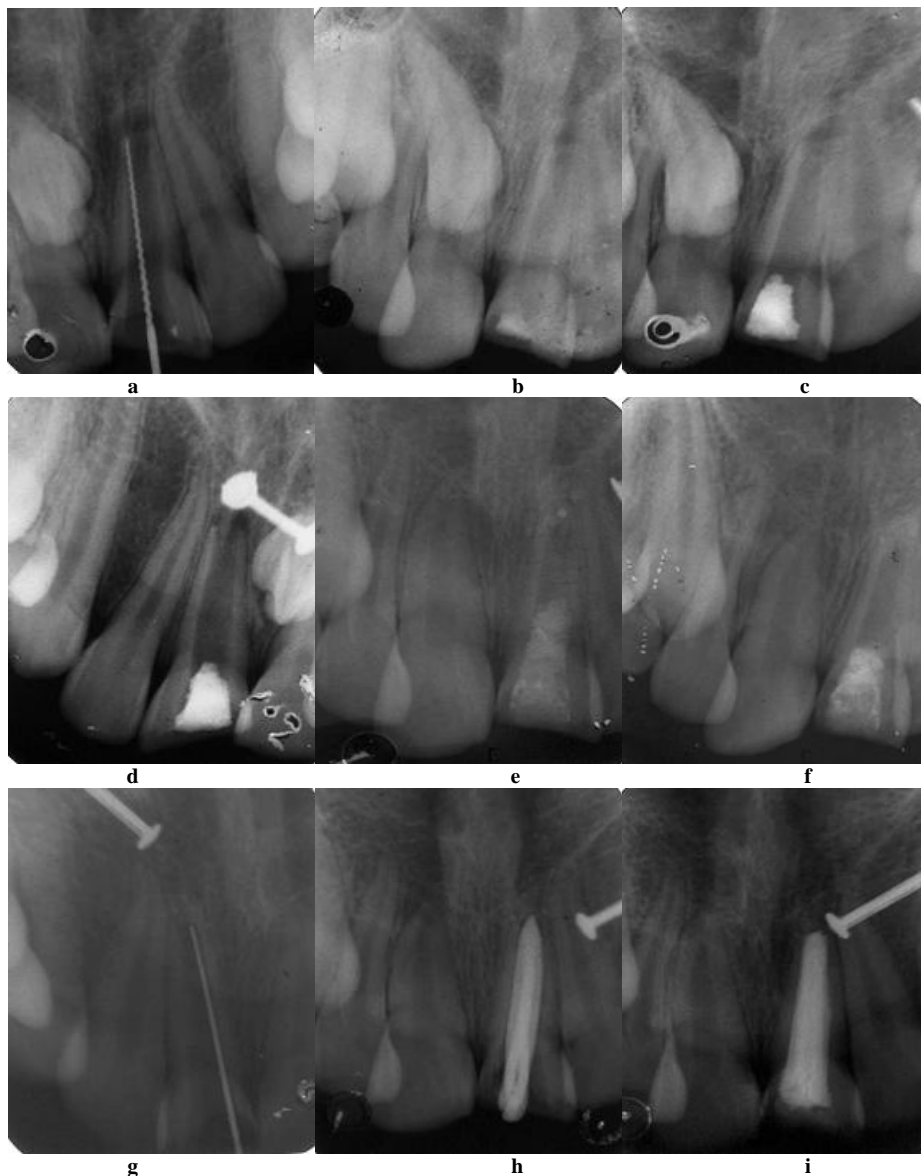


Figure 5 : Apexification in 21 completed within 8 months: (a) access cavity prepared and working length determined; (b) calcium hydroxide paste placed in the canal; (c) access cavity restored with glass ionomer cement; (d) radiograph after 1 month shows dissolution of calcium hydroxide paste; (e) & (f) renewal of paste done; (g) radiograph after 8 months shows hard tissue bridge in the apical region; (h) & (i) obturation done with Gutt-percha.

CASE 2: Another similar case with a history of trauma 2 months before reported to the clinic complaining of pain since 1 week in the upper front tooth. The patient was a boy of age 12 years accompanied by his parents. The parents did not give any significant medical history related with the child. A complete clinical examination revealed fracture involving the pulp in relation to 11 which was confirmed with a periapical radiograph. The radiograph suggested that the apex in relation to 11 was not completely closed which was confirmed clinically later on. Pulp vitality tests with electric pulp tester showed that

the tooth was partially vital. The procedure was similar as it was for the previous case using mixture of calcium hydroxide and normal saline. The patient was recalled every month for the radiographic evaluation of the treatment (Figure 6). The follow-up radiograph showed positive changes with apical maturation. After 5 months there was complete closure of the apex with an apical resistance or 'stop'. The treatment was completed by obturating the canal with gutta-percha followed by a semi-permanent restoration (polycarbonate crown) to protect the tooth.

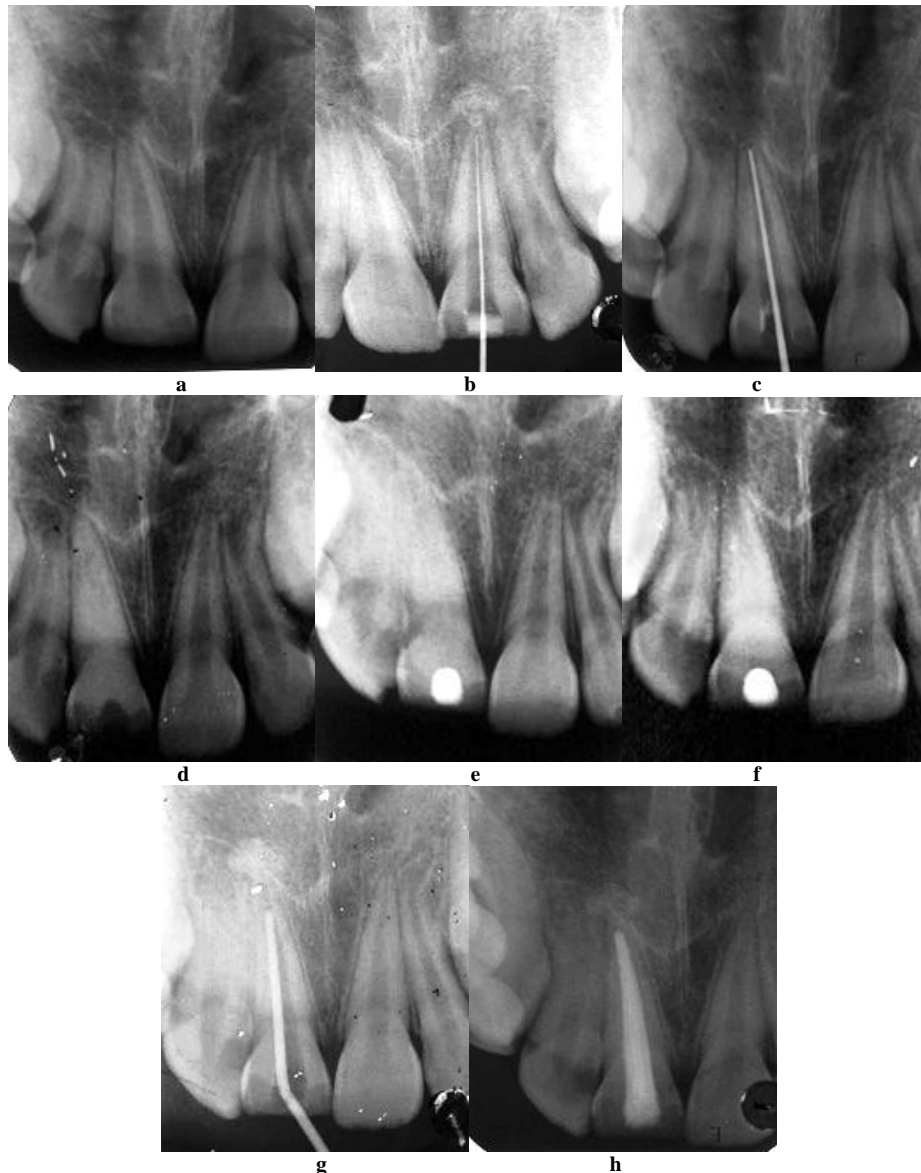


Figure 6: Apexification in 11 completed in 5 months: (a) pre-operative radiograph; (b) working length determined; (d) calcium hydroxide paste placed in the canal; (e) & (f) access cavity restored with glass ionomer cement.

DISCUSSION

The mechanism by which apical barrier is formed may be due to the alkalinity, antibacterial or neutralizing effect of calcium hydroxide. [4] The mere physical presence of calcium hydroxide material in the root canal prevents the penetration of granulation tissue and exudates into the canal space which in turn inhibits the osteoclastic activity. [3] Calcium hydroxide is a biocompatible material which is easily available and affordable by patients. Therefore, it has been widely accepted as the material of choice for the treatment of non-vital immature permanent teeth.

The drawbacks of calcium hydroxide apexification are, multiple visits leading to inevitable high costs; increased risk of root fracture; long time-span; root length compromised; thin lateral dentinal walls increasing the chances of root fracture; prevent apical pulp tissue regeneration due to calcific barrier formation; and it may damage the Hertwig's epithelial root sheath. [6,7] To overcome the drawbacks of calcium hydroxide, mineral trioxide aggregate (MTA) was used which induced hard tissue formation within a short time-span and improved patient compliance. [8] A new technique known as Revitalization/Revascularization which is an attempt to revitalize tissues in the pulp space and continued root formation in immature nonvital pulps is being investigated. The results of clinical trials shows high success rate in terms of regeneration of pulp, increased root length, and thickening of lateral dentinal walls, however, these preliminary reports still needs to be analyzed before its clinical application. [1]

There are two schools of thought regarding the need to replace the calcium hydroxide paste, some authors suggest a single application is sufficient to induce hard tissue barrier apically, because the calcium hydroxide paste acts only as a catalyst for deposition of calcified tissue and as a filler material in the canal space.

[9-11] In contrast, another group of authors recommend that renewal of paste is necessary in presence of a very wide foramen and inflammatory exudates in the apical region which increases the rate of dissolution of the paste. Therefore, renewal of calcium hydroxide paste in the initial stages cannot be under-estimated in infected immature teeth for the successful apical closure. [12,13]

The larger the apical opening, the longer is the time needed to induce apical closure. [4] The rate of apical barrier formation is directly proportional to the renewal of calcium hydroxide paste in infected immature non-vital tooth. [5] The time required also depends on the age of the patient and presence of any periradicular infections. [1]

In the present case report, the case 1 was treated with replacement of calcium hydroxide paste because the tooth was necrotic with inflammatory exudates present in the canal, while in case 2, the tooth was left without renewal. The rate of barrier formation in case 2 was faster than the tooth in which replacement of paste was done. This may be due to the very wide open apex in the first case or the presence of inflammatory exudates in the canal.

A definite conclusion could not be reached in the present case report, however, it can be interpreted that only infectious immature teeth with inflammatory exudates or periapical infections with wide open apex require renewal of calcium hydroxide paste. It also suggests that future clinical studies on apexification should investigate the effect of inflammatory exudates in the canals on the rate of barrier formation and need for renewal of paste.

REFERENCES

1. Huang GTJ. Apexification: the beginning of its end. *Int Endod J.* 2009; 42(10):855-66.
2. American Association of Endodontics. American Association of Endodontics Glossary of endodontic terms, 7th

- edition. Chicago, IL: American Association of Endodontics, 2003.
3. Jacobovitz M, de Pontos Lima RK. The use of calcium hydroxide and mineral trioxide aggregate on apexification of a replanted tooth: a case report. *Dent Traumatol.* 2009; 25:e32-e36.
 4. Peretz B. Apexification of wide-open apices in nonvital, immature permanent incisor: A case report. *Quintessence Int.* 1993; 24(11):799-802.
 5. Felipe MCS, Felipe WT, Marques MM, Antoniazzi JH. The effect of renewal of calcium hydroxide paste on the apexification and periapical healing of teeth with incomplete root formation. *Int Endod J.* 2005; 38:436-42.
 6. Andreasen JO, Farik B, Munksgaard EC. Long-term calcium hydroxide as a root canal dressing may increase risk of root fracture. *Dent Traumatol.* 2002; 18:134-7.
 7. Cvek M. Prognosis of luxated non-vital maxillary incisors treated with calcium hydroxide and filled with gutta-percha: A retrospective clinical study. *Endod Dent Traumatol.* 1992; 8:45-55.
 8. Shabahang S, Torabinejad M, Boyne PP, Abedi H, McMillan P. A comparative study of root-end induction using osteogenic protein-1, calcium hydroxide, and mineral trioxide aggregate in dogs. *J Endod.* 1999; 25:1-5.
 9. Chosack A, Sela J, Cleaton-Jones P. A histological and quantitative histomorphometric study of apexification of nonvital permanent incisors of vervet monkeys after repeated root filling with a calcium hydroxide paste. *Endod Dent Traumatol.* 1997; 13:211-7.
 10. Gupta S, Sharma A. Unmonitored apexification of wide open apex in nonvital immature incisor: a case report. *J Clin Pediatr Dent.* 1996; 20:145-7.
 11. Chawla HS. Apical closure in a nonvital permanent tooth using one Ca(OH)₂ dressing. *ASDC J Dent Child.* 1986; 53:44-7.
 12. Leonardo MR, Silva LAB, Leonardo RT, Utrilla LS, Assed S. Histological evaluation of therapy using a calcium hydroxide dressing for teeth with incompletely formed apices and periapical lesions. *J Endod.* 1993; 19:348-52.
 13. Yates JA. Barrier formation time in non-vital teeth with open apices. *Int Endod J.* 1988; 21:313-9.

How to cite this article: Sunil Kumar M, Chinagundi M, Sahasrabudhe S et. al. Apical barrier formation using calcium hydroxide for the management of fractured central incisors with open apex: report of two cases. *Int J Health Sci Res.* 2016; 6(2):388-393.
