

Original Research Article

Clustering Based Cup to Disc Ratio Method for Diagnosis of Primary Glaucoma

Patil Dnyaneshwari D^{1*}, Manza Ramesh R^{2*}, Gornale Sivanand S^{2**}

¹Researcher, ²Associate Professor, ²Associate Professor,

^{*}Department of CS & IT, Dr. BAMU, Aurangabad.

^{**}Department of Computer Science. School of Mathematics & Computing Sciences, Rani Channamma University, Vidyasangam, NH-4, Belagavi.

Corresponding Author: Patil Dnyaneshwari D.

Received: 01/12/2015

Revised: 21/12/2015

Accepted: 28/12/2015

ABSTRACT

Glaucoma is one of the leading reasons of blindness worldwide. In several countries many people suffer from this disease. Manual as well as automatic glaucoma detection methods are available. Here we have proposed one method which is called as the Cup to Disc Ratio (CDR) method by using online data base that is DRIONS-DB and RIM-ONE which is freely available. Then we applied our proposed method on that data base, and compare the results with the literature survey results and we got 99.00 % result by using CDR method.

Keywords: CDR-Cup to Disc Ratio, ROI-Region of Interest, ONH-(Optic Nerve head), IOP-Intra Ocular Pressure.

INTRODUCTION

Glaucoma is one of the leading causes of blindness worldwide. It is often associated with increase in intraocular pressure (IOP) of the fluid (known as aqueous humor) in eye. And if it is not drainage out properly from the eye it generates intra ocular pressure in eye and due to that pressure the size of optic cup is increased and the optic nerve head is also damaged. Normal person with CDR value is 0.2 to 0.3 mm but when it increased up to 0.6 to 0.7 mm it becomes glaucomatous and it requires further testing or treatment. [1] Due to this purpose the nick name of Glaucoma is “silent thief of sight”.

The early phases of glaucoma will damage the optic nerve without incurring any symptom. The patients are not aware of the disease until the progressive stage of disease occurs which makes total

blindness. The damage caused is irreversible, but through primary treatment can prevent progression of the disease if detected in the early stage. Thus, the early detection of glaucoma has been crucial and compulsory.

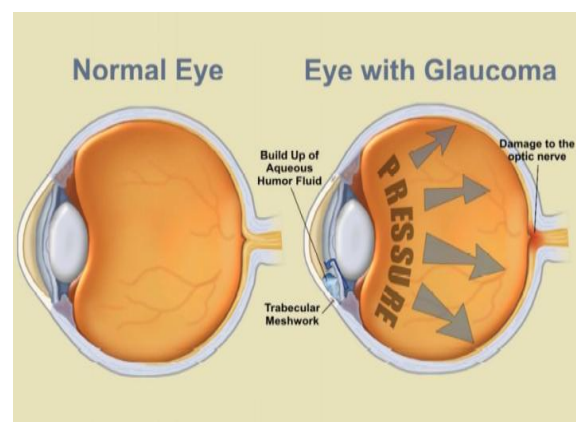


Figure 1: Medical image of normal and affected eye. [14]

Literature Survey: In literature survey we survey the most common methods used for diagnosis of glaucoma and the results obtained from these several methods. And after survey we decide to work on K-

means clustering technique, which gives higher results as compare to the techniques. Following table shows a short structure of literature review which has the references from, [2] to. [8]

Table1 Literature survey with author name, technique used, &result obtained.

Sr. No.	Author name	Technique	Results
1	DharmannaLamani	Fractal Dimension	95%
2	K. Narasimhan & K. Vijayarekha	K-means clustering technique,& SVM classifier.	95%
3	V. Pueyo	Gabor filter is performed with a Gaussian filter	71%
4	ChisakoMuramatsu	segmented using the active contour method	82%
5	Mrs. Preeti Kailas Suryawanshi	Segmentation Techniques	26 out of 45images
6	S. Kavitha	K means clustering	97%
7	Juan XuaandOpasChutatapeb	modified deformable model technique	94%

Database: A set of specific images is considered as ‘database’ here. For specific purpose it is used here and here we have used two different databases for the two purposes. One is DRIONS-DB and another one is RIM-One database and these are public database.

DRIONS-DB: In this database there are 110 images of retina and the mean age of the patients was 53.0 years, with the percentage of patients 46.2% male and 53.8% female. The images were captured by a colour analogical fundus camera, and they were stored in slide format, approximately concentrate on centered on the optic nerve head. In order to have the images in RGB format or digital format, they were digitized using a HP-Photo Smart-S20 high-resolution scanner. Resolution of image is 600x400 and 8 bits/pixel. [9]

RIM-One: Rim-I is our second data base which is available free download with the different digital fundus images in which some images having with different glaucoma levels and some are healthy eye images.

Here in this research work we are used only healthy images for applying our proposed algorithm on it because it contains gold standard for each image. And that gold standard is collaborated with three different Spanish hospitals: Hospital Universitario de Canaria, Hospital Clínico San Carlos and Hospital Universitario Miguel Servet. [10]

Proposed Method: There are several methods available to work on Glaucoma, Here we choose CDR i.e. cup to disc ratio.

Measuring cup to disc ratio (CDR): It is not possible to measure the ratio directly from the image. For measuring the ratio, this image goes from the several stages and after applying the various pre-processing steps on it we got some features of image. The cup to disc ratio is a measurement used in ophthalmology and optometry to assess the growth of glaucoma. The optic disc is the structural location of the eye's blind spot, the area where the optic nerve and blood vessels arrive the retina. The optic disc can be at or can have a certain volume of normal cupping. But glaucoma, which is due to an upsurge in intra-ocular pressure, produces additional pathological cupping of the optic disc.

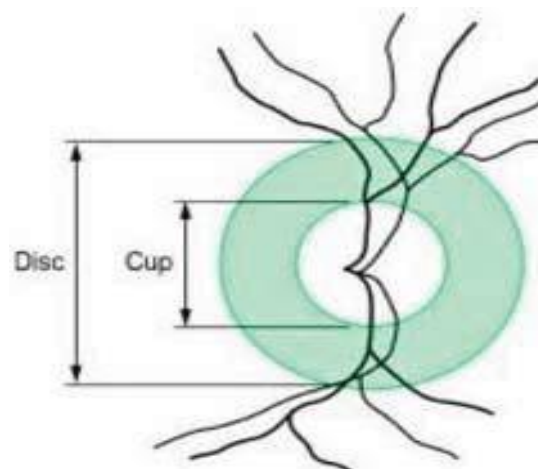


Figure 2: CDR definition. [2]

As glaucoma advances, the cup enlarges until it conquers most of the disc area as shown in Figure 2. The cup to disc ratio compares the diameter of the "cup" ration of the optic disc with the total diameter of the optic disc. A large cup to

disc ratio may indicate glaucoma. However, cupping by itself is not symbolic of glaucoma. Rather, it is an increase in cupping as the patient age which is an indicator for glaucoma. [2]

Work Flow Steps

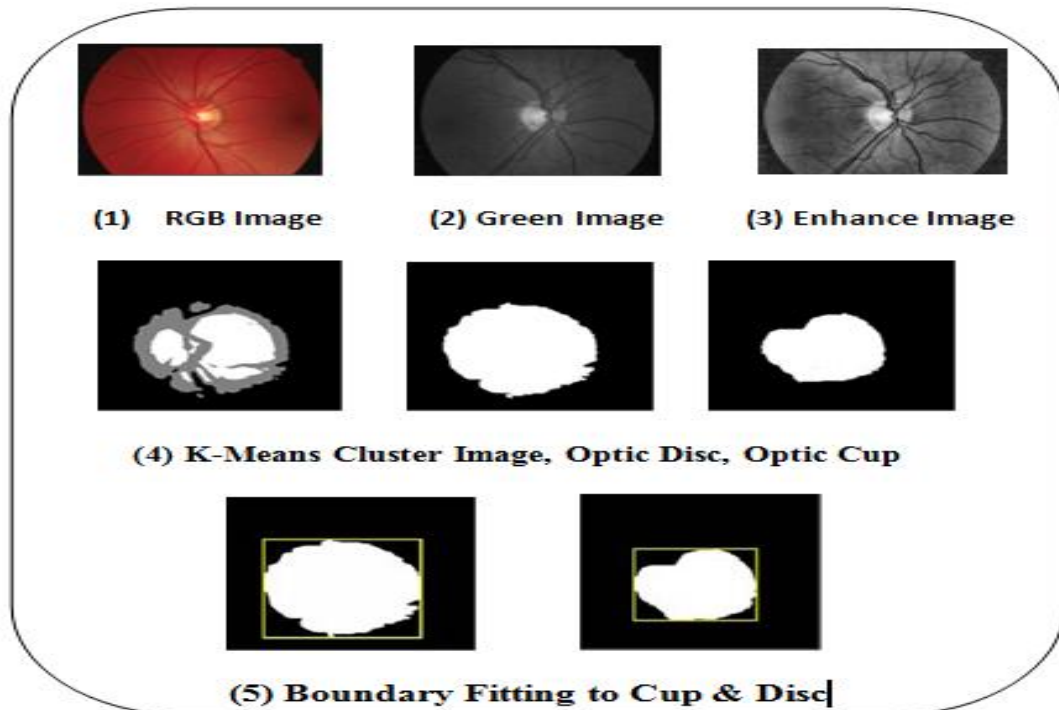


Figure 3: Work flow steps for ROI extraction in glaucoma diagnosis.

RGB Image: Images used from the DRIONS-DB database and RIM-One database is of RGB type. RGB images sometimes referred as a true color image. In this paper we have worked on the Green channel images. Here we have used green channel images because the intensity of green channel image is more than the red and blue channel.

Green Image: Firstly we have carried out the process of taking green channel from RGB image, the formula for green channel Extraction [11,12] is as follows:

$$g = \frac{G}{(R + G + B)} \quad (1)$$

Where, g = is a Green channel, R =Red, G =Green, B =Blue. We use above formula for green channel on both the database images 110 DRIONS-DB

Glaucomatous and randomly selected 64 Normal images from RIM-One database.

Enhance Image: For the proper enhancement of image we go from some stages. Like first we take histogram of green channel image. In second stage, we have enhanced the green image by taking the histogram equalization. Histogram equalization is used for enhancing the image quality. After the Green channel we have applied histogram equalization [12,13] for image enhancement.

$$h(v) = \text{round} \left(\frac{\text{cdf}(v) - \text{cdf}_{\min}}{(M \times N) - \text{cdf}_{\min}} \times (L - 1) \right) \quad (2)$$

Where, cdf_{\min} is the minimum value of the collective distribution function, $M * N$ gives the image's number of pixels. L is the number of grey stages.

With the help of this histogram equalization we can enhance the image.

5.4 K-Means clustering Algorithm:

After image enhancement, we have applied K-Means cluster on enhance image because it plays important role in feature extraction mechanism. Finally, this algorithm aims at minimizing an objective function (squared error function). The objective function is as follows.

$$J = \sum_{j=1}^k \sum_{i=1}^n \|x_i^{(j)} - c_j\|^2 \quad (3)$$

Where $\|x_i^{(j)} - c_j\|^2$ a chosen distance measure between is a data point and the cluster center C_j is and pointer of the distance of the n data points $x_i^{(j)}$ from their respective cluster centers. [3] In above fig.3 with step no.4 we see K-means cluster image, then optic disc & optic cup, which is extracted by using above formula.

Boundary Fitting to Cup & Disc: Then after extracting the futures next step is boundary fitting, here we applied connected component technique to form the rectangle that includes whole disc & cup region. As shown in fig 3 shown in step 5.

Calculating Area of cup & Disc: For calculating area the connected component technique is helpful for elliptical fitting Inside the rectangle which inscribed the area of disc & area of cup also. After elliptical fitting we calculate the actual area of disc & cup which are inside the ellipse by the following formula.

$$\text{Area} = \pi ab \quad (4)$$

Where a is the major axis length means half of the rectangle width, and b is the minor axis length means half of the rectangle height. [3]

Calculating CDR: For a normal person, the CDR value is around 0.2 to 0.3. Typically, subjects with CDR value greater than 0.6 or 0.7 are assumed of having glaucoma and further testing is often needed to make the diagnosis. [1] By the formula:

$$\text{CDR} = h_1/h_2 \quad (5)$$

Where, CDR = Cup to Disc ratio
 h_1 = (Area of cup) h_2 = (Area of disc)

RESULTS

For this proposed method we use 110 images of DRIONS-DB and 64 from RIM-One database we got 95 % result from glaucomatous database & 99% result from Normal database, overall we got 99% result from 174 images.

Table 2. Calculating result from DRIONS-DB & RIM-One database. Table 3. Comparison of result with literature survey.

Total No. of Images	Normal	Glaucoma		
		Mild	Moderate	Severe
110+64 = 174	Range	Range		
	(0.2 to 0.6mm)	(0.7 mm)	(0.8 mm)	(0.9 mm)
		Mild	Moderate	Severe
	62	14	30	68
Result	35%	64.36%		
Overall Result 99.36%				

Sr. No.	Technique	Results
1	Fractal Dimension	95%
2	K-means clustering technique, & SVM classifier.	95%
3	Gabor filter is performed with a Gaussian filter	71%
4	segmented using the active contour method	82%
5	Segmentation Techniques	26 out of 45 images
6	K means clustering	97%
7	modified deformable model technique	94%
8	Proposed Method	99%

DISCUSSION

In this research work we proposed here new algorithm including K-Means clustering feature extraction method. We choose this because of, in literature survey Dharmanna Lamani, DR. Ramegowda, DR. T.C. Manjunath was used this technique and get 97% results on their own data set. [2] On the basis of that we used here on the DRIONS-DB and RIM-One data set and get overall 99% results. And classify this result in three groups as per there intensities.

SUMMARY & CONCLUSIONS

Here it is concluded that for detection and diagnosis of glaucoma, image processing techniques are applied on the retinal fundus images and getting more accurate results through it. When both images are combined i.e. 110 Glaucomatous & 64 normal images together & when categorized that result in four clusters i.e. normal, & glaucomatous with mild, moderate & severe. The results obtained are, Normal 35 % images, Glaucomatous with Mild 8.3 % images, Moderate with 17.24 % images, & Severe with 39.08 % images.

REFERENCES

1. Fengshou Yin, Jiang Liu, Damon Wing Kee Wong, NganMeng Tan, BengHai Lee, Jun Cheng, Min ThetHtoo, Zhuo Zhang, YanwuXuand XintingGao, "ACHIKO-I Retinal Fundus Image Database and its Evaluation on Cup-to-Disc Ratio Measurement". DOI: 10.1109/ICIEA.2013.6566370 Conference: Industrial Electronics and Applications (ICIEA), 2013 8th IEEE Conference on
2. Dharmanna Lamani DR. Ramegowda, DR. T.C. Manjunath," Fractal Dimension as Diagnostic Parameter to Detect Glaucoma", Department of Computer science and Engineering SDMIT, Ujire, Karnataka, India. International Journal of Innovations in Engineering and Technology (IJET). Vol. 2 Issue 1 February 2013 page no. 63 ISSN: 2319 – 1058.
3. K. Narasimhan, Dr.K. Vijayarekha Iasst Prof., Department Of Ece, Sastra "An Efficient Automated System for Glaucoma Detection Using Fundus Image". Journal of Theoretical and Applied Information Technology, 15th November 2011. Vol. 33 No.1
4. V. Pueyo, J. M. Larrosa, V. Polo, A. Perez-Inigo, A. Ferreras, F. M. Honrubia. Sector-Based Analysis of the Distribution of the Neuroretinal Rim by Confocal Scanning Laser in the Diagnosis of Glaucoma. Arch Soc Esp Oftalmol, 2006(81):135-140.
5. ChisakoMuramatsu, a Toshiaki Nakagawa, b Akira Sawada, c Yuji Hatanaka, d Tetsuya Yamamoto, c and Hiroshi Fujitaa
6. Automated determination of cup-to-disc ratio forclassification of glaucomatous and normal eyes onstereo retinal fundusimages. aGifu University, Graduate School of Medicine, Department of Intelligent Image Information 1-1 Yanagido, Gifu 501-1194, and Japan.
7. Mrs. Preeti Kailas Suryawanshi Department of Electronics & Telecommunication, Satara College of Engineering &Management, Limb Satara, Maharashtra, India" An Approach to Glaucoma using Image Segmentation Techniques International Journal of Engineering Sciences & Research Technology. International journal of engineering sciences & research, [Suryawanshi, 2(9): September, 2013] issn: 2277-9655, impact factor: 1.852
8. S. Kavitha, K. Duraiswamyasst, an efficient decision support system for Detection of glaucoma in fundus images using anfis. Prof, Nandha engineering college, Erode, India, International Journal of Advances in Engineering & Technology, Jan 2012. Page no. 227 Vol. 2, Issue 1, pp. 227-240.
9. Juan Xua,, Opas Chutatapab, Eric Sungc, CeZhengd, Paul Chew Tec Kuand, Optic disk feature extraction via modified deformable model

technique for glaucoma analysis a Department of Ophthalmology, School of Medicine, University of Pittsburgh, USA.
[http://www.ia.uned.es/~ejcarmona/DRIONS-DB/BD/DRIONS-DB.rar\(Database\)](http://www.ia.uned.es/~ejcarmona/DRIONS-DB/BD/DRIONS-DB.rar(Database)).

10. F. Fumero, S. Alayon, J.L. Sanchez, J. Sigut, M. Gonzalez-Hernandez. "RIM-ONE: An Open Retinal Image Database for Optic Nerve Evaluation", DOI: 10.1109/CBMS.2011.5999143 Conference: Computer-Based Medical Systems (CBMS), 2011 24th International Symposium on Source: IEEE Xplore.
11. Yogesh M. Rajput, Ramesh R. Manza, Manjiri B. Patwari, Neha Deshpande, "Retinal Optic Disc Detection Using Speed Up Robust Features", National Conference on Computer & Management Science [CMS-13], April 25-26, 2013, Radhai Mahavidyalaya, Auarnagabad-431003(MS India).
12. Amin Dehghani, Hamid Abrishami Moghaddam and Mohammad-Shahram Moin," Optic disc localization in retinal images using histogram matching", Dehghani et al. EURASIP Journal on Image and Video Processing 2012, 2012:19
13. Deepali R. Rathod Yogesh M. Rajput, Ramesh R. Manza, Manjiri B. Patwari, Neha Deshpande, Localization of Optic Disc and Macula using Multilevel 2-D Wavelet Decomposition Based on Haar Wavelet Transform International Journal of Engineering Research & Technology (IJERT) ISSN: 2278-0181 Vol. 3 Issue 7, July – 2014.
14. ArchanaNandibewoor S B Kulkarni Sridevi Byahatti Ravindra Hegadi, "Computer Based Diagnosis of Glaucoma using Digital Fund us Images", Proceedings of the World Congress on Engineering 2013 Vol III,WCE 2013, July 3-5, 2013, London, U.K.

How to cite this article: Dnyaneshwari DP, Ramesh RM, Sivanand SG. Clustering based cup to disc ratio method for diagnosis of primary glaucoma. Int J Health Sci Res. 2016; 6(1):434-439.

International Journal of Health Sciences & Research (IJHSR)

Publish your work in this journal

The International Journal of Health Sciences & Research is a multidisciplinary indexed open access double-blind peer-reviewed international journal that publishes original research articles from all areas of health sciences and allied branches. This monthly journal is characterised by rapid publication of reviews, original research and case reports across all the fields of health sciences. The details of journal are available on its official website (www.ijhsr.org).

Submit your manuscript by email: editor.ijhsr@gmail.com OR editor.ijhsr@yahoo.com