



Original Research Article

A Prospective Comparative Study to Evaluate the Outcome of Fibrin Glue versus Sutures for Conjunctival Autografting after Primary Pterygium Excision

Priya V R¹, Shubhratha S Hegde²

¹Senior Resident (Minto Ophthalmic Hospital), Department of Ophthalmology, Bangalore Medical College and Research Institute, Bengaluru, Karnataka.

²Senior Resident, Department of Ophthalmology, Mysore Medical College and Research Institute, Mysuru, Karnataka.

Corresponding Author: Priya V R

Received: 02/12/2014

Revised: 22/12/2014

Accepted: 31/12/2014

ABSTRACT

Aim: To compare the use of fibrin glue versus sutures for fixating conjunctival autografts in patients undergoing primary pterygium excision.

Methods: This was a prospective comparative clinical study. A total of 80 patients (80 eyes) with primary nasal pterygium were randomized to undergo pterygium excision and conjunctival autografting using either fibrin glue (40 eyes) or 10-0 nylon suture (40 eyes). Patients were followed up for 6 months. The groups were compared in terms of duration of surgery, degree of postoperative discomfort, inflammation, subconjunctival haemorrhage, graft stability and pterygium recurrence.

Results: The mean surgery time in fibrin glue group was 14.5 minutes and in suture group was 26 minutes ($p=0.000$). Fibrin glue group had significantly lesser postoperative discomfort ($p=0.000$) and inflammation ($p=0.001$) compared to suture group at post-op day 1 and week 1, with no difference at subsequent follow-ups. No significant difference was found in degree of subconjunctival haemorrhage between the groups ($p=0.887$ and $p=0.797$ at day 1 and week 1 respectively). Grafts secured with fibrin glue were as stable as those secured with sutures ($p=0.745$, 0.644 at day 1 and week 1 respectively). 2 pterygium recurrences were noted in each group. One case of suture granuloma was noted. No side effects or complications were associated with the use of fibrin glue.

Conclusion: Compared to suturing, conjunctival autografting using fibrin glue shortens surgery time significantly, produces significantly less postoperative discomfort and inflammation with grafts being as stable as those secured with sutures.

Keywords: Pterygium; Conjunctival autografting; Fibrin glue; 10-0 nylon suture

INTRODUCTION

Pterygium is a degenerative condition of the subconjunctival tissues which proliferate as vascularised granulation tissue to invade the cornea. ⁽¹⁾ It remains an ophthalmic enigma, as the actual pathogenic

mechanisms of this condition remain unknown. ⁽²⁾ The difficulty in treating this deceptively benign disease stems from our lack of understanding of this condition, and its propensity for recurrence after surgical excision. There is a plethora of surgical and

medical measures currently available for pterygium, with no consensus regarding the 'ideal' treatment.⁽³⁾ Several surgical techniques have been described like bare sclera excision, excision with conjunctival closure/transposition, excision with antimetabolic adjunctive therapies like laser therapy, beta radiation, thiotepa, mitomycin-C and excision followed by ocular surface transplantation techniques like conjunctival autografting, amniotic membrane transplantation etc.^(3,4) Conjunctival autografting seems to be the best method since it is associated with very low rates of recurrence and complications when compared with other techniques.⁽⁵⁾ Kenyon et al introduced the technique of conjunctival autografting.⁽⁶⁾ Traditionally sutures have been used to secure the autograft. But suturing has the disadvantage of longer surgery time and complications such as granuloma formation, giant papillary conjunctivitis and significant patient discomfort after surgery.⁽⁷⁾ Lately fibrin based glues have been used to minimize operating time and discomfort. Cohen et al first described the use of fibrin glue during pterygium surgery.⁽⁸⁾ Since then several authors have reported about the safety and efficacy of fibrin glue but there have been varying reports regarding the recurrence rate. Here we performed a prospective comparative study to evaluate the outcome of fibrin glue versus sutures in a group of Indian patients.

MATERIALS AND METHODS

Study population

The study was conducted in the department of ophthalmology, Krishna Rajendra hospital, Mysore, between December 2011 and July 2013 after obtaining local Ethical Committee Clearance. 80 patients with primary nasal pterygium attending the outpatient department were enrolled in this study.

Inclusion criteria were patients with primary pterygium consenting for surgery and with any of the following indications for surgery – encroachment upon visual axis, inducing visually significant astigmatism of 1 D or more, causing recurrent inflammation or cosmetically bothersome to the patients. Exclusion criteria were recurrent pterygium, atrophic pterygium, patients on anticoagulants, patients with pre-existing glaucoma, patients with immune system disease, eyelid or ocular surface diseases e.g.- blepharitis, sjogren syndrome and dry eye and known hypersensitivity to any component of fibrin glue. Data was collected using a piloted proforma meeting the objectives of the study by means of personal interview with the patients, after informed consent. Routine ophthalmic examinations including visual acuity, slit lamp examination, fundus evaluation and keratometry readings were taken in all patients. In undilated eyes grading of the pterygium was done based on the following. Grade I- Head of the pterygium between limbus and a point midway between limbus and pupillary margin (P1). Grade II- Head of the pterygium present between point midway between limbus and pupillary margin (P1), and the pupillary margin (P2). Grade III- crossing pupillary margin.⁽⁹⁾

Fibrin Glue preparation

The fibrin glue used in the study was Tisseel fibrin sealant by Baxter, Vienna. Fibrinotherm was used for warming and mixing the components of the glue. A sealer protein concentrate (containing clottable protein and fibrinogen) was reconstituted in aprotinin solution and thrombin reconstituted in calcium chloride solution and mixed well. Each solution was withdrawn into a separate disposable syringe and the two syringes were mounted onto a duploject applicator, in which their contents were mixed in appropriate proportions. Since a single kit could be used to operate

on 10-13 patients and mixed glue could not be used beyond 4-6 hours, cases were pooled and 10 cases were operated using a single kit. This also made it a cost effective procedure, costing the patient almost the same as it would cost with suture.

Surgical technique

Patients were randomized to two groups. 40 patients underwent pterygium excision with conjunctival autografting using fibrin glue and 40 using 10-0 nylon sutures. All surgeries were performed by the same surgeon. All cases were taken up under peribulbar block using 2% lignocaine with 1: 1 lac epinephrine. Under aseptic precautions, wire lid speculum was applied. Pterygium excision was done either by avulsion technique or head of pterygium dissected from apex using surgical blade (No.15) taking care to follow the surgical plane of the pterygium followed by excision of the bulbar conjunctival extent. Underlying tenons was removed upto bare sclera. Minimal cautery was used when indicated. A thin tenon's free conjunctival graft was harvested from the superotemporal bulbar conjunctiva with the size being about 1 mm larger than the size of bare sclera. While covering the bare sclera with the graft, care was taken to maintain the limbus to limbus and stromal side down orientation. In 40 patients the grafts were secured with 4-6 sutures using 10-0 nylon. In the second group of 40 patients, 2 drops of fibrin sealant was placed on bare sclera and one drop on stromal side of graft followed by flipping of graft onto the bare sclera. Then gentle pressure was applied milking out any excess glue and free conjunctival margins were pressed. After 2 minutes, graft adhesion was confirmed. In all cases eye was bandaged after injecting dexamethasone and gentamicin subconjunctivally. The duration of surgery was calculated from the time of placing the lid speculum till its removal.

Follow-up

On first post operative day, bandage was removed and patients were started on steroid antibiotic eye drops 6 times a day. Follow up visits were at 1st week, 1st, 3rd and 6th months postoperatively. Any loose sutures were removed during the follow-up. Exposed or loose sutures were removed after 1 month. Steroid antibiotic drops were tapered depending on resolution of inflammation. On each follow-up visit patients were evaluated for degree of discomfort, inflammation, subconjunctival haemorrhage, graft stability and recurrence of pterygium. Pterygium recurrence was defined as any fibrovascular growth that has passed the limbus by more than 1 mm. The degree of discomfort was graded by the patients as follows. ⁽¹⁰⁾ Grade 0: None or no symptoms, Grade 1: Very mild or that symptom is easily tolerated, Grade 2: Mild or that symptom causes some discomfort, Grade 3: Moderate or that symptoms partially interferes with daily activities, Grade 4: Severe or that symptoms interferes completely with usual activities or sleep. The rest of the parameters were graded by an observer who was the same for all the 80 cases. The grading was as follows.

Grading of inflammation ⁽¹¹⁾

Grade 0: No dilated corkscrew vessel in graft, Grade 1: 1 bright red, dilated corkscrew vessel crossing the graft bed margin, Grade 2: 2 bright red dilated corkscrew vessels crossing the graft bed margin, Grade 3: 3 bright red dilated corkscrew vessels crossing the graft bed margin, Grade 4: ≥ 3 bright red dilated corkscrew vessels crossing the graft bed margin.

Grading of subconjunctival haemorrhage ⁽¹¹⁾

Grade 0- none, Grade 1- $\leq 25\%$ of size of the graft, Grade 2 - $\leq 50\%$ of size of the graft, Grade 3- ≤ 75 of size of graft, Grade 4- Haemorrhage involving the entire graft.

Grading of graft stability ⁽¹¹⁾

Grade 0: All four sides of the graft margin are well apposed, Grade 1: Gaping/displacement of one side of the graft-bed junction, Grade 2: Gaping/d is placement of two sides of the graft-bed junction, Grade 3: Gaping/ displacement of three sides of the graft-bed junction, Grade 4: Graft completely displaced from the bed.

Statistical Analysis

The statistical methods used were descriptive statistics, frequencies and percentages, crosstabs and independent-samples T test. All the statistical methods were carried out through the SPSS for Windows (version 16.0). A p value less than 0.05 was considered statistically significant.

RESULTS

All the 80 patients completed the follow-up. The mean duration of surgery in the fibrin glue group i.e.14.5 minutes (range 13-19 min) was found to be significantly shorter than that in suture group i.e. 26 minutes(range 21-30 min) (p=0.000). The fibrin glue group had significantly lesser postoperative discomfort compared to suture group at post-operative day 1 and week 1 (p=0.000 at both day 1 and week 1). The difference was not significant at 1st month post-operatively (p=0.077) and none of the patients in either group had any discomfort

at 3rd and 6th months. The fibrin glue group had significantly lesser postoperative inflammation compared to suture group at post-operative day 1 and week 1 (p=0.001 at both day 1 and week 1). None of the patients in either group showed any inflammation at 1st, 3rd and 6th months, except for 1 patient in suture group who had suture granuloma at 3rd month post-operative follow-up which was excised. No significant difference was found in the degree of postoperative sub conjunctival haemorrhage between the 2 groups at day 1 and week 1 (p=0.887 and p=0.797 respectively) . None of the patients had sub-conjunctival haemorrhage at 1st, 3rd and 6th months postoperatively. Conjunctival grafts secured with fibrin glue were as stable as those secured with sutures at day1, week 1, 1st, 3rd and 6th months postoperatively (p=0.745,p=0.644 at day 1 and week 1 respectively). The graft size in fibrin glue group tended to decrease slightly in the early postoperative period but stabilized later and was not associated with any dehiscence. 2 pterygium recurrences were noted in both the groups. No resurgery was required for these recurrent cases during follow-up. No side effects or complications were associated with the use of fibrin glue.

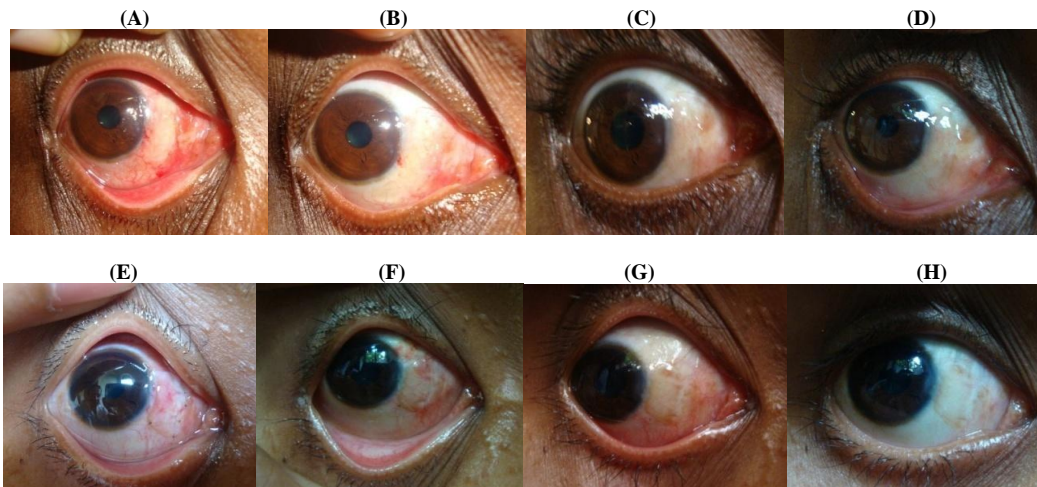


Figure 1: (A-D) Pictures of a patient in fibrin glue group at postoperative day 1, week 1, 1st month and 3rd month. (E-H) Pictures of a patient in suture group at postoperative day 1, week 1, 1st month and 3rd month.

Table 1: Patient characteristics in the two groups

	Fibrin glue group n = 40	10-0 nylon suture group n = 40
Mean age in years	42.4	38.8
Gender		
Male (%)	14(35%)	11(27.5%)
Female (%)	26(65%)	29(72.5%)
Laterality		
Right (%)	21(52.5%)	22(55%)
Left (%)	19(47.5%)	18(45%)
Pterygium grade		
Grade I (%)	10(25%)	12(30%)
Grade II (%)	26(65%)	24(60%)
Grade III (%)	4(10%)	4(10%)

DISCUSSION

Fibrin glue being biologic and biodegradable may be used under a superficial covering layer (e.g., conjunctiva, amniotic membrane) and induces minimal inflammation. ⁽¹²⁾ It was in early forties that fibrin glue was introduced to ophthalmology to fixate penetrating corneal grafts in rabbits. ⁽¹³⁾ Fibrin glue is a biological tissue adhesive which imitates the final stages of the coagulation cascade. ^(14,15) Tisseel (Baxter Immuno, Vienna, Austria) was the first fibrin sealant approved by the FDA for use in the USA. Fibrin sealant is now FDA approved for use as a topical hemostat, sealant and adhesive. ⁽¹⁶⁾ In India fibrin glue is available as Tisseel Fibrin Sealant (Baxter Vienna, Austria), and as reliseal (from Reliance life-sciences). ⁽¹⁷⁾

Tisseel (Baxter, Vienna, Austria) is a two component tissue adhesive which mimics the natural fibrin formation. This glue has two components. One consists of fibrinogen mixed with factor XIII and aprotinin. The other component is a thrombin-CaCl₂ solution. Equal amounts of the components are mixed together. Through the action of thrombin, the fibrinopeptides are split to fibrin monomers. These monomers aggregate by cross linking, resulting in a fibrin clot. ^(10,11) It has been used in neurosurgery, plastic surgery, ENT, and ocular surgery. In ocular surgery sealing perforations in the lens capsule,

treating conjunctival wounds and fistulas, conjunctival closure in strabismus surgery and retinal reattachment surgery and glaucoma surgeries, sealing corneal perforations, adapting free skin transplant in lid surgery, repairing injured canaliculi and sealing the wound in cataract surgery, use in pterygium are described. ⁽¹⁶⁻¹⁹⁾ Fibrin glue reduces the total surgical time, is better tolerated, non-toxic, has antimicrobial activity and is hypoallergenic. However high cost, risk of anaphylactic reactions and transmission of diseases (usually viral pathogens like parvovirus B19) are the drawbacks with its use. ⁽¹⁹⁾

Uy et al found that fibrin glue (Beriplast P) use results in shorter operating time and less postoperative discomfort compared to nylon 10-0 suture. ⁽²⁰⁾ Koranyi et al (Tisseel vs 7-0 vicryl), Karalezli et al (Tisseel vs 8-0 vicryl), Ozdamar et al (Tisseel vs vicryl), Marticorena et al also got similar results. ^(5,10,21,22) The results in our study were similar to that of above mentioned studies in terms of duration of surgery and degree of postoperative discomfort. Though the suture materials used in these studies were different, the results were similar maybe because as a study demonstrated, the postoperative discomfort using nylon sutures is comparable with the use of vicryl sutures. ⁽²³⁾

Srinivasan et al found that fibrin glue group had significantly less inflammation than suture group at 1 month and 3 months postoperatively whereas no significant difference was found at 1 week postoperatively. ⁽¹¹⁾ Our study showed significantly less inflammation in fibrin glue group at postoperative 1st day and 1st week with no difference at 1st month and later. Our results were similar to those got by Cha et al in their study. ⁽²⁴⁾ As Cha et al observed, this disparity may be explained by the use of different suture materials in the

studies. But in general all previous studies have demonstrated less inflammation in fibrin glue group.

Karalezli et al in their study reported significantly lower recurrence rate in the fibrin glue group ($p < 0.05$) with recurrence observed in 4% in glue group and in 12% in suture group. ⁽¹⁰⁾ They further opined that more severe inflammation may cause higher recurrence rates in suture cases and that the reduced postoperative inflammation and immediate adhesion of the graft with the use of fibrin glue may result in early graft vascularisation and prevent recurrence. In their study, Farid et al found lower recurrence rate in fibrin glue group with the difference being statistically significant. ⁽²⁵⁾ In the study by Cha et al there was no significant difference in the recurrence rates between the two groups. ⁽²⁴⁾ Thus the reports regarding recurrence rates have been inconsistent. Though the recurrence rate in the fibrin glue group in our study (5%) was comparable to recurrence rates reported in the literature for pterygium surgery with conjunctival autografting, a decreased recurrence rate with fibrin glue compared to sutures could not be demonstrated.

Our study had few drawbacks like the duration of follow-up being 6 months which is not long enough to document all recurrences. The recurrence in most cases is seen within 6 months, but can sometimes occur later. ⁽²⁶⁾ Secondly no blinding was followed. The observer who examined patients postoperatively at the slit lamp knew which were the glue cases and which were suture cases. There is a possibility of them being biased in their findings.

CONCLUSION

Compared to suturing, conjunctival autografting using fibrin glue shortens surgery time significantly, produces significantly less postoperative discomfort and inflammation with grafts being as stable

as those secured with sutures. Thus, as found in various studies worldwide, it might be considered as a better alternative to sutures even in Indian patients.

REFERENCES

1. Sihota R, Tandon R. Diseases of the conjunctiva. In: Parson's Diseases of the Eye. 21st ed. New Delhi : Elsevier; 2011.
2. Coster D. Pterygium - an ophthalmic enigma. *Br J Ophthalmol* 1995; 79(4) : 304-305.
3. Tan D , Chan C. Management of pterygium. In : Krachmer JH, Mannis MJ, Holland EJ. Cornea – Fundamental diagnosis and management, 3rd ed. Philadelphia: Mosby Elsevier; 2011.
4. Waller SG, Adamis AP. Pterygium. In: Duane's foundations of clinical ophthalmology, vol 6. Philadelphia: Lippincott, Williams and Wilkins; 2003.
5. Koranyi G, Seregard S, Kopp ED. Cut and paste: a no suture, small incision approach to pterygium surgery. *Br J Ophthalmol*. 2004 Jul;88(7):911-914.
6. Kenyon KR, Wagoner MD, Hettlinger ME. Conjunctival autograft transplantation for advanced and recurrent pterygium. *Ophthalmology* 1985 Nov;92(11):1461-1470.
7. Starck T, Kenyon KR, Serrano F. Conjunctival autograft for primary and recurrent pterygia: surgical technique and problem management. *Cornea* 1991;10:196-202.
8. Cohen RA, McDonald MB. Fixation of conjunctival autografts with an organic tissue adhesive (letter). *Arch Ophthalmol* 1993;111:1167-8.
9. Maheshwari S. Pterygium-induced corneal refractive changes. *Indian J Ophthalmol*. 2007 Oct;55(5):383-386.
10. Karalezli A, Kucukerdonmez C, Akova YA, et al. Fibrin glue versus sutures for conjunctival autografting in pterygium surgery: a prospective comparative study. *Br J Ophthalmol*. 2008 Sep;92(9):1206-1210.

11. Srinivasan S, Dollin M, McAllum P, et al. Fibrin glue versus sutures for attaching the conjunctival autograft in pterygium surgery: a prospective observer masked clinical trial. *Br J Ophthalmol*. 2009 Feb;93(2):215-218.
12. Chan SM, Boisjoly H. Advances in the use of adhesives in ophthalmology. *Curr Opin Ophthalmol* 2004;15:305-10.
13. Katzin HM. Aqueous fibrin fixation of corneal transplants in the rabbit. *Arch Ophthalmol*. 1946; 35(4):415-420.
14. Thompson DF, Letassy NA, Thompson GD. Fibrin glue: a review of its preparation, efficacy, and adverse effects as a topical hemostat. *Drug Intell Clin Pharm*. 1988 Dec;22(12):946-952.
15. Le Guéhennec L, Layrolle P, Daculsi G. A review of bioceramics and fibrin sealant. *Eur Cell Mater*. 2004;8:1-11.
16. Park HC, Champakalakshmi R, Panengad PP, et al. Tissue adhesives in ocular surgery. *Expert review of ophthalmology* 2011;6:631-55.
17. Vyas S, Kamdar S, Vyas P. Tissue adhesives in ophthalmology. *Journal of Clinical Ophthalmology and Research* 2013;1(2):107-112.
18. Sinha R, Kumar C, Sharma N. Use of tissue adhesives in ophthalmology. *Indian J Ophthalmol* 2009; 57 : 409-13.
19. Panda A, Kumar S, Kumar A, et al. Fibrin glue in ophthalmology. *Indian J Ophthalmol*. 2009;57:371-9.
20. Uy HS, Reyes JMG, Flores JDG, et al. Comparison of fibrin glue and sutures for attaching conjunctival autografts after pterygium excision. *Ophthalmology* 2005 April;112(4):667-671.
21. Ozdamar Y, Mutevelli S, Han U, et al. A comparative study of tissue glue and vicryl suture for closing limbal-conjunctival autografts and histologic evaluation after pterygium excision. *Cornea*. 2008 Jun;27(5):552-558.
22. Marticorena J, Rodríguez-Ares MT, Touriño R, et al. Pterygium surgery: conjunctival autograft using a fibrin adhesive. *Cornea*. 2006 Jan;25(1):34-36.
23. Wong VW, Rao SK, Lam DS. Polyglactin sutures versus nylon sutures for suturing of conjunctival autograft in pterygium surgery: a randomized, controlled trial. *Acta Ophthalmol Scand* 2007;85:658-61.
24. Cha DM, Kim KH, Choi HJ, et al. A comparative study of the effect of fibrin glue versus sutures on clinical outcome in patients undergoing pterygium excision and conjunctival autografts. *Korean J Ophthalmol*;2012 Dec; 26(6): 407-413.
25. Farid M, Pirnazar JR. Pterygium recurrence after excision with conjunctival autograft: a comparison of fibrin tissue adhesive to absorbable sutures. *Cornea* 2009 Jan;28(1):43-45.
26. Hirst LW, Sebban A, Chant D. Pterygium recurrence time. *Ophthalmology* 1994;101:755- 8.

How to cite this article: Priya VR, Hegde SS. A prospective comparative study to evaluate the outcome of fibrin glue versus sutures for conjunctival autografting after primary pterygium excision. *Int J Health Sci Res*. 2015;5(1):93-99.
