



Case Report

Type II Usher's Syndrome - A Case Report

Privila E¹, SM Shivshankaraiah²

¹Junior Resident, ²Professor,
Department of Ophthalmology, KVG Medical College Hospital, Sullia, Karnataka.

Corresponding Author: Privila E

Received: 24/06/2014

Revised: 22/07/2014

Accepted: 30/07/2014

ABSTRACT

Usher's syndrome is responsible for the majority of deaf blindness. It is the most common form of the syndromes associated with retinitis pigmentosa. People with Usher's syndrome represent one sixth of people with retinitis pigmentosa. The prevalence of Usher's syndrome is thought to be 3 cases per 100,000. It is inherited in an autosomal recessive pattern. It is divided clinically into 3 major groups: Type I, Type II and Type III. We hereby report a case of Type II Usher's syndrome.

Keywords: Usher's syndrome diagnosis, Retina /pathology, visual acuity

INTRODUCTION

Usher syndrome is defined as autosomal recessive deafness with retinopathy indistinguishable from typical RP. Not all retinitis pigmentosa patients affected by impaired hearing have Usher's syndrome. Any patient with retinal degeneration for whom there is a suspicion of even slight hearing loss must receive audiologic evaluation and treatment to minimize the effect of major sensory problems that arise from combined hearing and vision deficits.

CASE REPORT

A 32 year old female housewife presented to us with complaints of diminished hearing since childhood and diminution of vision both eyes more at night since 15 years.

Diminution of vision was insidious in onset, gradually progressive and painless. There was no history of use of spectacles or hearing aids. No history of difficulty in walking. She was born out of a non consanguineous marriage.

On examination Anterior segment of both eyes was found to be within normal limits; Pupils of both eyes were 3mm in size, Round, regular and reactive. Ophthalmoscopy of both eyes showed clear media, waxy gliotic pallor of both optic discs, severe thread like arteriolar attenuation and bone spicule retinal pigmentation in the midperiphery, characteristic of Retinitis pigmentosa. Colour vision was found to be normal.

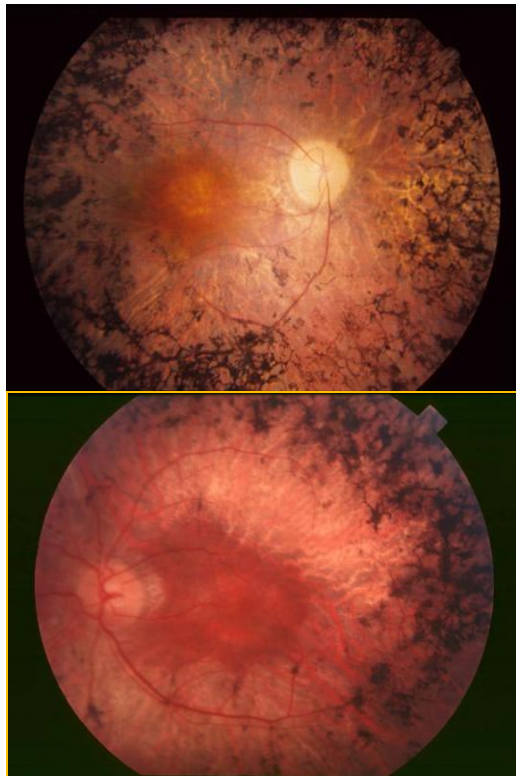


Figure1: Fundus photographs showing waxy gliotic pallor of optic disc, arteriolar attenuation and bone spicule pigmentation in the mid periphery of the fundus.

UCVA in both eyes was 5/60 N6; Pinhole improvement in both eyes was 6/12 N6
 BCVA in both eyes was 6/12 N6 With - 2.0DS. Pedigree charting was done and was found that no family members were affected. ERG was done and showed subnormal 'a' wave and 'b' wave.
 ENT consultation was done and vestibular functions were found to be normal.

Audiogram was ordered which revealed moderately severe Sensorineural hearing loss of 59.9dB both ears.

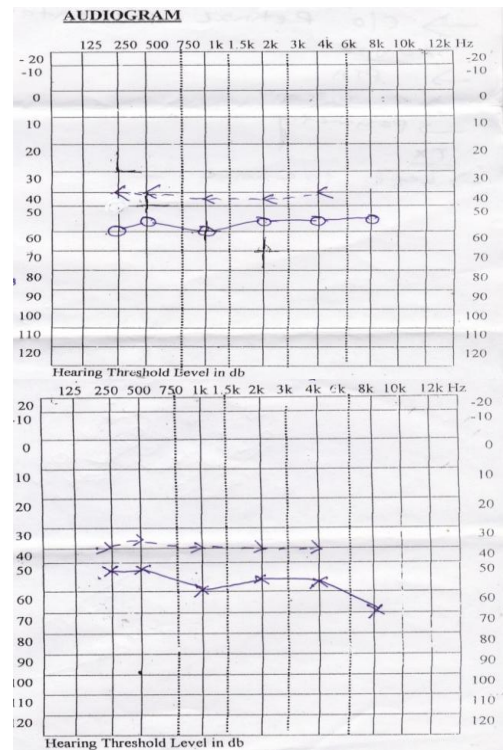


Figure 2: showing audiogram with moderately severe sensorineural hearing loss

Medicine consultation was done to rule out other systemic involvement. ECG was taken which did not show any conduction defects.

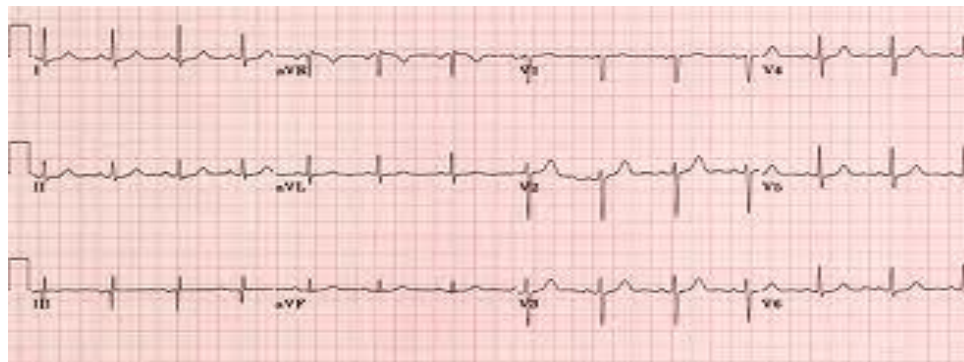

FIGURE 3: Normal ECG

Putting together all these findings a diagnosis of Type II Usher's syndrome was made. This patient was prescribed spectacles of -2.00DS spectacles. Vitamin A therapy started. Advised follow up after 6 months.

DISCUSSION

Usher's syndrome was described by Albert von Grafe but was named after the British ophthalmologist Charles Usher in 1914 for the appreciation that this condition was familial and represent a distinct entity. The Usher consortium has recommended specific clinical criteria for the diagnosis of Usher's syndrome. [1]

Classification

Usher's syndrome can be divided in to three major groups; Type 1, Type 2, Type 3

Characteristics

The two most frequent forms are Type1, with profound congenital sensorineural hearing loss and resultant prelingual deafness or severe speech impairment, vestibular symptoms, childhood onset retinopathy and Type 2,with congenital, partial , non progressive deafness, absence of vestibular symptoms and late onset retinopathy. The least common is Type 3 Usher's syndrome, which is characterized by progressive deafness starting in late , in the second to fourth decades, adult onset retinopathy, and hypermetropic astigmatism [2] Onset of nyctalopia is late in Type 2 compared to type 1. Visual acuity is retained in older patients with Type 2 Usher's syndrome than in Type 1 and Type 3. ERG is found to be profoundly abnormal to non detectable in all the types. [3]

Pathology

Congenital neurosensory deafness and RP might seem to have little in common pathologically. However the photoreceptors of the retina and hair cells of the inner ear are each ciliated neuroepithelial cells.

Spermatozoa, photoreceptors and inner ear hair cells all contain axonemes. Hunter et al found abnormal axonemes in sperm from subjects with Usher's syndrome and abnormal axonemes on histological examination of retinal sections from a patient with Usher's syndrome. [4] Connor et al found that spermatozoa from patients with Usher's syndrome Type 2 had an abnormal lipid composition that was associated with reduced mortality. [5] These findings suggest that both the cilium of the inner ear and the cilium of the photo receptors may share axonemal components that are necessary for formation of ciliated structures and whose genes would be candidates for the defective gene in Usher's syndrome.

Genetics

Yao SF et al found that mutations in the *USH2A* gene on chromosome 1q41 appear to be responsible for most cases of Usher type II. The gene has 21 exons and codes for usherin, a novel protein whose structure is partially homologous with the laminin protein group. The function of usherin is not yet understood but it has been postulated that it is a cell adhesion molecule or forms part of the basement membrane. The genomic structure of *USH2A* has been determined and several new *USH2A* mutations have recently been found. [6]

Differential diagnosis

Other syndromes that can be associated with pigmentary retinopathy and deafness must be contemplated when considering a diagnosis of Usher's syndrome. These include infantile Refsum disease, adult Refsum disease, Cockayne syndrome, Bardet Biedl syndrome, Alstrom disease, Kearns Sayre syndrome.

Treatment

The diagnosis of retinitis pigmentosa as part of Usher's syndrome can be made in early life with ERG testing. No tests of

retinal function are yet available to identify carriers of Usher's syndrome.

Patients with Usher's syndrome appear to have a slowly progressive retinal degeneration.

Currently, there is no cure for Usher's syndrome. The best treatment involves early identification so that educational programs can begin as soon as possible. Typically, treatment will include hearing aids, assistive listening devices, cochlear implants, or other communication methods; orientation and mobility training; and communication services and independent-living training that may include Braille instruction, low-vision services, or auditory training. Berson et al found that Patients with Usher's syndrome Type II may reasonably be treated with vitamin A palmitate 15,000 IU per day because these patients were included among those with autosomal recessive retinitis pigmentosa in a clinical trial of vitamin A for retinitis pigmentosa. [7]

Research into an effective treatment for Usher's Syndrome is focused on four main areas, gene therapy, retinal implants, stem cell therapy and drug-based therapy.

Since retinitis pigmentosa arises as a consequence of mutations in many genes, one rational approach to therapy relies on correcting the genetic defect. This involves delivering a normal copy of the specific affected gene to the retina with a virus vector or other delivery method. After Bainbridge et al proved the efficacy of gene therapy in autosomal recessive Leber congenital Amaurosis (LCA) from mutations in the RPE65 gene this was extended to a human RPE65 trial, with preliminary evidence of benefit to visual function. This method would be applicable when both copies of the gene harbor mutations, as in recessive retinitis pigmentosa. [8,9]

Tao W et al showed the safety of Ciliary Neurotrophic Factor (CNTF) delivered by encapsulated cell technology in patients with advanced retinitis pigmentosa. [10]

Other proposed therapies include optical devices to allow patients improved mobility despite constricted fields and visual prosthetic devices such as the light sensitive microchip for advanced degenerations. Stem cell mediated therapy is being considered for macular degeneration or retinitis pigmentosa. It may also be possible to replace defective retinal pigment epithelium with transplanted normal pigment epithelium or stem cells and thereby benefit some patients with these conditions. [11]

CONCLUSION

Investigation of Usher's syndrome in patients with hearing loss and impaired vision in dark will promote better rehabilitation and monitoring of patients. Consanguinity should be sought in affected individuals. Our case report shows a patient with deafness and blindness diagnosed to be Type 2 Usher's syndrome. So any patient with retinal degeneration for whom there is suspicion of even slight hearing loss must receive audiologic evaluation and treatment to minimize the effect of major sensory problems that arise from combined hearing and vision deficits.

REFERENCES

1. Smith R.J.H.,Berlin C.I.,Hejtmancik J.F., et al. Clinical diagnosis of Usher's syndrome,Usher's syndrome consortium. Am J Med Genet 1994; 50:32-8
2. Fishman G. A.,Kumar A, Joseph .M.E., et al. Usher's syndrome:Ophthalmic and neuro otologic findings suggesting genetic heterogeneity.Arch Ophthalmol 1983;101:1367-74
3. HunterD.G., FishmanG.F., Mehta R.S., et al. Abnormal sperm and

- photoreceptor axonemes in Usher's syndrome. Arch Ophthalmol 1986;104:385-9
4. Connor W.E., Welberg, De Francesco C, et al. sperm abnormalities in Retinitis pigmentosa. Invest ophthalmol Vis Sci 1997;38:2619-26.
 5. Tsilou, Benjamin, Rubin, et al. Usher syndrome clinical types I and II: Could ocular symptoms and signs differentiate between the two types?. Acta ophthalmol scand 2002; 80:196-201
 6. Eudy JD, Weston MD, Yao SF, et al. Mutation of a gene encoding a protein with extracellular matrix motifs in USH2A. Science 1998; 28:1753-7
 7. Berson EL, Rosner B, Sandberg MA et al. A randomized trial of vitamin A and vitamin E supplementation for retinitis pigmentosa. Arch Ophthalmol 1993;111:761-72
 8. Bainbridge J.W.B., Smith A.J., Barker S.S., et al. Effect of gene therapy on visual function in Leber's congenital amaurosis. N Engl J Med 2008; 358:2231-9.
 9. Maguire A.M., Simonelli F., Pierce E.A., et al. Safety and efficacy of gene transfer for Leber's congenital amaurosis. N Engl J Med 2008; 358:2240-8.
 10. Sieving P.A., Caruso R.C., Tao W., et al: Ciliary neurotrophic factor (CNTF) for human retinal degeneration: phase I trial of CNTF delivered by encapsulated cell intraocular implants. Proc Natl Acad Sci U S A 2006; 103:3896-901.
 11. Berson EL. Retinal degenerations: Planning for the future In: Anderson RE, LaVail MM, Hollyfield JG, ed. Recent Advances into Retinal Degeneration Research, New York: Springer; 2007.13

How to cite this article: Privila E, Shivshankaraiah SM. Type II usher's syndrome - a case report. Int J Health Sci Res. 2014;4(8):280-284.

International Journal of Health Sciences & Research (IJHSR)

Publish your work in this journal

The International Journal of Health Sciences & Research is a multidisciplinary indexed open access double-blind peer-reviewed international journal that publishes original research articles from all areas of health sciences and allied branches. This monthly journal is characterised by rapid publication of reviews, original research and case reports across all the fields of health sciences. The details of journal are available on its official website (www.ijhsr.org).

Submit your manuscript by email: editor.ijhsr@gmail.com OR editor.ijhsr@yahoo.com