



Case Report

Navicular Bump and Recalcitrant Pain - An Unusual Etiology

Ganesh Singh Dharmshaktu, Anshuman Vijay Roy, Tariq Akhtar Ansari

Govt. Medical College, Haldwani, Uttarakhand, India.

Corresponding Author: Ganesh Singh Dharmshaktu

Received: 29/05/2014

Revised: 26/06/2014

Accepted: 30/06/2014

ABSTRACT

Chronic mid-foot pain have several etiological factors and related treatment protocols. Most of the times, the treatment is limited to supportive and symptomatic therapy. Physical therapy measures are ancillary modalities along with activity modifications. A very localized chronic pain refractory to conservative treatment options warrants imaging studies to delineate underlying pathology. On rare instances very interesting underlying lesions are encountered. We present a case report of recalcitrant pain over medial aspect of foot diagnosed radiologically and managed accordingly.

Key Words: Bone Diseases, Osteochondritis, Navicular Bone of Foot.

INTRODUCTION

Mueller Weiss syndrome is an osteochondritic lesion affecting tarsal navicular bone. It can have presentations from asymptomatic dormancy to serious morbidity. A high index of suspicion and help of advance imaging modalities like magnetic resonance imaging is helpful in diagnosis and subsequent management. The treatment is personalized and symptom specific.

CASE REPORT

A lady aged 52 years presented to us with history suggesting off an on pain over medial aspect of her right foot since last seven years. The pain is not constant and was related to increased severity on prolonged use of the limb such as in standing or walking. She had otherwise no complaint and history of 'red flags'

suggesting any traumatic, infective or neoplastic disorder. The pain had interfered with her activities of daily living when severe. Pain was relieved by rest as well as partially on taking pain medications by the patient. She had noticed a bump on medial aspect of her right foot corresponding to the area of navicular bone before the pain and present complaint started. She could not exactly tell the starting of noticing the bump but it was about ten years ago.

On examination, the localized swelling was mildly tender with no localized temperature discrepancy. The swelling seemed to be localized to the navicular area and other tarsal bones were normal. Range of motion of toes and ankle joints were within normal limits. Distal neurovascular examination was unremarkable. There was flatness of bilateral feet but was flexible and got corrected when patient was asked to bear

weight on toes and try to hold her upright . The foot was otherwise normal with regard to skin and soft tissue concerns apart from flexibility and alignment.

Radiograph of the patient was unremarkable except localized osteoporosis of navicular region but the contour, height and anatomy was maintained.

RESULT

The case had chronic but only mild pain that was increased on prolonged standing and walking. She was explained the natural history of the disease and various treatment options. After the informed consent she chose for bone marrow injection intra-lesional with guarded prognosis.

She was given autologous bone marrow injection procured from iliac crest and approximately 10 ml. of the product was injected intralesionally under fluoroscopic guidance. A short leg plaster of paris splintage was given for ten days for immobilization and pain relieve. Her post procedure Visual Analogue Score and 100 point Numerical Rating Scale were

encouraging with 94 percent improvement in pain profile on seventh day. The pain relief was associated with improved gait and walking distance parameters. The patient was painfree and showed no fresh complaints as reviewed after twelve weeks, three and six months post- procedure. She was well explained of the future course and complications of the disease and regular periodic followup for future management of the disease.

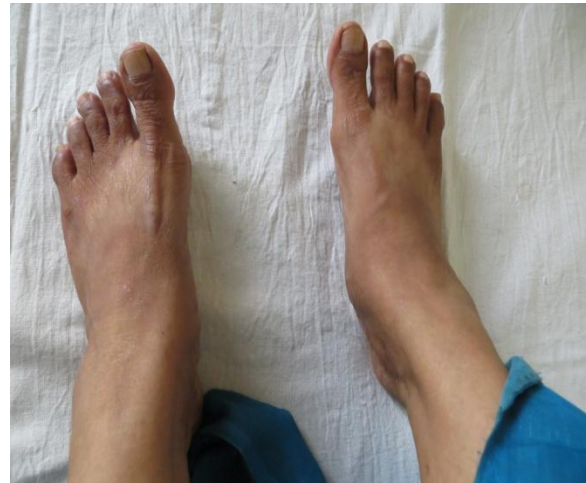

Fig 1. Clinical picture showing right navicular bump.

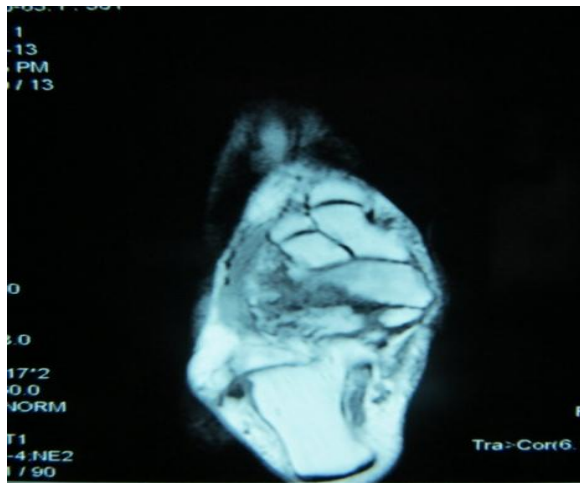


Fig 2 . MRI of the foot showing characteristic lateral column Collapse.

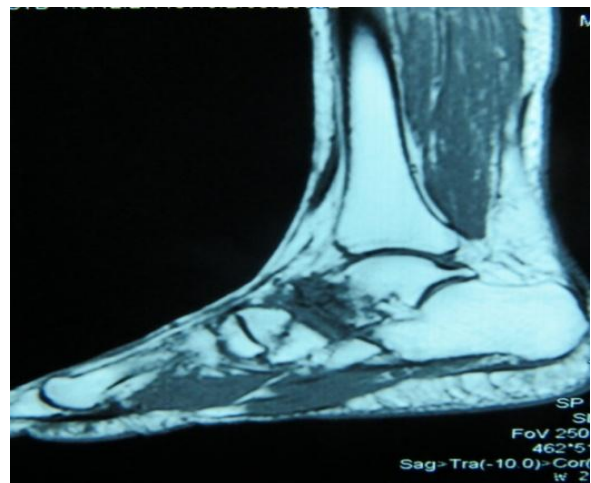


Fig 3. MRI saggittal view delineating the lesion.

DISCUSSION

Mueller –Weiss Syndrome is an uncommon disease affecting the tarsal

navicular bone, characterized by spontaneous osteonecrosis of lateral column. It subsequently manifests as pan-navicular

arthritis and variable mid foot pain. [1] It is considered to be an adult counterpart of Kohler's disease with circulatory interruptions cited as predisposing factors. [2]

The condition at initial stages has been treated with various conservative methods or navicular decompression. Late stages are described to be treated with excision of the sclerotic bone and medial column arthrodesis with bone grafts. [3,4]

CONCLUSION

Intralesional bone marrow injection is minimal invasive option for mild disease for initial pain and disability management, however no literature support could be found in this regard by the authors. It however proved to be an attractive modality of treatment and should be tried before proceeding to the other invasive surgical options.

REFERENCES

1. Tosun B, Al F, Tosun A. Spontaneous osteonecrosis of the tarsal navicular in an adult: Mueller-Weiss syndrome: J Foot Ankle Surg. 2011; 50(2):221-4.
2. Reade B, Atlas G, Distazio J, Kruljac S. Mueller-Weiss syndrome: an uncommon cause of midfoot pain. J Foot Ankle Surg. 1998. 37(6):535-9.
3. G. Janositz, K. Sisák, K. Tóth . Percutaneous decompression for the treatment of Mueller-Weiss syndrome. Knee Surgery, Sports Traumatology, Arthroscopy. Volume 19, Issue 4, pp 688-690.
4. Kumar VK, Renuka Mohan. Mueller - Weiss Syndrome: An uncommon cause of midfoot pain. Kerala Journal of Orthopaedics. 2011; 24:40-42.

How to cite this article: Dharmshaktu GS, Roy AV, Ansari TA. Navicular bump and recalcitrant pain - an unusual etiology. Int J Health Sci Res. 2014;4(7):266-268.

International Journal of Health Sciences & Research (IJHSR)

Publish your work in this journal

The International Journal of Health Sciences & Research is a multidisciplinary indexed open access double-blind peer-reviewed international journal that publishes original research articles from all areas of health sciences and allied branches. This monthly journal is characterised by rapid publication of reviews, original research and case reports across all the fields of health sciences. The details of journal are available on its official website (www.ijhsr.org).

Submit your manuscript by email: editor.ijhsr@gmail.com OR editor.ijhsr@yahoo.com