

*Case Report***Adenomatoid Tumor of Epididymis - A Case Report**

Rajshri Pisaram Damle, Kishor Hiranman Suryawanshi, Nandkumar V Dravid, Dhananjay V Newadkar,
Arundhati S Gadre

A.C.P.M. Medical College, Dhule, Maharashtra, India.

Corresponding Author: Rajshri Pisaram Damle

Received: 24/03/2014

Revised: 17/04/2014

Accepted: 21/04/2014

ABSTRACT

Adenomatoid tumor (AT) is a rare benign mesothelial neoplasm of the paratesticular region and mainly involves the epididymis. A definitive diagnosis of this tumor is important because it is difficult to differentiate clinically and radiologically from other intrascrotal pathology and malignancy. Histopathological examination along with immunohistochemistry is diagnostic and conclusive for diagnosis of paratesticular tumor.

Herein, we report a case of 53-year-old male who presented with paratesticular mass. Surgical excision was performed and histopathological examination confirmed the diagnosis of adenomatoid tumor of the epididymis.

Key words: adenomatoid tumor, epididymis, paratesticular mass

INTRODUCTION

Paratesticular neoplasms are rare and accounts for less than 10% of all intrascrotal tumors and most of them are benign in nature. [1] Adenomatoid tumor is a benign mesothelial neoplasm of the paratesticular tissue, accounting for approximately 30% of them and occasionally occurs as an intratesticular mass. [2] Most common sites of adenomatoid tumor are male and female genital tract. [3] Mostly these tumors are asymptomatic, benign in nature and presents as a small mass in the genital area so it requires a definitive diagnosis to rule out other intrascrotal pathology and malignancy.

Herein, we describe a case of 53-year-old male who presented with adenomatoid tumor of epididymis.

CASE REPORT

A 53-year-old male patient presented with a swelling in the right side of his scrotum since 6 months. He had no complaints of pain, tenderness and no history of trauma. On clinical examination swelling was located on the lower pole of testis but was felt separate from the right testis. Swelling was 2cmx1cm in size, smooth and firm in consistency. Personal and family history was unremarkable. Scrotal skin, spermatic cord, inguinal region and left testis were normal.

Ultrasonography showed a solid mass 2x1cm with iso-echoic area lying between epididymal tail and lower pole of right testis without any disruption of the architecture of the testicular parenchyma

suggestive of paratesticular tumor. Preoperative laboratory investigations including complete blood count, blood chemistry studies were within normal limits. The patient underwent excisional biopsy and specimen was sent for histopathological examination. Grossly received single encapsulated nodular mass measuring 2cm x 1cm with smooth appearance. Cut surface showed solid and greyish white nodule (Figure 1). Microscopically tumor cells were arranged in cords, tubules separated by fibro-connective tissue and lined by cuboidal to flattened epithelium with large intracytoplasmic vacuoles. The intervening stroma showed abundant fibrous tissue and smooth muscle (Figure 2 -4). Masson's trichrome stain revealed the presence of

fibrous tissue and smooth muscle in intervening stroma (Figure 5). Histological diagnosis of adenomatoid tumor of epididymis was made. Immunohistochemistry revealed positive staining for calretinin.

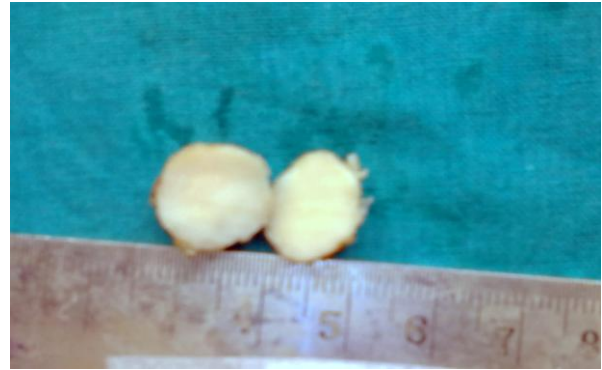

Figure 1: Cut section showing solid, greyish white tumor mass.

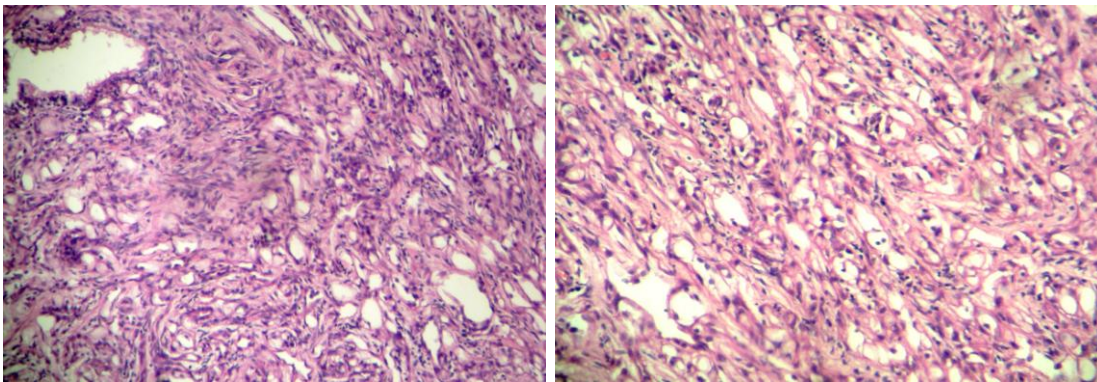


Figure 2& 3: Tumor showing characteristic tubular or nesting pattern (H & E X100)

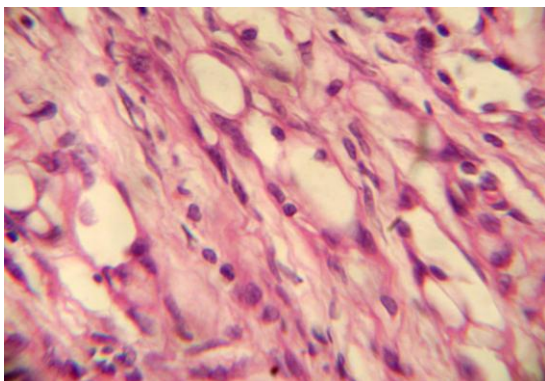


Figure 4: Tumor cells are arranged in tubulers and cords lined by cuboidal to flattened epithelium with characteristic vacuolated cytoplasm (H & E X 400)

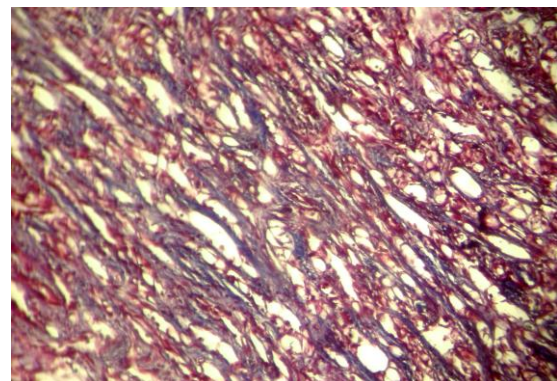


Figure 5: Masson's trichrome stain shows presence of fibrous tissue and smooth muscle in intervening stroma.

On the basis of histomorphological and immunohistochemical study, final diagnosis

of adenomatoid tumor of epididymis was given. Postoperative period was uneventful

and patient is free from local recurrence in the 6month follow-up after surgery.

DISCUSSION

Paratesticular tumors are rare and benign in nature with adenomatoid tumor being the commonest one. [4] Epithelial tumors of epididymis are a rare subtype mainly composing of adenomatoid, papillary cystadenoma and leiomyoma. [1,3]

Adenomatoid tumor is the most common neoplasm of the epididymis and was first described in 1945 by Golden et al as a small, firm, asymptomatic mass in scrotal region without pain and tenderness. [5,6]

Adenomatoid tumor may be seen in all ages but most cases are seen in the third to fifth decades of life. [3] Age group of patient reported in the literature ranged from 18-80 years. [7] Adenomatoid tumor affects epididymis, spermatic cord, prostate and ejaculatory ducts in males and uterus, fallopian tube, ovary in females. [3] But it may also involve adrenals, lymph node, pancreas, mediastinum and pleura. [8]

The origin of the adenomatoid tumor is not clear. The cell of origin could be mesothelial, mesonephric, mullerian and endothelial. In the literature, variety of theories indicate that adenomatoid tumor is of mesothelial nature, as originally proposed by Masson et al. [9] The structural and immunohistochemical studies support the mesothelial origin. On electron microscopy, it can present 3 basic patterns- tubules, cell nests and cords. Prominent microvilli, desmosomes and tonofilaments are highly suggestive of adenomatoid tumor of epididymis. [10] Ultrasonography revealed the solid nature of the lesion which may be hyper-echoic, iso-echoic, hypo-echoic or it may adopt any morphology.

Clinically, patient presents as small, solid intrascrotal mass which are found incidentally. Rarely adenomatoid tumor of epididymis is associated with pain and

sometimes confused with torsion of testis. Predominantly it is located on the left side than the right side and occurs in or near the lower pole or upper pole of the epididymis. A slightly higher incidence in the lower pole has been reported. [11] Mostly adenomatoid tumor present as slow growing and smaller in size ranging from 1-5cm but few cases also reported upto 12 cm. [9] In our case right lower pole of epididymis is involved and size of tumor is 2 cm.

Microscopically, adenomatoid tumor shows epithelial like cells forming solid cords, tubules and micro cystic spaces with cuboidal or flattened epithelium. Vacuolated cytoplasm is a predominant feature of the cells. The stroma is usually fibrous and may contain smooth muscle. Differential diagnosis includes leiomyoma, papillary cystadenoma, haemangioma, metastatic carcinoma, malignant mesothelioma and carcinoma of rete testis. Histomorphological and immunohistochemical features (calretinin and HMBE1) of these tumors support their mesothelial origin.

Based on review of literature treatment of adenomatoid tumor is surgical excision and no cases of recurrence or metastasis have been reported. [12]

CONCLUSION

Adenomatoid tumor of epididymis is an uncommon benign neoplasm and sometimes confused with testicular neoplasm. Accurate diagnosis is important for surgical management to prevent unnecessary surgical intervention.

Conflicts of Interest:

The authors declare that there are no conflicts of interest.

REFERENCES

1. Moyano CJL, Giraldez PJ, Sanchez de la Vega J, et al. Adenomatoid

- tumour of the epididymis. *Actas Urol Esp* 2007; 31: 417-419.
2. Davis CJ, Woodward PJ, Dehner LP et al. Tumors of paratesticular structures. In: Eble JN, Sauter G, Epstein JI et al. WHO classification of tumors. Pathology and genetics of tumors of the urinary system and male genital organs. Lyon: IARC press, 2004;267-76
 3. Samada A A, Pereiroa B, Badiola A, Gallegoc C, Zungria E. Adenomatoid tumour of intratesticular localization. *Eur Urol* 1996; 30: 127-28.
 4. Kuhn MT and MacLennan GT. Benign neoplasms of the epididymis. *Journal of Urology* 2005;174:723.
 5. Kalyani R, Das S. Adenomatoid tumor: Cytological diagnosis of two cases. *J Cytol* 2009;26:30-32
 6. Manjunath GV, Nandini NM. Fine needle aspiration cytology of adenomatoid tumor- a case report with review of literature. *Indian J Pathol Microbiol* 2005;48:503-504
 7. Maestro MA, Gonzalez RT, Dorrego MA, Barthel JDP, De Serrano MN
 8. Timonera ER, Paiva ME, Lopes JM, Eloy C, van der Kwast T, Asa SL. Composite adenomatoid tumor and myelolipoma of adrenal gland: report of 2 cases. *Arch Pathol Lab Med* 2008; 132:265-7.
 9. Rosai J. Male reproductive system. In: Rosai J, editor. *Rosai and Ackerman's Surgical Pathology*. Mosby: St. Louis, 2005;1361-1482
 10. Davy CL, Tang CK. Are all adenomatoid tumours adenomatoid mesothelioma. *Hum Path* 1981; 12(4): 360-69.
 11. Srigley JR, Hartwick RWJ. Tumours and cysts of the paratesticular region. *Pathol Annu* 1990; 25: 51-108.
 12. Plas E, Riedl CR, Pfluger H: Malignant mesothelioma of the tunica vaginalis testis: review of the literature and assessment of prognostic parameters. *Cancer* 1998, 83:2437-46.

How to cite this article: Damle RP, Suryawanshi KH, Dravid NV et. al. Adenomatoid tumor of epididymis - a case report. *Int J Health Sci Res.* 2014;4(5):310-313.

International Journal of Health Sciences & Research (IJHSR)

Publish your work in this journal

The International Journal of Health Sciences & Research is a multidisciplinary indexed open access double-blind peer-reviewed international journal that publishes original research articles from all areas of health sciences and allied branches. This monthly journal is characterised by rapid publication of reviews, original research and case reports across all the fields of health sciences. The details of journal are available on its official website (www.ijhsr.org).

Submit your manuscript by email: editor.ijhsr@gmail.com OR editor.ijhsr@yahoo.com