

Supratentorial Gliomas: A Review of Neurosurgical Management, Technological Advancements and New Therapeutic Interventions

V K S Gautam¹, Ravinder Singh²

¹Assistant Professor, Department of Neurosurgery,

²Associate Professor & Head, Department of Medical Anthropology,

IHBAS Hospital, Faculty of Medical Sciences, University of Delhi, GNCT Delhi, Dilshad Garden, Delhi-95

Corresponding Author: Ravinder Singh

Received: 21/11/2013

Revised: 03/01/2014

Accepted: 08/01/2014

ABSTRACT

Introduction: Generally Supratentorial tumors are glial in origin. Their management is challenging despite of various advancements. Therefore, there is need to integrate various diagnostic and therapeutic modalities to achieve best clinical outcome following neurosurgical interventions.

Objective: Paper aims to review recent advances in the field of neuroimaging, operative techniques, intra-operative technologies, chemoradiation and other modalities of therapeutic interventions affecting the prognosis of supratentorial gliomas.

Materials and Methods: Pre and post operative clinical evaluation, psychological assessment, neuroimaging with CT scan, or MRI brain with contrast and or MR spectroscopy were done in 18 patients of supratentorial gliomas operated and followed up in last 3 years. Per operative frozen section biopsy was obtained in each case.

Results: Seizures and headache were common presentation of supratentorial gliomas. Craniotomy and tumor decompression were common neurosurgical intervention. MRI brain with contrast enhancement was the main modality of investigation in the preoperative and post operative evaluation of these patients. Pre operative frozen section biopsy guided the extent of the tumor resection. Majority of patients had shown significant neurological improvement after surgery.

Conclusion: Pre-operative neurological status of the patient, neuroimaging, per-operative frozen section biopsy, histopathological grade of the tumor has guided treatment of supratentorial gliomas. Various technological advancements e.g. PET scan, functional MRI, intra operative ultra sonogram, intra operative MRI and other technologies, advances in chemoradiation, immunotherapy, molecular based therapy and other newer therapeutic interventions have been reviewed for better clinical outcome. In view of recent advances it is imperative to establish an evidence based guideline for the comprehensive management.

Keywords: Gliomas, Neuroimaging, Supratentorial

INTRODUCTION

Glioma is the most common primary brain tumor and mainly characterized by

highly infiltrative nature, high malignancy and poor clinical outcome.^[1-3] It originates from glial cells like astrocytes,

oligodendrocytes and ependymal cells and their nomenclature is based on glial cell type responsible for tumour i.e. astrocytoma, oligodendroglioma and ependymoma. Subependymoma arises from less abundant subependymal astrocytes.^[4] Oligoastrocytomas consist of both astrocytic and oligodendrocytic components. According to WHO classification these glial tumors are further subdivided into Grade 1 to IV based on the features of neoplasia. The prognosis of glial tumor remains poor despite advances in surgical techniques, radiotherapy and chemotherapy.^[1-3] This paper aims to analyze outcome of 18 patients of supratentorial glioma operated in neurosurgery OT during last three year and review the literature to find the impact of recent advances in the field of neuroimaging, operative techniques, chemoradiation and other modalities of therapeutic interventions on the clinical outcome of such tumors.

METHOD

18 patients of supratentorial glioma were operated between May 2009 and April 2012. All the patients were evaluated either with CT scan or MRI of the brain or both and had radiological features suggestive of supratentorial glioma. Contrast studies and MR spectroscopy were additionally performed in some cases. Pre and post operative clinical evaluation and neuropsychological assessment was done in all patients. Pre-operative frozen section biopsy was obtained in all cases at the time of surgical decompression of the tumor. Patients who received chemotherapy and radiotherapy were also evaluated with PET scan. All patients were observed in a follow up for a period of 3 years for any clinical deterioration or recurrence of the tumor.

RESULT

The seizures and headache were commonest presentation of supratentorial gliomas. Craniotomy and tumor decompression was the done for all the patients. For preoperative and post operative evaluation of the patients, MRI brain with contrast enhancement was the commonest modality of investigation. Per-operative frozen section biopsy guided the extent of the tumor resection. Majority of the patients exhibited significant neurological improvement following surgery. MRI brain scan and PET scan were done to evaluate the patient for tumor recurrence in follow up. Various factors affect the clinical outcome such as pre-operative clinical status of the patient, location of the tumor i.e. deep or superficial, relation to eloquent areas, relation to vessels and availability of advanced imaging, extent of tumor decompression, intraoperative technologies like intra-operative MRI and adjuvant therapy.

DISCUSSION

Advancement has occurred in the fields of neuro-radiology and neuro-oncology leading to early diagnosis, better surgical management, effective chemoradiation and newer therapeutic interventions for supratentorial gliomas. Therefore we are emphasizing on advancements in neuroimaging, intraoperative techniques, chemoradiation therapies and new therapeutic interventions in management of supratentorial Gliomas in following discussion.

1. Neuroimaging Advances: Advances in pre operative neuroimaging normally includes CT scan, MRI scan, MR spectroscopy, functional MRI, MR tractography, PET scan, and SPECT. Neuronavigation, intraoperative Ultrasonography (iUS), Intraoperative CT scan and intraoperative MRI further may help in intraoperative imaging, localization

and extent of tumor removal of glial tumors. PET scan is an advanced tool for evaluation response to the therapy and any tumor recurrence, apart from CT scan, MRI scan with contrast, and MR spectroscopy. Neuroradiological advancements have led for the better preoperative assessment of supratentorial gliomas. CT scan or MRI of the brain may identify location of tumor and indicate the pathology of the lesion. The low grade supratentorial glioma is usually hypointense on T1 weighted image and hyperintense on T2 weighted image (Fig. 1 and 2). However, the underlying metabolic or functional integrity of brain cannot be adequately evaluated on anatomical MRI alone. Several physiology based methods have been developed to improve tumour characterization including MR spectroscopy (MRS), dynamic susceptibility contrast MRI, functional MRI, diffusion imaging and perfusion MRI^[4,5] and radionuclide imaging (PET and SPECT). Positron emission tomography (PET) with ¹¹C-methionine, Fluorodeoxyglucose, and ¹¹C-Choline may also help understanding of the pathophysiology of glial tumors.^[5]

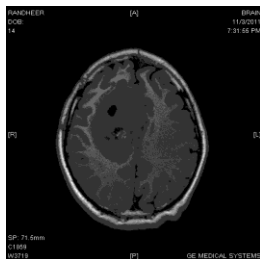


Fig-1. MRI brain T1W1 image axial view showing right frontal low grade glioma.

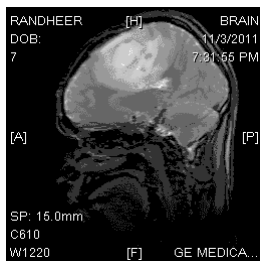


Fig-2. MRI brain T2W2 image sagittal view showing frontal region low grade glioma.

MR spectroscopy of brain helps in diagnosis of intracranial neoplastic lesions. Glial tumours have a reduced NAA/Cr ratio and spectroscopic profiles such as high lactate and lipids are indicative of malignant tumour. Tumour cell density may be reflected by the magnitude of choline peak and choline: NAA ratio on MR spectroscopy.^[5] Diffusion tensor imaging (MR tractography) depicts the anatomical relationship of a tumor to local white matter pathways, and may show any displacement, invasion or destruction of surrounding white matter tracts by tumor. The knowledge of location of white matter tracts may assist intraoperative fibre stimulation and guide extent of resection and the evidence of intact pathways following surgery may predict motor deficits and recovery.^[4]

2. Intraoperative technological advancements: The goals of surgery for malignant glioma is to establish a histological diagnosis, tumor cytoreduction for improvement in neurological status by reduction of increased intracranial pressure, and for possible change in tumor kinetics leading to better response to chemoradiation.^[6,7] Cavitron ultra sonic aspirator (CUSA), neuroendoscopy, neuronavigation, intraoperative ultrasound (iUS) are important tools to maximize the extent of tumor decompression and reduce the post operative morbidity.^[8-11] The use of fluorescent tumor marker technique for intraoperative detection involves oral administration of the nonfluorescent prodrug, 5-aminolevulinic acid (ALA). In tumour tissue, 5-ALA is metabolized to fluorescent protoporphyrin IX (PpIX) through the heme biosynthesis pathway. PpIX is accumulated in WHO grade III and IV malignant gliomas. The use of a specially adapted operating microscope omitting blue light with wavelength of 400 nm allows the surgeon to visualize brain tissue as “blue”

and the tumour as “red” in colour. It enhances the macroscopic total resection of malignant gliomas.^[9,12]

Intraoperative MRI allows surgeons to take MR scans during surgery, while the patient is still in the operating room. Surgery can be temporarily stopped, MRI is performed and MR scans are analysed to determine if the tumour has been removed completely, or if the surgery should continue. The biggest advantage of the use of the iMRI is that it can help the surgeon to identify the normal tissue in eloquent areas.^[13] Diffusion tensor imaging (DTI) provides information about eloquent white matter structures. Long tracts, especially the corticospinal tract, can be visualized by means of a technique called DTI fiber tracking. Fiber tracking can be integrated into neurosurgical planning software and be used for navigated surgery.^[13] With the help of the fMRI, active parts of the brain are visualized. Intraoperative Examination Monitor for Awake Surgery (IEMAS) is an information sharing device, which provides ones an opportunity for simultaneous real-time visualization of the wide spectrum of co-registered intraoperative data.^[13-15]

Contemporary technological developments have revolutionized surgical management of intracranial gliomas. Combined application of these techniques provides an opportunity for aggressive removal of the intraaxial brain lesions with minimal risk of neurological complications. Surgery performed under such conditions can be designated as “information-guided procedure”.^[13-15] Robotic neurosurgery, i.e., incorporation of the robotic systems into neurosurgical practice may provide extremely high preciseness (up to 10 µm), and may potentially reduce the risk of neurological deficit if surgery is performed in highly vulnerable brain areas. Other potential advantages of the robotics include opportunity to perform manipulations in

extremely limited working space, as well as possibility of initial computer-aided modeling and simulation of the planned surgical actions.^[13]

3. Advances in chemoradiation therapy and newer therapeutic interventions:

Chemotherapy with Temozolamide is used routinely as adjuvant chemotherapy for high grades. It improves survival and time to progression, without any increase in adverse events. Response to this drug can be predicted by analyzing tumor tissue for O-6-methylguanine-DNA methyltransferase (MGMT) expression, as this enzyme diminishes the therapeutic efficacy of temozolamide.^[4] Tumor vaccine therapy or immunotherapy is a new therapeutic intervention to target residual tumor cells after neurosurgical procedure. One option involves creation of a subcutaneous vaccine specific to the patient’s resected tumor using tumor lysate-pulsed dendritic cells. Vaccinated patients demonstrate an antigen-specific T-cell response and survival benefit as well as increased responsiveness to chemotherapy. Other potential strategies include interleukin gene introduction via viral vectors, vaccination with dendritic-glioma cell fusion using interleukin12, or scores of other targets to immunotherapy.^[16,17] Genetic modification of tumor cells can increase their immunogenicity and potentially enhance the systemic immune response generated against an intracranial tumor. Numerous cytokines such as IFN, GM-CSF, or IL-12 have been tested. Vaccination with cytokine-producing tumor cells has been shown to stimulate a potent immunity against tumors within the brain and provides a basis for gene-based immunotherapy. Vaccination with allogeneic pre-B cells transduced with a glioma-related mutant antigen, epidermal growth factor receptor variant III (EGFRvIII) has been shown to produce a systemic immune response against

autologous intracranial tumor expressing the same antigen.^[18]

Promising alternative approach to antibodies is now represented by RNA and DNA oligonucleotides, including antisense (AS-ODN), microRNAs (miRNAs), small interfering RNAs (siRNAs), and nucleic acid aptamers. Among them, only AS-ODNs are already in clinical development.^[9] The most advanced is a phosphorothioate-modified AS-ODN (Trabedersen, AP 12009, Antisense pharma) directed against the transforming growth factor- β 2 (TGF- β 2), a protein that is massively produced by high-grade gliomas and promotes tumor cell proliferation, angiogenesis, invasion and metastasis. Thus, inhibiting TGF- β 2 production, Trabedersen exerts multiple antitumor effects. To bypass the BBB, this AS-ODN has been administered intratumorally using a single intratumoral catheter linked to a portable pump.

Molecularly targeted therapy in gliomas is a newer modality in the management of gliomas. In the past decade there has been substantial growth in the number of novel therapies due to increased understanding of the molecular pathways involved in glioma formation and progression. Malignant transformation in glioma is often the result of the sequential accumulation of genetic aberrations and proliferation of growth factor signaling pathways that include the vascular endothelial growth factor (VEGF), epidermal growth factor (EGF), and platelet derived growth factor (PDGF). Delineation of the molecular pathways of glial tumorigenesis has fostered development and testing of small molecule inhibitors and monoclonal antibodies targeting their components.^[17]

In malignant gliomas, angiogenesis is typically associated with an increase in vascular endothelial growth factor (VEGF), a protein that stimulates new blood vessel

formation. Activation of the VEGF receptor starts many processes that promote endothelial cell growth, migration, and survival from preexisting blood vessels.^[19] Perhaps the most exciting development in the treatment of recurrent (and possibly newly diagnosed) malignant gliomas has been the use of antiangiogenic therapies such as bevacizumab. *Bevacizumab* is a humanised monoclonal antibody against vascular endothelial growth factor (VEGF), necessary for tumour angiogenesis).^[1,20]

Local chemotherapy can target micrometastases by taking advantage of the expression of tumor-specific proteins and rapid tumor cell turnover while minimizing toxicity to the postmitotic normal brain. Local chemotherapy is also desirable because GBM rarely has systemic metastases, eliminating the necessity of systemic delivery with its associated toxicity.^[8,21] Gliadel (MGI Pharma, Bloomington, MN) represents an early attempt at local therapy. It is a system for the delivery of carmustine via biodegradable polymer wafer and is FDA approved for the treatment of newly diagnosed and recurrent malignant gliomas.^[22] Intra-arterial chemotherapy is an intervention in which a drug is directly delivered to the tumoral arterial supply under angiographic guidance. This approach avoids metabolism of the drug before it reaches its target, allowing for a tenfold increase in tissue drug concentration as compared with intravenous administration.^[8,23]

Intra-arterial mannitol is administered to enhance tumor penetration prior to chemotherapy to cause a transient interruption in the tight junctions that compose the BBB. In addition, drugs such as carboplatin are being utilized, which have a more favorable side-effect profile than nitrosureas when used for arterial infusion. Although not yet used in neurosurgical practice, it is expected that within the next

10 years, nanotechnology will further advance the surgical management of malignant gliomas. The multifunctional clinical nature of nanotechnology will provide for the targeting, imaging, and therapy of infiltrating brain tumour cells that escape the surgical treatment. Therapeutic nanoparticles coated with various drugs and conjugated to brain tumour-specific antibodies will be delivered systemically or locally to brain tumours. The ability to image nanoparticles by conventional methods, such as MRI, will provide precise information regarding therapeutic agent delivery and therapeutic follow-up. The local hyperthermia treatment of malignant gliomas might also be possible with nanoparticles using alternating magnetic fields that are safe for noncancerous cells.^[9, 24]

CONCLUSION

Preoperative neuroradiological investigations such as MR spectroscopy, PET imaging, functional MRI and diffusion tensor imaging help in the early diagnosis and precise surgical planning in case of supratentorial glioma. Information-guided surgical management of intracranial gliomas based on the intraoperative integration of the various anatomical, neurophysiological, and histopathological data permit to perform aggressive tumor resection with minimal risk of permanent postoperative neurological morbidity and may result in meaningful prolongation of the patients' survival. Further development of the intraoperative technologies will permit to increase the rate of glioma resection. Various techniques like intra arterial drug administration, wafers/ implantable polymers, high dose chemotherapy intrathecal therapy and convection enhanced delivery may improve the drug delivery of chemotherapeutic agents. The newer therapeutic interventions- immunotherapy, molecular

based therapy, etc. may improve the clinical outcome of the patients following neurosurgical intervention. So, an integration of various technological advancements should be preferred to achieve the higher quality of life for a patient of glioma. Interdisciplinary effort of integration of the technological developments like intraoperative ultrasound, neuronavigation, intraoperative MRI, chemoradiation and newer therapeutic modalities- antiangiogenic therapy, immunotherapy may revolutionize surgical management of supratentorial gliomas. The outcome of glioma management may improve further with a better understanding of tumor biology, molecular aspects of cancer, robotic neurosurgery and nanotechnology.

REFERENCES

1. S. Catuogno, C. L. Esposito, C. Quintavalle, G. Condorelli, V. de Franciscis, and L. Cerchia (2012). Nucleic Acids in Human Glioma Treatment: Innovative Approaches and Recent Results. *Journal of Signal Transduction*. Volume, 2012, Article ID 735135, pp 1-11
2. H. Ohgaki, P. Dessen, B. Jourde et al (2004). "Genetic pathways to glioblastoma: a population-based study," *Cancer Research*, vol.64, no. 19, pp. 6892-6899.
3. D. N. Louis, H. Ohgaki, O. D. Wiestler et al. (2007), "The WHO classification of tumours of the central nervous system," *Acta Neuropathologica*, vol. 114, no. 2, pp. 97-109, 2007.
4. Melissa C Werndle, Timothy L Jones and Marios C Papadopoulos (2011). *Neurosurgical Management of Gliomas*. In *Diagnostic Techniques and Surgical Management of Brain Tumors*, by Ana Lucia Abujamra (Ed.), ISBN: 978-953-307-589-1
5. Claude-Edouard Chatillon and Kevin Petrecca (2012). *Emerging imaging and*

- operative techniques for glioma surgery. In *Advances in Cancer Management*, by Ravinder Mohan (Ed.), Publisher: InTech
6. Sapiro WR(1982). Treatment of neuroectodermal brain tumors. *Ann Nerol*. 12, 231-7
 7. C. Abrudan, Adriana Cocis, Dana Cernea, B. Suci, Marilena Cheptea, I. Florian(2011), Surgery of high grade gliomas - pros in favor of maximal cytoreductive surgery . *Romanian Neurosurgery*, XVIII 1: 38 – 53.
 8. Samuel A. Goldlust, Garth M. Turner, Jordana F. Goren, Michael L. Gruber(2008). Glioblastoma Multiforme: Multidisciplinary Care and Advances in Therapy. *Hospital Physician*. pp. 9 –22
 9. Vranic A(2011). New developments in surgery of malignant gliomas. *Radiol Oncol*; 45(3): pp.159-165.
 10. Cappabianca P, Cinalli G, Gangemi M, Brunori A, Cavallo LM, de Divitiis E, et al(2008). Application of neuroendoscopy to intraventricular lesions. *Neurosurgery*; 62(Suppl 2), pp. 575-97.
 11. Enchev Y, Bozinov O, Miller D, Tirakotai W, Heinze S, Benes L, et al.(2006). Image guided ultrasonography for recurrent cystic gliomas. *Acta Neurochir (Wien)*; 148, pp1053-63.
 12. Stummer W, Pichlmeier U, Meinel T, Wiestler OD, Zanella F, Reulen HJ.(2006). Fluorescence-guided surgery with 5-aminolevulinic acid for resection of malignant glioma: a randomised controlled multicentre phase III trial. *Lancet Oncol*, 7: pp392-401.
 13. Yoshihiro Muragaki, Hiroshi Iseki, Takashi Maruyama, Mikhail Chernov, Takashi Suzuki, Kitaro Yoshimitsu, et al (2011). Advanced Surgical Management of Gliomas: Technological Requirements, Concept of Information-Guided Resection and Clinical Results, Diagnostic Techniques and Surgical Management of Brain Tumors. *Ana Lucia Abujamra (Ed.) Publisher: InTech*,
 14. Iseki H., & Nambu K.(2005). Intraoperative examination monitoring for awake surgery IEMAS. *No Shinkei Geka*, vol 33, No 10, pp 1028-1031.
 15. Iseki, H.; Nakamura, R.; Muragaki, Y.; Suzuki, T.; Chernov, M.; Hori, T. & Takakura K. (2008). Advanced computer-aided intraoperative technologies for information-guided surgical management of gliomas: Tokyo Women's Medical University experience. *Minimally Invasive Neurosurgery*, Vol. 51, No. 5, pp. 285-291.
 16. Yang Liu, MD, Ka-yun Ng, MD, and Kevin O. Lillehei(2003), Cell-Mediated Immunotherapy: A New Approach to the Treatment of Malignant Glioma, *Cancer Control* Vol. 10, No.2 138-147
 17. Manmeet S. Ahluwalia, *Chemotherapy for brain tumors, Schmidek and Sweet Operative Neurosurgery techniques*, 6th edition, volume 1, Alfredo Quinones – Hinojosa (Ed) , (Elsevier Saunders) page 94-104.
 18. Sampson JH, Crotty LE, Lee S, et al.(2000). Unarmed, tumor-specific monoclonal antibody effectively treats brain tumors. *Proc Natl Acad Sci U S A*. 97:7503-7508.
 19. Khasraw M., Lassman A. B(2010). Advances in the Treatment of Malignant Gliomas. *Curr Oncol Rep* 12:26–33.
 20. P. Hau, P. Jachimczak, and U. Bogdahn(2009), “Treatment of malignant gliomas with TGF- β 2 antisense oligonucleotides,” *Expert Review of Anticancer Therapy*, vol. 9, no. 11, pp. 1663–1674,.
 21. Newton HB(2005). Intra-arterial chemotherapy of primary brain tumors. *Curr. Treat Options Oncol*; 6:519–30.
 22. Guha A, Mukherjee J(2004). Advances in the biology of astrocytomas. *Curr. Opin Neurol* 17:655–62.
 23. Westphal M, Ram Z, Riddle V, et al.(2006). Gliadel wafer in initial surgery for malignant glioma: long-term

follow-up of a multicenter controlled trial. Acta Neurochir;148:269–75.
24. Van Meir EG, Hadjipanayis CG, Norden AD, Shu H, Wen PY, Olson JJ(2010).

Exciting new advances in neuro-oncology: The avenue to a cure for malignant glioma. CA Cancer J Clin; 60: 166-93.

How to cite this article: Gautam VKS, Singh R. Supratentorial gliomas: a review of neurosurgical management, technological advancements and new therapeutic interventions. Int J Health Sci Res. 2014;4(2):170-177.

International Journal of Health Sciences & Research (IJHSR)

Publish your work in this journal

The International Journal of Health Sciences & Research is a multidisciplinary indexed open access double-blind peer-reviewed international journal that publishes original research articles from all areas of health sciences and allied branches. This monthly journal is characterised by rapid publication of reviews, original research and case reports across all the fields of health sciences. The details of journal are available on its official website (www.ijhsr.org).

Submit your manuscript by email: editor.ijhsr@gmail.com OR editor.ijhsr@yahoo.com