



Case Report

Molar Distalization by Using a Skeletal Anchorage System: A Case Report

Sunilkumar M^{1*}, Silju Mathew^{1**}, Mahantesh. R. Chinagundi^{1***}, Hrushikesh Aphale^{1#}, Aravind S Raju^{2***}

*Reader, **Professor & Head, ***Senior Lecturer, #P.G. Student

¹Department of Orthodontics & Dentofacial Orthopaedics, M.S.Ramaiah Dental College & Hospital, Bangalore

²Department of Orthodontics & Dentofacial Orthopedics, St.Gregorios Dental College, Chelad, Kerala.

@Correspondence Email: drlinus22@yahoo.com

Received: 19/04/2013

Revised: 17/05/2013

Accepted: 27/05/2013

ABSTRACT

Aim & objective : To obtain an effective and compliance-free molar distalization without an anchorage loss.

Methodology: A conventional pendulum appliance was modified to obtain anchorage from a palatal implant instead of the premolars. The screw was placed in the anterior paramedian region of the median palatal suture.

Results: Skeletal and dental changes were measured on cephalograms, and dental casts were obtained before and after distalization.

Conclusion: Molar as well as premolar distalization was achieved with BAPA without any anchorage loss. Besides the space gained in the posterior segment, enough space was also gained in anterior segment, and spontaneous alignment of anteriors was achieved during molar distalization. Thus BAPA presented an effective and minimally invasive, compliance-free alternative for intraoral molar distalization in nonextraction Class II.

Keywords: Molar distalization; Pendulum appliance; Mini implant; Skeletal anchorage

INTRODUCTION:

Maxillary molar distalization is needed for nonextraction treatment of dental Class II malocclusions. The traditional approach to distalize maxillary molars is with extraoral appliances. ^[1] Although this method offers the advantage of stability with fewer side effects, the need for compliance and the esthetic drawbacks led clinicians to search for noncompliance alternatives. ^[2, 3] Numerous alternative intraoral non-compliant appliances ^[6] such as repelling magnets, ^[4] the distal jet, ^[5] and the pendulum ^[7] have been developed, and many well-

documented studies have substantiated their effects. The pendulum appliance has been a commonly used. Forward movement of anchoring teeth with all intraoral distalization appliances has been the most important disadvantage of the pendulum appliance.

Brender et al, and Kircelli et ^[7] al had successful results using intraosseous screws for maxillary molar distalization. Screws can be used as a direct anchorage unit that is connected to the teeth to be moved, or the anchorage teeth can be stabilized with the screw that acts as an indirect anchorage unit.

Kircelli et al used a modified pendulum appliance (bone-anchored pendulum appliance, BAPA) supported by 2 intraosseous screws instead of occlusal rests on the premolars.

Patient Selection and Diagnostic Considerations

Favourable cases for molar distalization include Class I skeletal pattern cases, non extraction treatment of class II malocclusion, patients with mild arch length

discrepancy, in cases where upper permanent first molars have moved mesially due to early loss of deciduous molars, in patients where second molar extractions are planned or has not yet erupted, low angle cases. Unfavourable cases for molar distalization include class II and class III skeletal pattern, skeletal and dental open bite, severe arch length discrepancy cases, high angle cases.

CASE REPORT

A 17 year old female patient presented with a chief complaint of proclined upper anteriors. Review of the patient's medical, dental, and family histories revealed no significant findings. Extra oral examination revealed a convex profile, deep mentolabial sulcus and horizontal facial pattern (Fig.1).



Fig.1: Pre-treatment extra – oral features

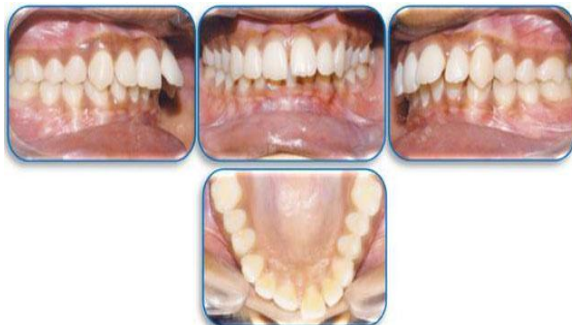

Fig.2: Pre-treatment Intra – Oral features.

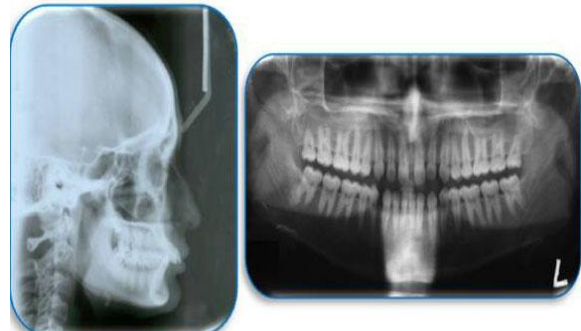


Fig.3: Pretreatment Lateral cephalogram and OPG

Looking at the intraoral picture, patient had class II molar relation and an overjet of 5mm (Fig.2).

Pretreatment panoramic radiograph and lateral cephalogram confirmed the clinical findings and revealed distoangular impacted upper third molars (Fig.3).

Treatment Objective

Correction of overjet, overbite, proclination, spacing, rotation and midline shift, molar relation

Treatment Plan

Treatment plan followed was non extraction treatment using a fixed functional appliance. It included alignment, intrusion

and retraction of upper and lower anteriors followed by distalization of upper molars with implant supported pendulum appliance.

Treatment Mechanics

Fabrication and Placement of Bapa

A titanium palatal implant (2.0 mm diameter 8 mm length) was used as a rigid bone anchor. It was inserted in the anterior paramedian region of the median palatal suture 7-8 mm posterior to the incisive foramen and 3-4 mm lateral to the median line.

After soft tissue healing, impressions and stone casts were obtained with the IMF screws in place. On the stone model, the screw head was blocked out with wax, and the pendulum appliance was constructed according to Hilgers descriptions, excluding the auxiliary wires that extend to the occlusal surface of the first and second premolars. The appliance adaptation was checked clinically, and the springs were activated parallel to the median palatal

suture. The acrylic plate was connected to the screw head using cold-cure, methyl methacrylate free acrylic resin (Fig 4).

Finally, activated 0.032-inch titanium molybdenum alloy (TMA) springs were inserted into the lingual sheaths on the first molar bands. Patients were specially educated to maintain their oral hygiene and were asked to use a mouthwash regularly. At every appointment, the soft tissue around the acrylic plate was checked. Also, the springs were reactivated if necessary.

Treatment commenced with MBT versatile appliance in 0.022 inch slot. Pendulum appliance (implant supported) was fabricated and placed in the oral cavity for molar distalization as described above. Pendulum appliance was activated and molar distalization was done. A Class I molar relationship was achieved in 6 months. The maxillary first molars distalize at an average of 4 mm tipping distally, the maxillary second premolar and first premolar retracted distally (Fig.5).

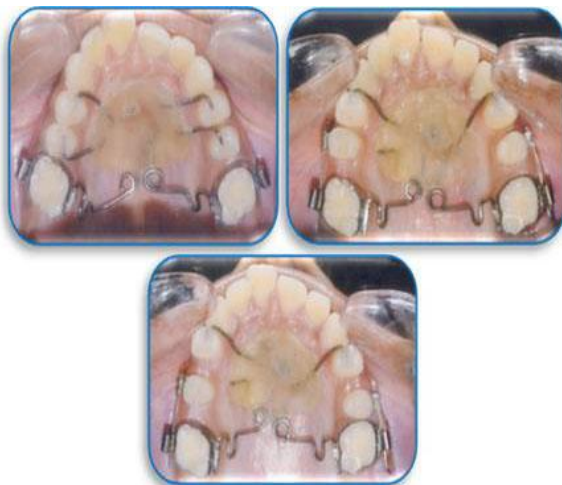

Fig.5 : showing bone anchored molar distalization appliance in place.

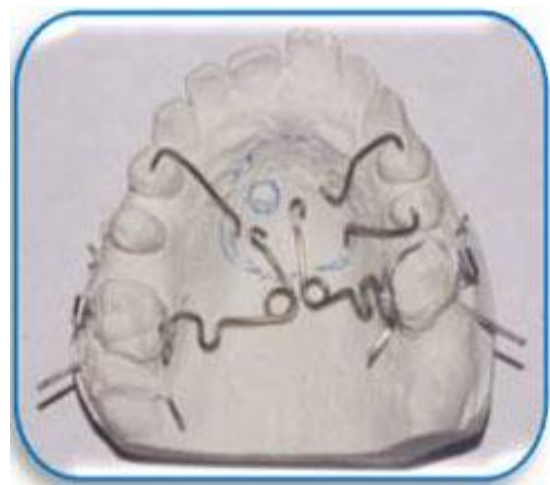


Fig 4 : Fabrication of pendulum appliance

No anterior movement of the incisors was detected and space gained was utilised for correction of over jet (Fig.6a, Fig.6b). After removing the acrylic plate, mild to moderate

soft tissue irritation was detected on the palatal mucosa, but this was resolved in a few days.



Fig.6a : Post treatment Extra Oral Features.

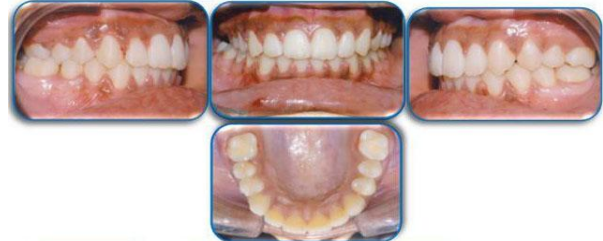

Fig.6a : Post treatment Intra Oral Features.

DISCUSSION

The pendulum appliance has experienced widespread clinical use, [8] and various studies have demonstrated its skeletal [9] and dentoalveolar effects. [10] Invariably, the pendulum was found to be an effective appliance for distalizing maxillary molars. However, associated anterior anchorage loss, which represented 30–43% of the space created between molars and premolars, was a constant finding of these studies. Today, rigid bone anchors including osseointegrated implants, [11] titanium miniscrews, [12] and miniplates are powerful candidates to solve the anchorage concern. Screws are attached to the bone by mechanical retention. Osseointegration is not a goal when screws are placed. At first sight, one can assume that severe mucosal irritation might occur with the BAPA; however, the screw head in the palatal acrylic acts as a stop so that the palatal mucosa cannot be compressed.

The maxillary molars moved distally by 4 mm and the second and first premolars were retracted distally. The cant of the palatal plane remained unchanged and the mandibular plane rotated by 3° in a clockwise direction. This clockwise rotation can be attributed to the maxillary molars moving distally into the wedge of occlusion and to the cusp interferences. No significant difference was observed regarding the upper and lower lip positions relative to the esthetic line.

CONCLUSION

Molar as well as premolar distalization was achieved with BAPA without any anchorage loss. Besides the space gained in the posterior segment, enough space was also gained in anterior segment, and spontaneous alignment of anteriors was achieved during molar distalization. Thus BAPA presented an effective and minimally invasive, compliance-free alternative for intraoral molar distalization in nonextraction Class II.

REFERENCES

1. Melsen B, Verna C. A rational approach to orthodontic anchorage. *Prog Orthod* 1999; 1:10-22.
2. Higuchi KW, Slack JM. The use of titanium fixtures for intraoral anchorage to facilitate orthodontic tooth movement. *Int J Oral Maxillofac Implants* 1991; 6:338-44.
3. Gelgor IE, Buyukyilmaz T, Karaman AI, Dolanmaz D, Kalayci A. Intraosseous screw-supported upper molar distalization. *Angle Orthod* 2004; 74:838-50.
4. Gianelly AA, Viatas AS, Thomas WM. The use of magnets to move molars distally. *Am J Orthod* 1989; 96:161-7.
5. Hilgers JJ. The pendulum appliance for Class II non-compliance therapy. *J Clin Orthod* 1992; 26:706-14.

6. Carano A, Testa M. The distal jet appliance for upper molar distalization. *J ClinOrthod* 1996; 30:374-80.
7. Kircelli BH, Zafer OP, Kircelli C. Maxillary molar distalization with a bone-anchored pendulum appliance. *Angle Orthod* 2005; 76:650-9.
8. Keim RG, Gottlieb EL, Nelson AH, Vogels DS. 2002 JCO study of orthodontic diagnosis and treatment procedures. Part 1. Results and trends. *J ClinOrthod*. 2002; 36:553–568.
9. Ghosh J, Nanda RS. Evaluation of an intraoral maxillary molar distalization technique. *Am J Orthod*. 1996; 110:639–646.
10. Byloff FK, Darendeliler MA. Distal molar movement using the pendulum appliance. Part 1: clinical and radiological evaluation. *Angle Orthod*. 1997; 67:249–260.
11. Keles, A, Erverdi N, Sezen S. Bodily distalization of molars with absolute anchorage. *Angle Orthod*. 2003; 73:471–482.
12. Deguchi T, Takano-Yamamoto T, Kanomi R, Hartsfield JK Jr, Roberts WE, Garetto LP. The use of small titanium screws for orthodontic anchorage. *J Dent Res*. 2003; 82(5): 377–381.

How to cite this article: Sunilkumar M, Mathew S, Chinagundi MR et. al. Molar distalization by using a skeletal anchorage system: a case report. *Int J Health Sci Res*. 2013;3(6):97-101.
