

Evaluation of Global and Regional Strain and Angiographic Correlation in Patients with Non-ST Elevation Acute Coronary Syndrome (NSTEMI-ACS)

Dr Sandipta Ray¹, Dr Subir Sen², Dr Seababrata Jana³

^{1,2,3}Department of Cardiology, AMRI Hospitals, Kolkata, India.

Corresponding Author: Dr Sandipta Ray

DOI: <https://doi.org/10.52403/ijhsr.20240610>

ABSTRACT

Non-ST elevated acute coronary syndrome (NSTEMI-ACS) is common and comprises of around one third of total patient of acute coronary syndrome (ACS). Evaluation and management is difficult due to complex pathophysiology involved.

Traditionally echocardiography helps to assess these patients non-invasively before they are taken to cardiac catheterization laboratory.

Speckle tracking echocardiography (STE) is an evolving modality by which more accurate assessment of left ventricular (LV) function can be done. STE also helps in identification of culprit artery responsible for the cardiac event.

In our study we tried to correlate angiographic finding with global and regional strain echocardiography of LV in patients with NSTEMI-ACS.

Total 50 patients were included in this cross-sectional study and we found that poor global longitudinal strain (GLS) of LV was associated with critical, multivessel coronary artery disease (MVCAD) with or without involvement of Left main coronary artery (LMCA)

Keywords: NSTEMI-ACS, LV, Regional strain, global strain, STE

INTRODUCTION

Speckle Tracking Echocardiography (STE) is a new non-invasive imaging technique that permits assessment of global and regional myocardial function independently from both cardiac translational movements and beam angle. It is based on analysis of spatial displacement of spots during cardiac cycle and can capture myocardial deformation in 3 dimensions: radial, circumferential, and longitudinal. It also offers a superseded way to evaluate strain and strain rate and can conquer many traditional problems related to angle-dependent methods.(1)

Other than STE only cardiac MRI (CMR) can analyse myocardial deformity. CMR

can also measure both Right ventricle (RV) and left ventricular ejection fraction (LVEF) more accurately compared to echocardiography. Cardiac MRI also assess viability of infarcted myocardium and also able to identify myocardial edema. In Non ST Elevated Acute Coronary Syndrome (NSTEMI-ACS) culprit artery recognition can be done by using T2 sequence of CMR and identification of infarcted area.

Use of STE in acute coronary syndrome (ACS) is well studied. In some studies correlation was found in between serum troponin level and global longitudinal strain (GLS) of left ventricle (LV). Patients with NSTEMI-ACS has complex pathology,

generally have multivessel coronary artery disease. (2)

It is difficult to identify infarct related artery (IRA) in these subsets of patients by conventional echocardiography. Regional strain echo by STE is an attractive alternative to identify ischaemic myocardium after ACS and also helps in localization of IRA.(3)

In our study we have tried to correlate global and regional strain echocardiographic parameters of LV with coronary angiography finding in patients with NSTEMI-ACS.

MATERIALS & METHODS

PLACE OF STUDY: Department of cardiology, IPGME&R- SSKM Hospital, Kolkata

STUDY POPULATION:

This cross-sectional study was conducted on 50 patients aged between 30years to 70 years with clinical diagnosis of NSTEMI-ACS who had attend the Cardiology OPD and Emergency, IPGME&R Kolkata, was included in this study. Written informed consent was taken from each patient or their relative in their own language. Patient with ST elevated myocardial infarction (STEMI), unstable angina (UA), hemodynamically significant valvular heart disease, atrial and ventricular arrhythmias were excluded from the study.

METHOD

Every patient included in the study undergone conventional and strain echocardiography after hospital admission. STE was performed for all the subjects to assess LV global and regional strain. STE was performed using vivid scanner (E9) and gave 17-segment LV images from two-chamber, apical long axis, and four-chamber recordings with frame rate of 50 - 60 for quantitative analysis. The strain values for the entire segments were recorded and then averaged to gain the Global Longitudinal Strain (GLS). After that, regional and global longitudinal strains were calculated based on segmental myocardial strain and colours of bull's eye mapping values. It was mentioned that choosing the cardiac cycle was left to the operator's decision (according to the best quality). Normal LV strain value was taken as -18 to -19 as per criteria laid down by American Society of Echocardiography (ASE).

Coronary angiography (CAG) was performed for every patient enrolled in this study. The data were expressed as a percentage of stenosis of Left Circumflex artery (LCX), Left Anterior Descending (LAD), Right Coronary Arteries (RCA), and their main branches. Obstruction more than 70% was considered to be significant stenosis. RCA and LCX constituted the poster inferior territory, while LAD and its branches were responsible for perfusion of the antero-septal territory.

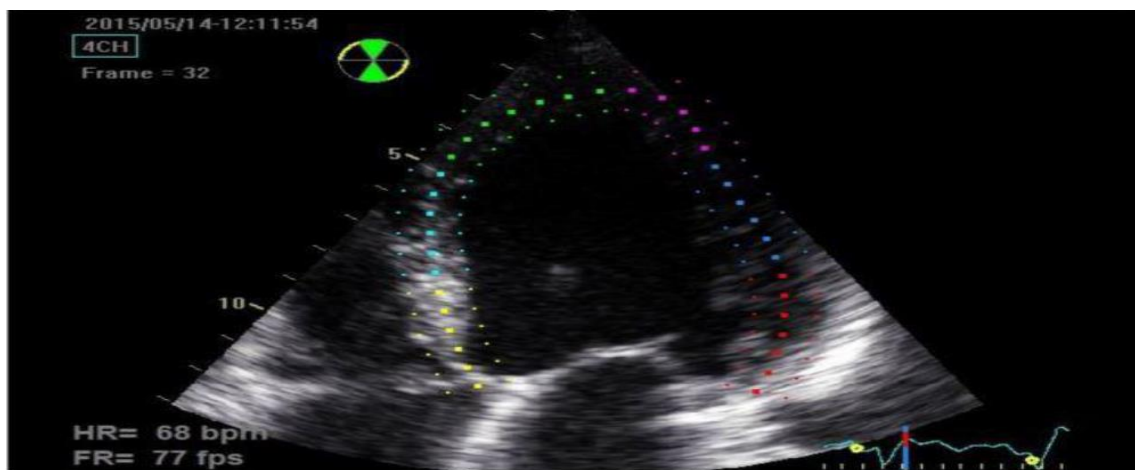


Figure 1- Apical four chamber (A4C) view demonstrating endocardial border of LV by STE (Semi automated tracing)

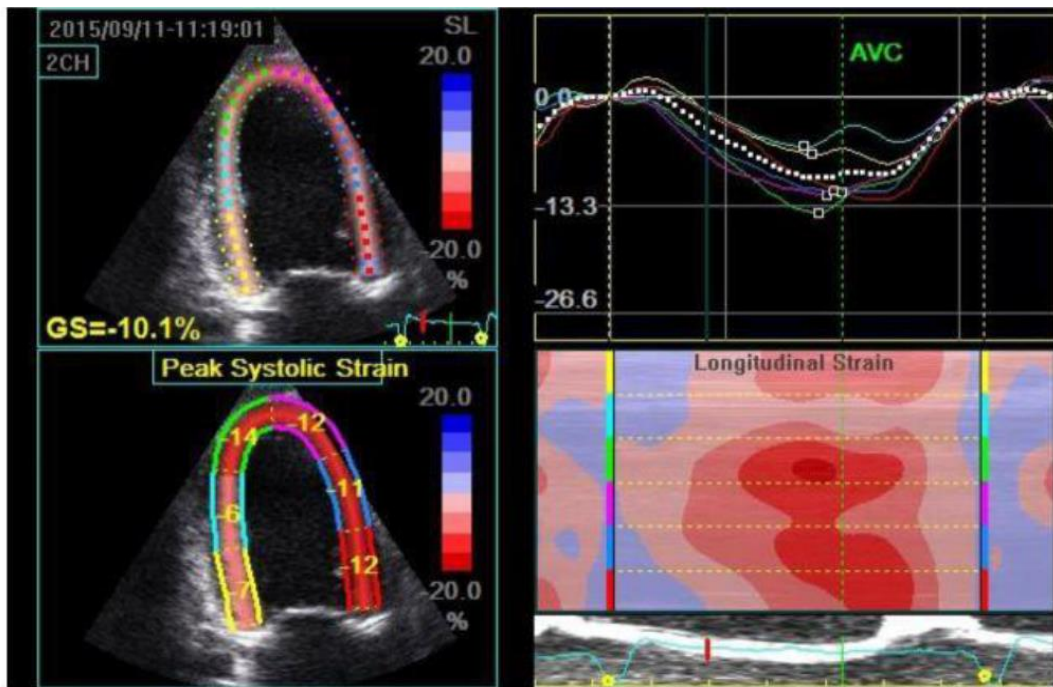


Figure 2- Quad display of apical two chamber view (A2C) showing different ways to depict global longitudinal strain (GLS) of LV.

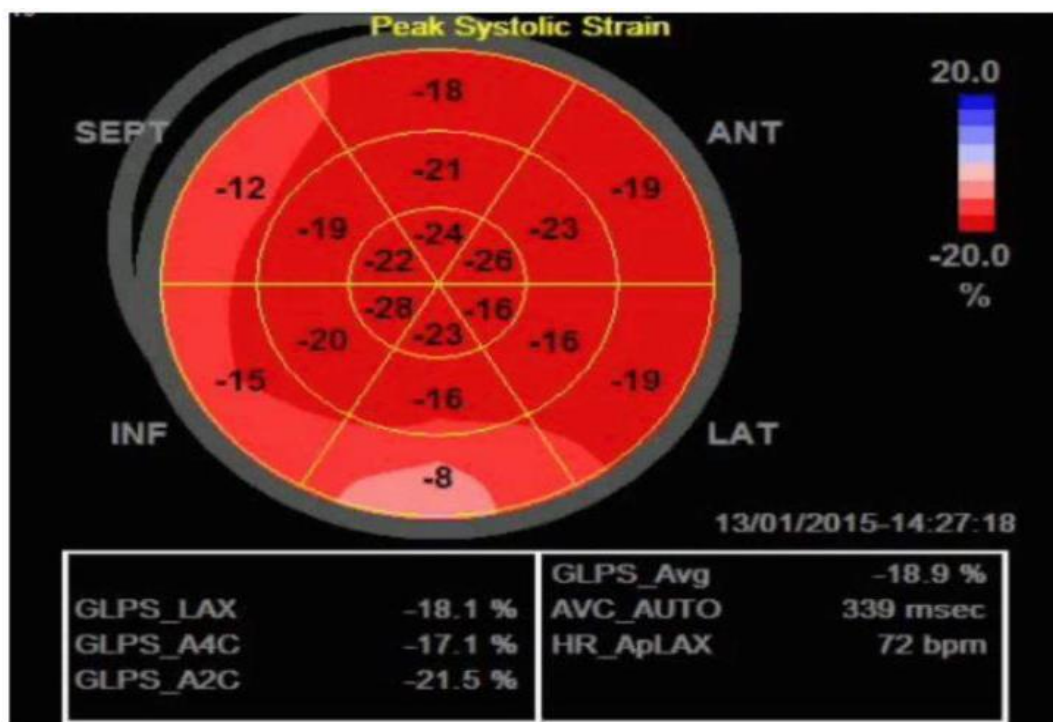


Figure 3 – Bull's Eye map of the left ventricular strain showing impaired basal inferior wall longitudinal strain (light red) in a patient with NSTE-ACS.

RESULT

For statistical analysis data were entered into a Microsoft excel spreadsheet and then analyzed by SPSS (version 27.0; SPSS Inc., Chicago, IL, USA) and GraphPad Prism version 5. Data had been summarized as mean and standard deviation for numerical

variables and count and percentages for categorical variables. One-way analysis of variance (one-way ANOVA) technique used to compare means of three or more samples for numerical data (using the F distribution). P value of less than 0.05 was taken as statistically significant.

Mean age of the study population was around 58 years. 62% of the study population was male.

Type 2 diabetes mellitus, systemic hypertension, and dyslipidaemia and active smoking were most common associated comorbid condition.

CAG performed in all patients.

11(22%) patients had Normal LAD and 32(64%) patients had Significant LAD where 5(10%) patients had Intermediate disease. Among the patients with significant

LAD disease, 40% have complete occlusion of LAD.

Left main coronary artery (LMCA) involvement was seen in about one third of study population.

Left circumflex artery (LCX) significant disease was seen in 60% patients whereas Right coronary artery (RCA) was critically involved in around 50% cases.

In our study, 12(24%) patients had DVD, 13(26%) patients had SVD and 17(34%) patients had TVD. (Figure 4)

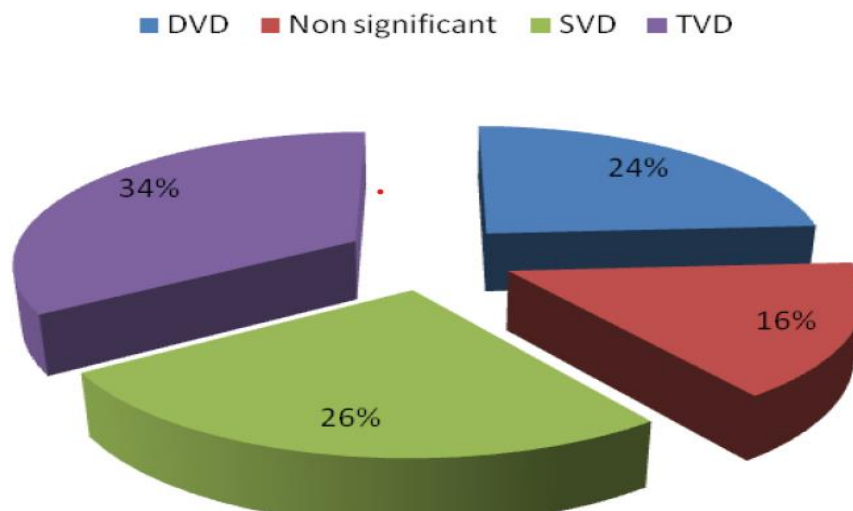


Figure 4- showing distribution of coronary involvement in the study population.

Our study showed that in patients with LAD involvement and anteroseptal ischaemia the mean GLS (mean ± s.d.) was -12.56 ± 6.4 as compared to normal value of -19 . (Table 1)

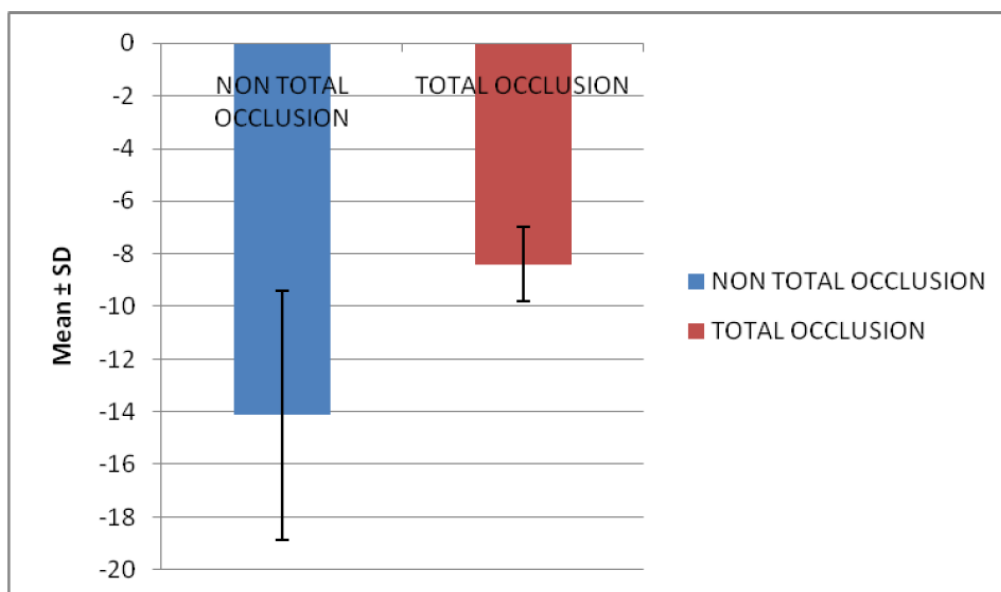


Table 1- Total occlusion in LAD leading to significant decrease in mean GLS of LV which is statistically significant.

In critical LCX involvement mean GLS was -11.8 with significant reduction of regional strain in the infero-lateral segments of LV. (Table 2)

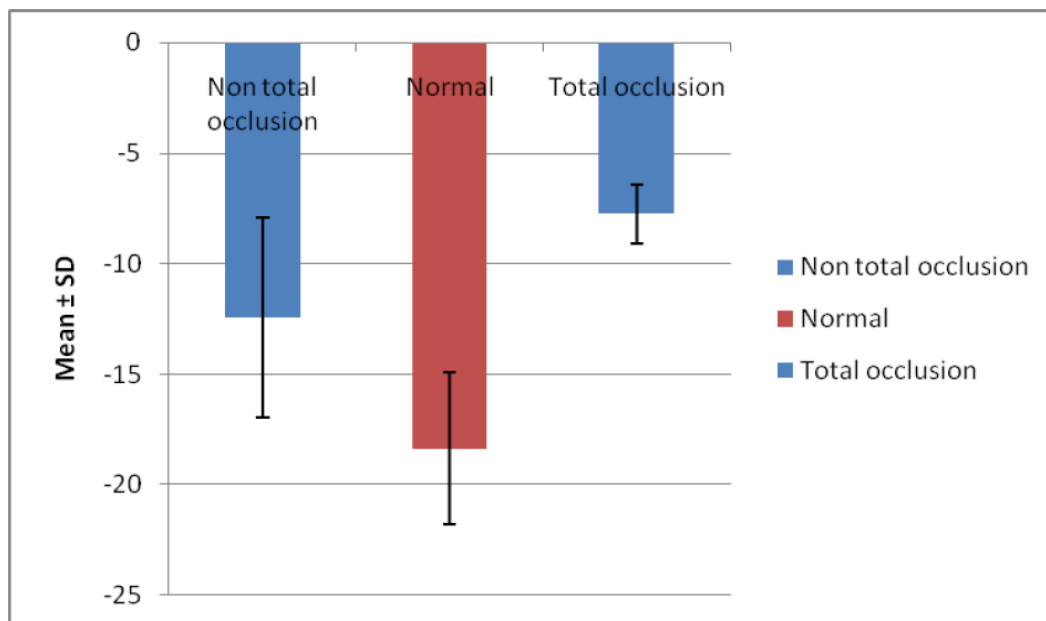


Table 2- showing significant reduction of GLS of LV in near total and total occlusion of LCX.

In predominant RCA involvement mean GLS of LV was around -12.6. Many patients with predominant RCA involvement had features of Right ventricular myocardial infarction (RVMI). Requirement of fluid and inotropic support was higher in these subsets. Multiple vessel involvement resulted in more decrement of global LV strain leading

to more overt LV dysfunction and increase cardiovascular morbidity. Patients with significant TVD underwent either complex coronary angioplasty or coronary artery bypass grafting (CABG) but had a prolong hospital stay, increased incidence of heart failure. In our study severely reduced GLS on many occasion predicts critical TVD.

		Numbe r	Mean	SD	Minimu m	Maximu m	Median	p-value
GLOBAL STRAIN	DVD	12	-10.6750	1.3811	-12.8000	-8.7000	10.4000	<0.0001
	Non significant	8	-21.5375	1.9205	-25.9000	-20.4000	20.6500	
	SVD	13	-15.5769	.9934	-16.9000	-13.4000	15.7000	
	TVD	17	-7.8941	1.1255	-9.6000	-5.7000	-7.6000	

Table 3 (DVD- Double vessel disease, SVD- single vessel disease, TVD- Triple Vessel Disease)

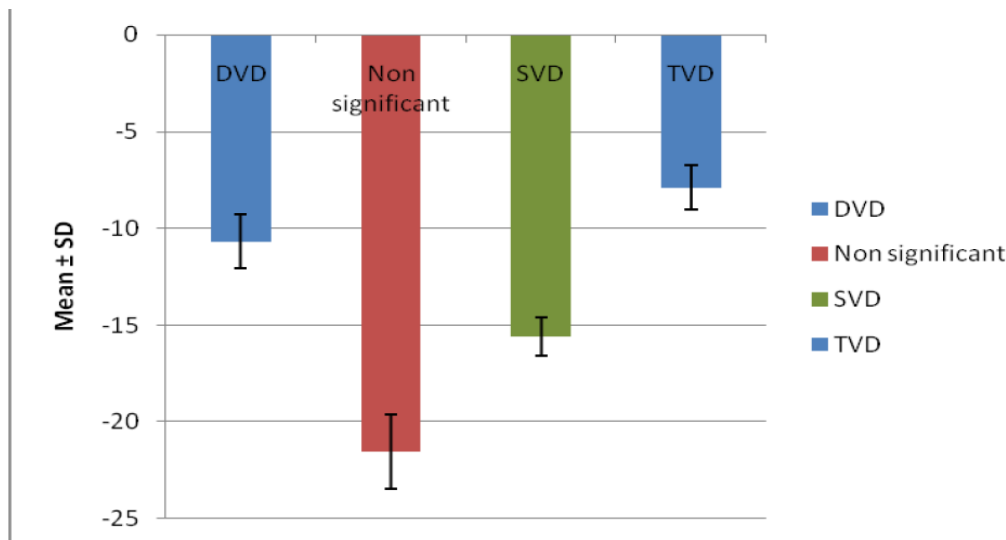


Table 4— significant reduction GLS of LV (Y axis) in patient with TVD as compared to SVD or DVD.

DISCUSSION

Patients with diagnosis of NSTE-ACS are a heterogeneous population with elevated risks of cardiovascular mortality, morbidity, and recurrence in long- and short-term follow-up.(4)

In these patients, choosing the treatment strategy depends on the presence and extent of coronary occlusion.

Identification of culprit artery during angiography remains the main challenge. Majority patient of NSTE-ACS have multivessel CAD. Generally, they are sick, having multiple comorbidities and prone to develop decompensated heart failure. (5)

Revascularization of these patients are also difficult often required heart team approach. STE can image these patients after acute coronary syndrome and helps to identify ischaemic myocardium and IRA. (6)

This study aimed at assessment of the capability of STE to determine whether angiographic correlation with echocardiographic finding is possible or not. Our study demonstrated that the poor GLS of LV is associated with hemodynamically significant critical coronary artery disease.

CONCLUSION

Small study population is the main limitation of this study. We only evaluated GLS of LV before coronary angiography. Assessment of GLS after revascularization would give us much more insights. Despite

wide use of STE across the globe it is still not a routine practice while evaluating patients with ACS. High Cost, non-availability of software, requirement of technical expertise are main limiting factors. Introduction of this novel non-invasive technique not only give us angiographic correlation but also helps to prognosticate about cardiovascular morbidity mortality.

Declaration by Authors

Ethical Approval: Approved

Acknowledgement: None

Source of Funding: None

Conflict of Interest: The authors declare no conflict of interest.

REFERENCES

1. Bauer M, Cheng S, Jain M, Ngoy S, Theodoropoulos C, Trujillo A, et al. Echocardiographic speckle-tracking based strain imaging for rapid cardiovascular phenotyping in mice. *Circ Res.* 2011;108(8):908-16.
2. Caspar T, Samet H, Ohana M, Germain P, El Ghannudi S, Talha S, Morel O, Ohlmann P. Longitudinal 2D strain can help diagnose coronary artery disease in patients with suspected non-ST-elevation acute coronary syndrome but apparent normal global and segmental systolic function. *International journal of cardiology.* 2017 Jun 1;236:91-4.
3. Dahlslett T, Karlsen S, Grenne B, Eek C, Sjøli B, Skulstad H, Smiseth OA, Edvardsen T, Brunvand H. Early Assessment of strain

- echocardiography can accurately exclude significant coronary artery stenosis in suspected non-ST-segment elevation acute coronary syndrome. Journal of the American Society of Echocardiography. 2014 May 1;27(5):512-9.
4. D'Andrea A, Cocchia R, Caso P, et al. Global longitudinal speckle-tracking strain is predictive of left ventricular remodeling after coronary angioplasty in patients with recent non-ST elevation myocardial infarction. *Int J Cardiol.* 2011;153(2):185–91.
 5. Munk K, Andersen NH, Terkelsen CJ, et al. Global left ventricular longitudinal systolic strain for early risk assessment in patients with acute myocardial infarction treated with primary percutaneous intervention. *J Am Soc Echocardiogr.* 2012;25(6):644–51
 6. Heimdal A, Stoylen A, Torp H, Skjaerpe T. Real time strain rate imaging of the left ventricle by ultrasound. *J Am Soc Echocardiogr.* 1998; 11:1013–19

How to cite this article: Sandipta Ray, Subir Sen, Sebabrata Jana. Evaluation of global and regional strain and angiographic correlation in patients with non-ST elevation acute coronary syndrome (NSTE-ACS). *Int J Health Sci Res.* 2024; 14(6):65-71. DOI: <https://doi.org/10.52403/ijhsr.20240610>
